

60th Anniversary Editorial

The journal *Acta Medica (Hradec Králové)* is entering its 60th year in a new format. The anniversary brings an opportunity to recall the path the Journal has gone through, and to consider possible future trends.

The first issue was published in 1958 under the title of *Sborník vědeckých prací lékařské fakulty Univerzity Karlovy v Hradci Králové (A Collection of Scientific Works of the Charles University Faculty of Medicine in Hradec Králové)*. The new journal then started to cover the publication needs of the new medical school established shortly after the World War in October II 1945 and affiliated to the renowned Charles University in Prague. Since then, the journal has remained interdisciplinary and has been bringing important findings of the research teams from various departments of our Faculty. There has always been a close association to the University Hospital in Hradec Králové, the most important hospital in East Bohemia and one of the best in the Czech Republic. As the years passed, increasing numbers of papers by extramural authors were published, including those from the other biomedical schools in Hradec Králové (Faculty of Military Medicine and Faculty of Pharmacy) as well as those from other medical schools and hospitals in Czechoslovakia, and now in the Czech Republic. In addition, there are a growing number of manuscripts submitted by authors from all around the world. In 2016, 57 manuscripts by foreign authors were submitted (i.e. 79% of all submissions), of which 13 (i.e. 23%) were accepted for publication after two peer-reviews.

The increasing participation of foreign authors (and readers), together with increasing confidence of Czech authors, has been paralleled by the changes in the publishing language. The first issues were published in Czech, with English and Russian summaries. Gradually, there were increasing number of articles in English, German, Russian, and occasionally French. Since 1974, all articles have been published in English. In 1996, the journal was renamed *Acta Medica (Hradec Králové)*.

In 2007, *Acta Medica* incorporated an older journal *Lékařské Zprávy (Medical Reports)*, published in Czech by our Faculty since 1956.

Since 1958, there has also been a considerable development in the informational technologies. While in the early years typewritten manuscripts were sent by post to the editorial office, the suitable ones were sent (also by post) to the reviewers, who made their corrections by pen and sent typewritten comments back to the editors, etc. and ultimately the revised manuscript, again typewritten, returned to the editors, and then to printing office for publication. The introduction of the Internet changed all that. Namely, the communication is more rapid and the corrections easier, leaving the availability of the reviewers and their time the most important factor of the manuscript processing time. Since 1997, the journal has been published both in printed and online version. Since 2015, all articles (online also those from the previous years) have received the unique and persistent identifier Crossref DOI, allowing for persistent link and precise citation analysis of our articles.

We have also adopted the open access approach, with no financial obligations either for the authors or the readers (platinum open access). The journal was included into the Directory of Open Access Journals (DOAJ) in 2004, and this was confirmed in 2016. Our articles are published online after being accepted (ahead of print), and shortly the abstract appears in PubMed, with a direct link to our website, where the full text is available for free. This brings our articles more publicity, resulting in increasing citation (though naturally even more affected by the quality of the article). The citations are being registered in Scopus, SCImago, Google Scholar and ResearchGate.

Today, *Acta Medica (Hradec Králové)* is an interdisciplinary medical journal, published quarterly and indexed in Index medicus, MEDLINE, Scopus, EBSCO, DOAJ and Chemical Abstracts.

We are happy that in its 60th year the journal is still going strong. We would like to thank all those participating in its successful course. We greatly appreciate the effort of all the previous Editors-in-Chief, Prof. MUDr. Jan Řehoř, DrSc. (1958–1965), Prof. MUDr. Jindřich Groh, CSc. (1966–1990), Prof. MUDr. Stanislav Němeček, DrSc. (1991–2006) and Prof. MUDr. Bohuslav Melichar, CSc. (2006–2008). With the exception of Prof. Němeček, who was widely educated histopathologist, they were all internists, with excellent general clinical knowledge and experience. I would like to give my special thanks to another generally educated internist, Prof. MUDr. Bohuslav Král, CSc., who was a long-term Edi-

tor-in-Chief of the incorporated journal *Lékařské Zprávy* and then became the most effective member of the *Acta Medica* Editorial Board. He was my invaluable teacher both in clinical internal medicine and in editorial work, and he is still (at the age of 87) greatly helpful to the journal. Also many other members of the Editorial Board have provided important help. However, as the quality of any journal is mostly dependent on the quality of the submitted manuscripts and on the peer-reviewing process, we are very grateful to our authors and reviewers. Especially for the reviewers, the cooperation means unselfish service to the scientific community, and we greatly appreciate their contribution. Both in better and worse times, the success of the journal would not be possible without unceasing support of our Faculty of Medicine, in the last 8 years led by Prof. MUDr. RNDr. Miroslav Červinka, CSc., as the Dean (picture on the cover). Last but not least, we have been enjoying a fruitful and strong liaison with Charles University Publishing House (Karolinum Press), led by Mgr. Petr Valo.

For future trends, an informal advisory group of experienced researchers led by the Vice-Dean of our Faculty Prof. MUDr. Sylvie Dusilová Sulková, DrSc., has been recruited. The new format of our journal is the first achievement. Other improvements are being discussed, and we will inform you on our plans in one of the following issues.

We will do our best to ensure that our Journal will continue to provide an efficient medium for scientific reports from members of our Faculty as well as from various Czech and foreign authors. We offer a friendly (though demanding) approach of our Editorial Board and the peer-reviewers.

Prof. MUDr. Jiří Horáček, CSc.
Editor-in-Chief

REVIEWER, THANK YOU

The Journal *Acta Medica (Hradec Králové)* would like to thank the following individuals who reviewed our manuscripts over the past year 2016. The voluntary peer-review process is at the heart of any professional medical journal. We greatly value the time and effort you took in reviewing the articles for our journal and we very much look forward to any possible cooperation with you in the future.

Seppo Ahlfors, *Boston, Massachusetts, USA*
Jiří Bajgar, *Hradec Králové, Czech Republic*
Stavros J. Baloyannis, *Thessaloniki, Greece*
Radim Brdička, *Prague, Czech Republic*
Radan Brůha, *Prague, Czech Republic*
Milan Buc, *Bratislava, Slovak Republic*
Vladimír Buchta, *Hradec Králové, Czech Republic*
Oliver Bulik, *Brno, Czech Republic*
Lucie Cahlíková, *Hradec Králové, Czech Republic*
Libor Červínek, *Brno, Czech Republic*
Tomáš Česák, *Hradec Králové, Czech Republic*
Viktor Chrobok, *Hradec Králové, Czech Republic*
Robert Čihák, *Prague, Czech Republic*
Leodante da Costa, *Toronto, Canada*
Klára Dadová, *Prague, Czech Republic*
Petr Dítě, *Ostrava, Czech Republic*
Ivo Dřížhal, *Hradec Králové, Czech Republic*
Ludwig Feinendegen, *Düsseldorf, Germany*
Steven Fishman, *Boston, Massachusetts, USA*
Maxim Freydin, *London, United Kingdom*
Mahmoud Ghazi-Khansari, *Tehran, Iran*
Igor Guňka, *Hradec Králové, Czech Republic*
Abdulbaset Hafuda, *Pardubice, Czech Republic*
Petr Hůlek, *Hradec Králové, Czech Republic*
Lydie Izakovičová Hollá, *Brno, Czech Republic*
Jan Jiskra, *Prague, Czech Republic*
Anna Jonášová, *Prague, Czech Republic*
Lubomír Jurgoš, *Bratislava, Slovak Republic*
Vojtěch Kamarád, *Olomouc, Czech Republic*
Jiří Kassa, *Hradec Králové, Czech Republic*
Pavel Klein, *Pilsen, Czech Republic*
Radim Kočvara, *Prague, Czech Republic*
Karel Kotaška, *Prague, Czech Republic*
Jaroslav Koudelka, *Hradec Králové, Czech Republic*
Antonín Krajina, *Hradec Králové, Czech Republic*
Jan Krejsek, *Hradec Králové, Czech Republic*
Kamil Kuča, *Hradec Králové, Czech Republic*
Tomáš Kučera, *Prague, Czech Republic*
Jaroslav Květina, *Hradec Králové, Czech Republic*

Carlos Martin Llorente, *Madrid, Spain*
Alena Meleková, *Pardubice, Czech Republic*
Jiří Náhlavský, *Hradec Králové, Czech Republic*
David Netuka, *Prague, Czech Republic*
Ivo Novák, *Hradec Králové, Czech Republic*
Aleš Novotný, *Prague, Czech Republic*
Jose Boix Ochoa, *Barcelona, Spain*
Jaroslav Pacovský, *Hradec Králové, Czech Republic*
Vladimír Palička, *Hradec Králové, Czech Republic*
Tomáš Pantoflíček, *Prague, Czech Republic*
Petr Pařízek, *Hradec Králové, Czech Republic*
Zbyšek Pavelek, *Hradec Králové, Czech Republic*
Arnošt Pellant, *Pardubice, Czech Republic*
Giovanni Mario Pes, *Sassari, Italy*
Rudolf Poruban, *Prague, Czech Republic*
Jindřich Preis, *Hradec Králové, Czech Republic*
Maurizio Quadri, *Asti, Italy*
Enrico Radaelli, *Leuven, Belgium*
Ondřej Renc, *Hradec Králové, Czech Republic*
Pavel Rozsival, *Hradec Králové, Czech Republic*
Pavel Šebesta, *Chemnitz, Germany*
Julius Šimko, *Hradec Králové, Czech Republic*
Richard Škába, *Prague, Czech Republic*
Dáša Slížová, *Hradec Králové, Czech Republic*
Ivo Stárek, *Olomouc, Czech Republic*
Ilja Stříž, *Prague, Czech Republic*
Vijayalakshmi Subramaniam, *Mangalore, India*
Miguel A. Teus, *Madrid, Spain*
Zbyněk Tonar, *Plzeň, Czech Republic*
Ondřej Urban, *Ostrava, Czech Republic*
Bijay Vaidya, *Exeter, United Kingdom*
Martin Vališ, *Hradec Králové, Czech Republic*
Jan Vodička, *Pardubice, Czech Republic*
Jan Vokurka, *Hradec Králové, Czech Republic*
Oldřich Vyšata, *Hradec Králové, Czech Republic*
Robert Weinkove, *Wellington, New Zealand*
Ralf Weiskirchen, *Aachen, Germany*
Pavel Zerhau, *Brno, Czech Republic*
Helena Živná, *Hradec Králové, Czech Republic*

Anthelmintic Flubendazole and Its Potential Use in Anticancer Therapy

Kristýna Čáňová¹, Lucie Rozkydalová², Emil Rudolf^{1,*}

ABSTRACT

Flubendazole is a widely used anthelmintic drug belonging to benzimidazole group. The molecular mechanism of action of flubendazole is based on its specific binding to tubulin, which results in disruption of microtubule structure and function, and in the interference with the microtubule-mediated transport of secretory vesicles in absorptive tissues of helminths. The microtubule-disrupting properties of benzimidazole derivatives raised recently interest in these compounds as possible anti-cancer agents. In this minireview flubendazole effects towards selected human malignant cells including myeloma, leukemia, neuroblastoma, breast cancer, colorectal cancer and melanoma are discussed along with basic data on its pharmacokinetics, metabolism and toxicity.

KEYWORDS

flubendazole; benzimidazole carbamate; anti-cancer treatment; melanoma; microtubules; mitotic catastrophe

AUTHOR AFFILIATIONS

¹ Department of Medical Biology and Genetics, Charles University, Faculty of Medicine in Hradec Králové, Czech Republic

² Department of Pharmacology, Charles University, Faculty of Pharmacy in Hradec Králové, Czech Republic

* Corresponding author: Charles University, Faculty of Medicine in Hradec Králové, Šimkova 870, 500 38 Hradec Králové, Czech Republic; e-mail: rudolf@lfhk.cuni.cz

Received: 18 January 2017

Accepted: 16 March 2017

Published online: 12 April 2017

Acta Medica (Hradec Králové) 2017; 60(1): 5–11

<https://doi.org/10.14712/18059694.2017.44>

© 2017 The Authors. This is an open-access article distributed under the terms of the Creative Commons Attribution License (<http://creativecommons.org/licenses/by/4.0>), which permits unrestricted use, distribution, and reproduction in any medium, provided the original author and source are credited.

INTRODUCTION

Cancer continues to be one of the leading causes of morbidity and mortality worldwide. Although there are numerous researches about anticancer therapy, with many lead candidates at various stages of preclinical or clinical research, only 5% of compounds originally entering Phase I clinical trials are in the end approved (1).

Historically, discovery of novel antineoplastic agents was essentially linked with pharmacological and biochemical analyses of diverse natural sources including microorganisms, animals and plants, often followed by total chemical synthesis or modification of identified individual compounds. This approach has been lately complemented by screening assays of libraries of all known and identified compounds with aim of selection of potentially suitable candidates for further testing. Although these mentioned strategies are still used, they suffer from several potential drawbacks including time cost, financial burden and laboriousness. New strategies are therefore needed to optimize the development of new, potent antineoplastic compounds. One of the promising strategies is drug repositioning (or repurposing). Drug repositioning is the process of searching for new indications of existing drugs (2). This is potentially efficient approach since many existing drugs are of established formulations produced by standardized manufacturing methods and their pharmacokinetic, pharmacodynamic and toxicity aspects are well known, thus reducing the chance of their future failure due to adverse side effects. Moreover, reduced cost of development as well as the shortened overall time required for approval can also be considered an advantage (1, 3, 4). These all factors contributed to the fact that to the date, there are at least 46 approved drugs already repositioned for new therapeutic uses as indicated in literature (5).

One of the potential pharmacological candidate for repurposing is flubendazole. Flubendazole ([5-(4-fluorobenzoyl)-1H-benzimidazole-2-yl]-carbamic acid methyl ester) belongs to the class of synthetic anthelmintic compounds (Fig. 1) which was found by Janssen company in 1970s.

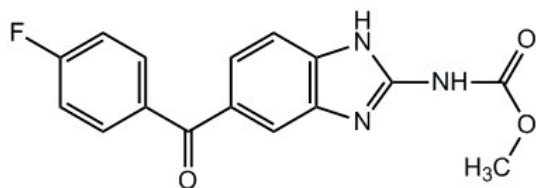


Fig. 1: Structure of flubendazole.

This compound belongs to the group of benzimidazole carbamates – drugs widely used in human and veterinary medicine against parasitic worms. The members of this group including flubendazole show wide range of efficiency towards gastrointestinal nematode infections in swine, poultry and domestic animals, as well as against lungworms in swine. In these indications, flubendazole is usually administered over 3 days at doses of approximately 5 mg/kg, but it is probably also efficient when given as a single dose at this same rate. In Europe, flubendazole is registered also for human use under the commercial name Fluvermal® for treatment of intestinal nematodes (4).

MECHANISM OF ACTION

The mechanism of action of benzimidazole carbamates encompasses their ability to specifically bind and interact with the microtubule subunit protein of β -tubulin (6). Microtubules, filamentous intracellular structures, are among main components of the eukaryotic cytoskeleton. They are composed of a single type of globular protein, called tubulin. Tubulin is a heterodimer consisting of two closely related polypeptides, α -tubulin and β -tubulin. Accordingly, it has been found that benzimidazole carbamates generally interact with mammalian tubulin even if the affinity for a mammalian tubulin is weaker compared with the one of helminths (7). Since microtubule structures are very important for many vital functions of the parasite such as proliferation, mitosis, intracellular transport of organelles, maintenance of cell shape or cell locomotion, alteration of microtubular assembly and dynamics leads to the final destruction of the parasite (6, 8, 9). In addition, benzimidazole carbamates may also inhibit energy metabolism of parasite cells. They cause disruption of transport and metabolism of glucose, resulting in energy and glycogen store depletion and loss of cellular motility. Even this process ultimately contributes to the death of the parasite (10, 11).

PHARMACOKINETICS

Benzimidazole carbamates including flubendazole are usually administered orally and absorbed through the gastrointestinal tract. Only small quantities of flubendazole are resorbed after oral treatment of pigs, rats, sheep, dogs and humans (12). Flubendazole is very poorly soluble in aqueous systems, which are found in the gastrointestinal tract, causing its low absorption to the bloodstream and thus very low bioavailability. Maximal plasma concentration levels of flubendazole in humans were lower than 5 ng/ml even after an oral dose of 2 g. Its absorption is markedly increased if the substance is used immediately after a meal (13). More than 80% of an oral dose is excreted in feces and only very small amounts of unchanged drug (less than 0.1%) are found in the urine. The half-life of flubendazole in tissues is 1–2 days (14, 15).

Low bioavailability is the main limitation for use of flubendazole for treatment of many tumors thus its potential future use in oncology must be associated with modifications enhancing its availability. It was established that the dosage of the benzimidazole drug doesn't have an influence on the area under the concentration curves (AUC). For example dogs treated with fenbendazole with a single dose with a different range of 25 to 100 mg/kg had similar AUC level (16). Another study has found that the maximum concentration (C_{max}) of flubendazole observed after its administration is significantly higher when solution is used instead of suspension. Moreover it was demonstrated that hydroxypropyl- β -cyclodextrin significantly increases aqueous solubility of flubendazole, which resulted in the higher plasma C_{max} and enhanced its absorption and bioavailability in treated mice (17). Hydroxypropyl- β -cyclodextrin is commonly-used reagent for enhancing bioavail-

ability of lipophilic drugs and can be used in both liquid and solid dosage forms (4).

METABOLISM OF FLUBENDAZOLE

There are two possible ways of flubendazole biotransformation. Absorbed flubendazole is during first-pass metabolism transformed in the liver, where hydrolysis of carbamate or reduction of ketone could take place. Ketoreduction to methyl [5-[(4-fluorophenyl)hydroxymethyl]-1H-benzimidazol-2-yl]carbamate was the major metabolic pathway verified in chickens and turkeys. Second metabolic pathway is carbamate hydrolysis to (2-amino-1H-benzimidazole-5-yl)(4-fluorophenyl)methanone, which is the major metabolic pathway in pigs. Products of both mentioned pathways are later converted to 2-amino- α -(4-fluorophenyl)-1H-benzimidazole-5-methanol. Metabolic pathways of flubendazole are shown in scheme (Fig. 2, 18).

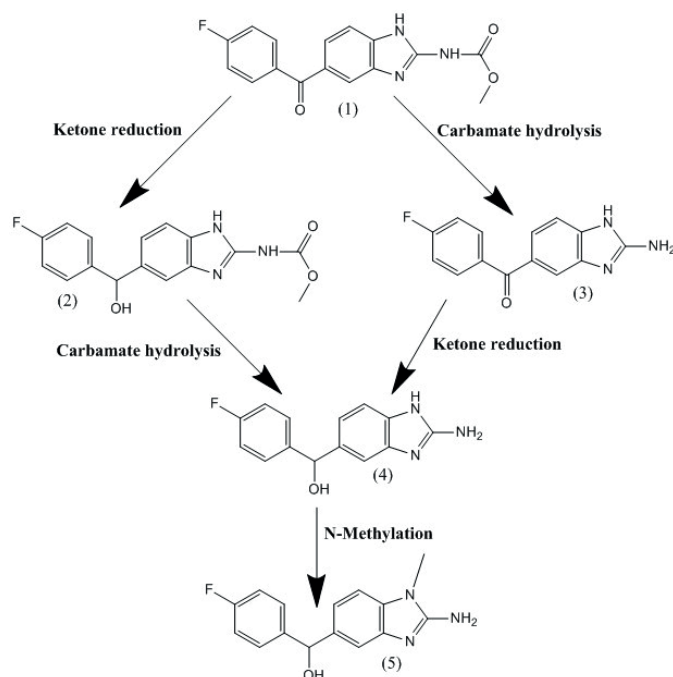


Fig. 2: Metabolic pathways of flubendazole (established by Van Leemput L. et al., 1991).

- (1) - flubendazole
- (2) - methyl-[5-[(4-fluorophenyl)hydroxymethyl]-1H-benzimidazol-2-yl]carbamate
- (3) - (2-amino-1H-benzimidazol-5-yl)(4-fluorophenyl)methanone
- (4) - 2-amino- α -(4-fluorophenyl)-1H-benzimidazole-5-methanol
- (5) - 2-amino- α -(4-fluorophenyl)-1-methyl-1H-benzimidazole-5-methanol

TOXICITY

The median lethal dose of flubendazole was explored in mice, rats and guinea pigs and was determined to have the value exceeding 2.56 g/kg (12). In selected animal species flubendazole-dependent teratogenic effects as well as its influence on fertility were tested. In all these species, flubendazole was well tolerated. In pigs, flubendazole

showed no teratogenicity and didn't have any effect on their fertility. Similarly, it did not affect reproductive ability or egg quality in hens and did not significantly diminish fertility in pheasants. Moreover, lack of any negative flubendazole-specific effect on reproductive performance was noted in the study with dogs. Finally, in rats flubendazole failed to produce any embryotoxic, foetotoxic, or teratogenic effects.

In several *in vitro* assays on gene mutation in bacteria and yeast cells as well as in *in vitro* assays on DNA damage in *Drosophila melanogaster* flubendazole tested negative. A carcinogenicity study in Wistar rats reported no evidence of transformation potential of this compound (14). Furthermore, toxicity studies in humans showed that treatment with flubendazole of neurocysticercosis with doses 40 to 50 mg/kg/d for 10 days and treatment of alveolar echinococcosis with doses 50 mg/kg/d for 24 months produced no toxicity and adverse effects (19, 20).

ANTICANCER ACTIVITY OF BENZIMIDAZOLE CARBAMATES IN PRECLINICAL MODELS

A number of reports demonstrated ability of benzimidazole carbamates to inhibit polymerization of mammalian tubulin *in vitro*. These results raised the question of whether this class of compounds could inhibit tubulin polymerization in human cells too and if so whether such a targeted effect could lead in a wider context to their antiproliferative and/or antitumor effects. First study to address this issue was published in 1985. It investigated a number of 5(6)-substituted methyl benzimidazole carbamate analogues and their activity against mouse leukemia cells L1210. In 1989, Robin et al. subsequently proved that benzimidazole carbamate albendazole is cytotoxic in hepatocellular carcinoma cell line Hep2G. Despite this early promising evidence, more thorough inquiry into antiproliferative potential of benzimidazole carbamates was realized almost after a decade only. In a panel of human, rat and mouse tumor liver cell lines albendazole at concentrations of 100 nM and higher was found to inhibit proliferation of all tested cells which correlated with concentration-dependent changes in cell cycle distribution. Upon lower employed albendazole concentrations (up to 500 nM), exposed cells accumulated in G1 phase while higher albendazole concentrations (around 1000 nM) mediated in the same cells transition delay through G2/M or mitosis. These *in vitro* observations were then by the same authors recapitulated *in vivo* using a xenograph model in which the growth of subcutaneous tumors induced by implantation of human tumor SKHEP-1 cells into nude mice was inhibited by the application of albendazole although at higher dose of 300 mg/kg/day only. Such a significant difference in effective albendazole concentrations in both models was attributed to the very high rate of metabolism of albendazole in mice and the poor blood supply to the studied tumor. Despite these observations, however, authors concluded that albendazole has a promising antitumor potential to be further investigated for the potential human use (21).

The anti-tumor efficiency of albendazole was also studied in a model of colorectal cancer. Albendazole and its

main metabolite albendazole sulfoxide were found to potently inhibit growth and proliferation of human colorectal cell line HT-29, with the IC₅₀ values of 0.12 μ M for albendazole and 2.35 μ M for albendazole-sulfoxide, respectively. Cytotoxicity of the same compound was also investigated in other colorectal cancer cell lines representing various stages of this malignancy (SW480, SW620, NCM460, Caco2 and HCT-8) where the most sensitive proved to be HCT-8 cells (IC₅₀ 0.4 μ M). Generally speaking, the main mechanism behind the observed effects of the employed compounds was induced arrest of cells at G2/M phase of the cell cycle and presence of caspase-3-mediated apoptosis (22). Furthermore, in nude mice HT-29 xenografts, regionally administered albendazole (150 mg/kg/i.p.) proved its efficacy in peritoneal carcinomatosis (23).

In paclitaxel-resistant leukemic cells CEM/dEpoB300 treatment with albendazole induced significant cytotoxicity (IC values being as low as 0.32 μ M in CEM and 0.16 μ M in CEM/dEpoB300). Albendazole in this case stimulated massive depolymerization of microtubular network and activation of morphologically distinct apoptosis occurring via downregulated expression of BCL-2 and MCL-1 proteins, mitochondrial release of cytochrome c and increased abundance of proapoptotic BAX as well as caspase-3 (24). Depolymerization of microtubules as a result of albendazole presence in the cell and resulting cell death was also confirmed in ovarian cancer cells sensitive (1A9) and resistant to paclitaxel (1A9PTX22) (25).

Another benzimidazole carbamate mebendazole was found effective in a number of *in vitro* models including adrenocortical carcinoma cell lines (26), non-small lung cancer cells (27), cholangiocarcinoma cancer cells (*in vivo* activity was noted too) (28), malignant melanoma cells (29), colon cancer cells (30, 31) and gastric cancer cells, where it could not only inhibit their growth but also migration and invasion (32).

ANTICANCER ACTIVITY OF FLUBENDAZOLE IN PRECLINICAL MODELS

Anti-tumor activity of flubendazole was first reported in leukaemia and myeloma cells originating from both established stabilized cell lines as well as from patients samples. At low and pharmacologically feasible nM concentrations, flubendazole induced mitotic catastrophe and cell death in malignant cells and delayed tumour growth *in vivo*. Mechanistically, flubendazole altered microtubule structure and inhibited tubulin polymerization by interacting with a site on tubulin similar to colchicine but distinct from that of Vinca alkaloids. A similar interaction with tubulin was also noted for mebendazole. However, other benzimidazole carbamate benomyl has been found to inhibit tubulin polymerization by interacting at a site distinct from both the colchicine and the Vinca domains. Thus, the actual mechanism of benzimidazoles-mediated inhibition of tubulin formation in exposed cells apparently varies within family members and may provide rationale for their putative usefulness in cases of recognized particular microtubule alterations in malignant cells.

Even more importantly, in cells resistant to vinblastine because of overexpression of P-glycoprotein full sensitivity to flubendazole was retained. In addition, flubendazole when supplied with both vinblastine and vincristine *in vitro* could reduce the viability of OCI-AML2 cells and delay tumor growth in a leukemia xenograft model more than either drug alone (33).

In a screen of a panel of 321 cell lines including cell lines from 26 cancer entities was neuroblastoma identified as another highly flubendazole-sensitive malignancy type. In the more refined screen aimed now on neuroblastoma model only, flubendazole displayed broad activity towards primary neuroblastoma cells obtained from five patients and a panel of 140 neuroblastoma cell lines with acquired drug resistance against major microtubule-binding compounds, with confirmed independence on major ABC transporters ABCB1 and ABCG2 expressions. The anti-neuroblastoma activity of flubendazole involved p53-signaling where the MDM2 inhibitor and p53 activator nutlin-3 strongly potentiated the observed flubendazole effects. Further inquiry into mechanisms of flubendazole-induced apoptosis suggested PUMA to be a key mediator of the induced effects. In addition, a water-soluble flubendazole-(2-hydroxypropyl)- β -cyclodextrin preparation inhibited vessel formation and tumor growth in the chick chorioallantoic membrane model *in vivo*, thus attesting to the potential treatment potential of flubendazole in neuroblastoma and feasibility of its further testing (34).

In another recently published study, flubendazole inhibited proliferation of several breast cancer cell lines (MDA-MB-231, BT-549, SK-BR-3 and MCF-7) in dose- and time-dependent manner and was shown to delay tumor growth in xenograft models by intraperitoneal injection. Flubendazole specifically reduced CD44^{high}/CD24^{low} subpopulation of treated cells and suppressed the formation of mammosphere and the expression of several, stem cell phenotype-related genes comprising *c-myc*, *oct-4*, *sox-2*, *nanog* and *cyclin D1*. Moreover, authors noted that flubendazole induced cell differentiation and inhibited cell migration. Among flubendazole-specific effects in breast cancer cells were also reduced expression of mesenchymal markers (i.e. β -CATENIN, N-CADHERIN and VIMENTIN) and an induced epithelial and differentiation marker (KERATIN 18). Observed antiproliferative effects of flubendazole were further associated with arrested cell cycle at G2/M phase and induced monopolar spindle formation through inhibited tubulin polymerization. In combined regimens, flubendazole enhanced cytotoxicity of standard therapeutic drugs fluorouracil and doxorubicin against breast cancer cells (35).

Besides exerting antiproliferative effects in breast cancer cells via inhibition of tubulin polymerization and cell cycle arrest, flubendazole proved to be a potent inducer of reactive oxygen species (ROSs) and could activate autophagy as demonstrated by Zhanq et al. Their *in-silico* analysis and experimental validation provide evidence on flubendazole as a compound capable of targeting the autophagy-related protein 4B(ATG4B) in MDA-MB-231 cell line with a promising potential for further testing of its usefulness in case of triple negative breast cancer therapy (36).

Flubendazole-based antiproliferative activity was also investigated on the small panel of colorectal cancer cell lines. Predictably, flubendazole inhibited the growth of these cells by the cell cycle arrest in the G2/M phase and also potentiated the effect of paclitaxel in this cellular model (22). In colorectal cancer SW480 and SW620 cells, low concentrations of flubendazole were cytotoxic as demonstrated by the presence of disrupted microtubular network, aberrant mitotic spindles and cell cycle perturbations accompanied by changes in CYCLIN D and B1 levels. Resulting activation of CASPASE-2 and CASPASE 3/7 as well as PARP cleavage lead to mitotic catastrophe and appearance of premature senescence phenotypes with typical giant multinucleated cells positive for SA- β -galactosidase staining. Although significant in their extent, these flubendazole-related effects were only temporary in their appearance and exposed cells were able to recover from them. This observation raised several important questions (such as the issue of longer term response rates of cancer cells to this compound as well as the nature of mechanisms enabling the rescue of cells undergoing mitotic catastrophe and/or premature senescence etc.) prompting the need of further studies in this field (37).

In our laboratory, we are investigating effects of flubendazole on malignant melanoma. Melanoma is the most aggressive form of skin cancer, with a high propensity to metastasize (38). Most metastatic melanoma patients fail to respond to available therapy, underscoring the need for innovative processes to identify more effective treatment. In line with the repositioning strategy, biological effects of selected benzimidazole carbamates were already investigated in melanoma models. Doudican et al. focused on potential mebendazole activity in chemoresistant M-14 and SK-Mel-19 cell lines. He proved that this compound effectively inhibited the growth and proliferation of malignant melanocytes (IC₅₀ was 0.32 μ M) while having a minimal effect on the normal melanocytes. Mebendazole effects were mediated via induced phosphorylation of BCL-2 which contributed to the proapoptotic signaling and resulting cell death. In the light of fact that BCL-2 is widely expressed in human melanoma with a recognized role in melanoma chemoresistance, this discovered mebendazole's activity is of particular interest and deserves further examination (29). Supporting this conclusion is also the fact that mebendazole treatment decreases expression levels of another key antiapoptotic protein – X-linked inhibitor of apoptosis (XIAP) both *in vitro* and in human xenograft melanoma model. This inhibition may occur partially through proteasomal degradation of XIAP and/or via stimulated interaction of SMAC/DIABLO with XIAP (38).

Our results on antiproliferative activity of flubendazole obtained from model melanoma cell lines Bowes, A-375 and RPMI-7951 generally concur with the findings of Michaelis et al. although our determined IC₅₀ values were generally higher than those reported in their employed melanoma models. We also proved flubendazole-dependent stimulation of mitotic catastrophe with resulting caspase-dependent cell death in all exposed melanoma cells, however, unlike in case of mebendazole with var-

ying contribution of individual signaling pathways and negligible involvement of BCL-2 and XIAP proteins. These results clearly suggest that flubendazole may interfere with a variety of signaling pathways and/or targets which among other factors reflects genotypic and phenotypic differences in melanoma cell populations and warrants more detailed further studies.

ANTICANCER ACTIVITY OF BENZIMIDAZOLE CARBAMATES IN CLINICAL STUDIES

So far, no clinical study on flubendazole effects in human malignancies has been conducted. Still, there exists some clinical information on other members of benzimidazole carbamate family. A pilot study on albendazole in 7 patients with advanced hepatocellular cancer or colorectal cancer with hepatic metastases refractory to other forms of therapy was conducted over 28 days. In patients who received albendazole at 10 mg/kg/day orally in two divided doses tumor markers (carcinoembryonic antigen or alpha-feto protein) were measured and hematological as well as biochemical parameters were obtained to monitor potential bone marrow, kidney or liver toxicity. Results of this study confirmed a good tolerance of albendazole in all patients with only concern being severe neutropenia in three of them. Importantly, albendazole treatment resulted in decrease of followed tumor markers in two patients while in three others the markers were stabilized, thus demonstrating that albendazole shows antitumor activity in humans (39). In the subsequent dose-finding phase I study of oral albendazole in patients with refractory solid tumors thirty-six patients received doses of 400 mg with dose escalation until 1,200 mg twice a day in a 3 week cycle with serial blood sample collection up to 96 h and on day 8 of cycles 1 and 4. The results of this study confirmed that albendazole was well tolerated on the tested treatment schedule, with main dose-limiting toxicity being myelosuppression. Authors recommended the dose of 1,200 mg albendazole twice daily for 14 days in a 21-day cycle for further study (40).

Currently, two clinical trials of mebendazole in brain tumors are carried out. The first one is a phase I open label study in newly diagnosed high-grade glioma patients receiving temozolomide. Patients are treated on a 28 day cycle of 500 mg oral mebendazole three times a day. The primary aim is to determine the maximum tolerated dose of mebendazole with temozolomide and to determine whether this combined regimen can slow tumour progression. The study was completed in September 2016 with no results reported yet. The second clinical trial is phase I and II pilot study of mebendazole in combination with vincristine, carboplatin, and temozolomide. The mebendazole dose is 100 mg twice a day during 70 weeks of treatment. The primary objective of the phase I is verify tolerability of mebendazole dose with the current three-drug regimen. For the phase II aims include time of progression-free status in patients and their overall survival. The study is currently recruiting participants and estimated study completion date is April 2020 (41).

CONCLUSION

There is ample evidence that several benzimidazole carbamates and in particular flubendazole and even to a higher degree albendazole and mebendazole show anti-tumor potential *in vitro*, *in vivo*, and *in silico*. Despite the fact that all of them primarily target microtubular system, their concrete mechanisms of action are slightly different. One explanation of this variability might relate to their structural similarity with nucleotides which enables their interaction with a variety of biomolecules. Resulting is the diverse range of mechanisms of action such as reduction of fumarate or glucose uptake in addition to their interaction with cytoskeleton which en face with often chemoresistant and aggressive tumor cells could represent natural advantage. Another strong advantage concerning the potential use of flubendazole as well as other two more intensively studied benzimidazole carbamates is their demonstrated synergism with several clinically approved drugs. To this end published data from clinical trials albeit very limited and preliminary strongly argue in favor of these compounds with well-established pharmacokinetics, excellent toxicity profile and low-cost and warrant their individual further evaluation in oncology.

ACKNOWLEDGEMENTS

This work was supported by the projects PRVOUK P37/01 and SVV 2016 of Charles University, Faculty of Medicine in Hradec Králové.

REFERENCES

- Kato S, Moulder SL, Ueno NT, et al. Challenges and perspective of drug repurposing strategies in early phase clinical trials. *Oncoscience* 2015 Jun 30; 2(6): 576–80.
- Shim JS, Liu JO. Recent Advances in Drug Repositioning for the Discovery of New Anticancer Drugs. *International Journal of Biological Sciences* 2014; 10(7): 654–63.
- Hurle MR, Yang L, Xie Q, Rajpal DK, Sanseau P, Agarwal P. Computational Drug Repositioning: From Data to Therapeutics. *Clinical Pharmacology & Therapeutics* 2013 Apr 1; 93(4): 335–41.
- Mackenzie CD, Geary TG. Flubendazole: a candidate macrofilaricide for lymphatic filariasis and onchocerciasis field programs. *Expert Rev Anti Infect Ther* 2011 May; 9(5): 497–501.
- Li YY, Jones SJ. Drug repositioning for personalized medicine. *Genome Med.* 2012 Mar 30; 4(3): 27.
- Lacey E. Mode of action of benzimidazoles. *Parasitol Today (Regul Ed)* 1990 Apr; 6(4): 112–5.
- Ireland CM, Gull K, Gutteridge WE, Pogson CI. The interaction of benzimidazole carbamates with mammalian microtubule protein. *Biochem Pharmacol* 1979 Sep 1; 28(17): 2680–2.
- Cooper GM. Microtubules 2000; Available from: <http://www.ncbi.nlm.nih.gov/books/NBK9932/>
- Jordan MA, Wilson L. Microtubules as a target for anticancer drugs. *Nat Rev Cancer* 2004 Apr; 4(4): 253–65.
- Jasra N, Sanyal SN, Khera S. Effect of thiabendazole and fenbendazole on glucose uptake and carbohydrate metabolism in *Trichuris globulosa*. *Vet Parasitol* 1990 Mar; 35(3): 201–9.
- Cumino AC, Elissondo MC, Denegri GM. Flubendazole interferes with a wide spectrum of cell homeostatic mechanisms in *Echinococcus granulosus* protoscoleces. *Parasitology International* 2009 Sep; 58(3): 270–7.
- Bossche HV, Thienpont D, Janssens PG. Chemotherapy of Gastrointestinal Helminths. Springer Science & Business Media 2012. 732 p.
- Michiels M, Hendriks R, Heykants J, van den Bossche H. The pharmacokinetics of mebendazole and flubendazole in animals and man. *Arch Int Pharmacodyn Ther* 1982 Apr; 256(2): 180–91.
- European Medicines Agency (online) – Committee for products for veterinary use – flubendazol – Summary report (July 2006). Available at: http://www.ema.europa.eu/docs/en_GB/document_library/Maximum_Residue_Limits_-_Report/2009/11/WC500014292.pdf. (14 July 2016, date last accessed).
- Institute for state control of veterinary biologicals and medicines – Summary of Product Characteristics – Flubenol® (online). Available at: <http://www.uskvbl.cz>. (14 July 2016, date last accessed).
- McKellar QA, Galbraith EA, Baxter P. Oral absorption and bioavailability of fenbendazole in the dog and the effect of concurrent ingestion of food. *J Vet Pharmacol Ther* 1993 Jun; 16(2): 189–98.
- Ceballos L, Elissondo M, Bruni SS, Denegri G, Alvarez L, Lanusse C. Flubendazole in cystic echinococcosis therapy: pharmacoparasitological evaluation in mice. *Parasitol Int* 2009 Dec; 58(4): 354–8.
- Van Leemput L, Heykants J (1991). Flubendazole: concentrations in plasma and residues in edible tissues of pheasants after a 7-day treatment at 60 ppm in the feed. Unpublished report number R 17889/FK1071. Submitted to FAO by Janssen Pharmaceutica, Beerse, Belgium.
- Roche G, Canton P, Gérard A, Dureux JB. Treatment of alveolar echinococcosis with flubendazole. Pharmacological study (author's transl.). *Pathol Biol* 1982 Jun; 30(6): 452–7.
- Lassègue A, Estavoyer JM, Minazzi H, et al. Treatment of human alveolar echinococcosis with flubendazole. Clinical, morphological and immunological study. *Gastroenterol Clin Biol* 1984 Apr; 8(4): 314–20.
- Pourgholami MH, Woon L, Almajd R, Akhter J, Bowery P, Morris DL. In vitro and in vivo suppression of growth of hepatocellular carcinoma cells by albendazole. *Cancer Letters* 2001 Apr 10; 165(1): 43–9.
- Králová V, Hanušová V, Staňková P, Knoppová K, Čáňová K, Skálová L. Antiproliferative effect of benzimidazole anthelmintics albendazole, ricobendazole, and flubendazole in intestinal cancer cell lines. *Anticancer Drugs* 2013 Oct; 24(9): 911–9.
- Pourgholami MH, Akhter J, Wang L, Lu Y, Morris DL. Antitumor activity of albendazole against the human colorectal cancer cell line HT-29: in vitro and in a xenograft model of peritoneal carcinomatosis. *Cancer Chemother Pharmacol* 2004 Nov 23; 55(5): 425–32.
- Khalilzadeh A, Wangoo KT, Morris DL, Pourgholami MH. Etoposide-paclitaxel resistant leukemic cells CEM/dEpoB300 are sensitive to albendazole: Involvement of apoptotic pathways. *Biochemical Pharmacology* 2007 Aug 1; 74(3): 407–14.
- Chu SWL, Badar S, Morris DL, Pourgholami MH. Potent inhibition of tubulin polymerisation and proliferation of paclitaxel-resistant 1A9PTX22 human ovarian cancer cells by albendazole. *Anticancer Res* 2009 Oct; 29(10): 3791–6.
- Martarelli D, Pompei P, Baldi C, Mazzoni G. Mebendazole inhibits growth of human adrenocortical carcinoma cell lines implanted in nude mice. *Cancer Chemother Pharmacol* 2008 Apr; 61(5): 809–17.
- Sasaki J, Ramesh R, Chada S, Gomyo Y, Roth JA, Mukhopadhyay T. The anthelmintic drug mebendazole induces mitotic arrest and apoptosis by depolymerizing tubulin in non-small cell lung cancer cells. *Mol Cancer Ther* 2002 Nov; 1(13): 1201–9.
- Sawanyawisuth K, Williamson T, Wongkham S, Riggins GJ. Effect of the antiparasitic drug mebendazole on cholangiocarcinoma growth. *Southeast Asian J Trop Med Public Health* 2014 Nov; 45(6): 1264–70.
- Doudican N, Rodriguez A, Osman I, Orlov SJ. Mebendazole induces apoptosis via Bcl-2 inactivation in chemoresistant melanoma cells. *Mol Cancer Res* 2008 Aug; 6(8): 1308–15.
- Nygren P, Fryknäs M, Ågerup B, Larsson R. Repositioning of the anthelmintic drug mebendazole for the treatment of colon cancer. *Journal of Cancer Research and Clinical Oncology* 2013 Dec; 139(12): 2133–40.
- Nygren P, Larsson R. Drug repositioning from bench to bedside: tumour remission by the anthelmintic drug mebendazole in refractory metastatic colon cancer. *Acta Oncol* 2014 Mar; 53(3): 427–8.
- Pinto LC, Soares BM, Pinheiro J de JV, Riggins GJ, Assumpção PP, Burbano RMR, et al. The anthelmintic drug mebendazole inhibits growth, migration and invasion in gastric cancer cell model. *Toxicol In Vitro* 2015 Dec; 29(8): 2038–44.
- Spagnuolo PA, Hu J, Hurren R, et al. The anthelmintic flubendazole inhibits microtubule function through a mechanism distinct from Vinca alkaloids and displays preclinical activity in leukemia and myeloma. *Blood* 2010 Jun 10; 115(23): 4824–33.
- Michaelis M, Agha B, Rothweiler F, et al. Identification of flubendazole as potential anti-neuroblastoma compound in a large cell line screen. *Sci Rep* 2015; 5: 8202.
- Hou Z-J, Luo X, Zhang W, et al. Flubendazole, FDA-approved anthelmintic, targets breast cancer stem-like cells. *Oncotarget* 2015 Mar 20; 6(8): 6326–40.
- Zhang L, Guo M, Li J, et al. Systems biology-based discovery of a potential Atg4B agonist (Flubendazole) that induces autophagy in breast cancer. *Mol Biosyst* 2015 Nov; 11(11): 2860–6.
- Králová V, Hanušová V, Rudolf E, Čáňová K, Skálová L. Flubendazole

- induces mitotic catastrophe and senescence in colon cancer cells in vitro. *J Pharm Pharmacol* 2016 Feb; 68(2): 208-18.
38. Doudican NA, Byron SA, Pollock PM, Orlov SJ. XIAP downregulation accompanies mebendazole growth inhibition in melanoma xenografts. *Anticancer Drugs* 2013 Feb; 24(2): 181-8.
 39. Morris DL, Jourdan JL, Pourgholami MH. Pilot study of albendazole in patients with advanced malignancy. Effect on serum tumor markers/high incidence of neutropenia. *Oncology* 2001; 61(1): 42-6.
 40. Pourgholami MH, Szwajcer M, et al. Phase I clinical trial to determine maximum tolerated dose of oral albendazole in patients with advanced cancer. *Cancer Chemother Pharmacol* 2010 Feb; 65(3): 597-605.
 41. Pantziarka P, Bouche G, Meheus L, Sukhatme V, Sukhatme VP. Repurposing Drugs in Oncology (ReDO) - mebendazole as an anti-cancer agent. *Ecancermedalscience* 2014 Jul 10; 8.

The Osteogenic Potential of Human Non-differentiated and Pre-differentiated Mesenchymal Stem Cells Combined with an Osteoconductive Scaffold – Early Stage Healing



Luboš Tuček¹, Zuzana Kočí^{2,3,4}, Kristýna Kárová^{2,3}, Helena Doležalová¹, Jakub Suchánek^{1,*}

ABSTRACT

Despite the huge research into stem cells and their regenerative properties for bone healing, there are still unanswered questions including the recipient's respond to the presence of the stem cells, the fate of stem cells inside the bone defect and the possible advantage in utilizing pre-differentiated cells. To address these problems, we used human multipotent mesenchymal stromal/stem cells (MSCs), GMP Grade, in a rat model of bone formation. In a "bioreactor concept" approach seven Wistar rats were implanted with 0.2 g of synthetic bone scaffold seeded with 2×10^6 MSCs, seven Wistar rats were implanted with 0.2 g of synthetic bone scaffold seeded with 1×10^6 pre-differentiated osteoblasts and 1×10^6 pre-differentiated endothelial cells and 14 Wistar rats were implanted with 0.2 g of synthetic bone scaffold without seeded cells into an intramuscular pocket on the left side of their back. The right side of each rat was used as a control, and 0.2 g of synthetic bone scaffold was implanted into the intramuscular pocket alone. To see the early stage healing the samples were harvested 14 days after the implantation, MSCs were detected by positive DAPI and MTCO2 staining in 43% of all the samples implanted with MSCs, and no inflammation signs were present in any implanted animal. New vessels could be found in both groups implanted with MSCs, but not in the control group of animals. However, hematoxylin-eosin staining could not detect newly created bone within the implant in any of the groups. These results were in line with COL1 staining, where we could detect positive staining only in three cases, all of which were implanted with un-differentiated MSCs. According to our findings, there were no benefits of using the pre-differentiated of MSC.

KEYWORDS

mesenchymal stromal/stem cells; bone defect; osteoconduction; osteoinduction; scaffold; tissue bone engineering

AUTHOR AFFILIATIONS

¹ Department of Dentistry, Charles University, Medical Faculty and University Hospital Hradec Králové, Czech Republic

² Institute of Experimental Medicine ASCR, Prague, Czech Republic

³ Department of Neuroscience, 2nd Faculty of Medicine, Charles University, Czech Republic

⁴ Bioinova, Ltd, Prague, Czech Republic

* Corresponding author: University Hospital Hradec Králové, Department of Dentistry, Sokolská 581, 500 05 Hradec Králové, Czech Republic; e-mail: suchanekj@lfhk.cuni.cz

Received: 25 November 2016

Accepted: 20 December 2016

Published online: 6 March 2017



Acta Medica (Hradec Králové) 2017; 60(1): 12–18

<https://doi.org/10.14712/18059694.2017.43>

© 2017 The Authors. This is an open-access article distributed under the terms of the Creative Commons Attribution License (<http://creativecommons.org/licenses/by/4.0>), which permits unrestricted use, distribution, and reproduction in any medium, provided the original author and source are credited.

INTRODUCTION

MANAGEMENT OF THE BONE DEFECTS

Bone disorders connected with the aging population, low physical activity and higher body weight starts to represent challenging tasks for nowadays and mostly close future medicine. Most commonly found disorders are bone cysts, benign or malign tumors and pathological fracture. The first two mentioned represent diseases characterized by a silent slow progression and accompanied with wide bone destruction. The result of the surgery and its efficiency is mostly based on the size of the bone defect. The small defect can be left without any treatment and undergo physiological regeneration similar way to the healing of a bone fracture. This standard procedure works very well in case of small defects but larger defects are often accompanied by some complications, such as pathological fracture or dehiscence of the wound with secondary infection and subsequently blood clot disintegration. Most of these complications can be prevented by filling the bone defect with materials that can replace the bone immediately after surgery and enhance the healing speed by stimulating new bone creation. Studies focused on replacement of the damaged tissues using autologous and allogeneic transplantation revealed considerable limitations and complication (3, 5, 7, 13). However, autografts are considered as gold standard of the treatment they are connected with needs of harvesting the bone from other bone source and therefore leads to another surgery, pain, scaring and possible complication during healing. Allografts on the other hand are connected with some ethical issues, many patient are not accepting tissue from the cadaver. Obtaining such a tissue is expensive and represents the risk of immunoreactions and transmission of infection. Nowadays, stem cell therapy and tissue engineering are commonly considered as new potential methods for the treatment of different types of diseases. It seems to be logical to combine MSCs together with osteoinductive scaffolds to accelerate bone healing. However, vascularization is still an issue that must be addressed (2). Even though stem cells are generally more resistant to hypoxia and low nutrition supply than somatic cells, we must ensure that the growth of the blood vessels is complete before maturation occurs.

RESEARCH AIMS

While most of the published studies take at least one month, but mostly 3–6 months to prove the effect of the BTE, the presented study is focused on early stage healing and the changes within the tricalcium phosphate scaffold loaded with human MSC. Moreover we tried to identify the differences resulting from usage of non-differentiated and pre-differentiated MSC.

Our research aims are, successively:

I. Confirm the survival of the MSCs loaded into the scaffold under *in vivo* conditions and the changes in the surrounding area during early stage healing (2 weeks).

II. Histologically evaluate the angiogenesis and new bone creation during early stage healing

III. Evaluate the benefits resulting from usage of the pre-differentiated MSCs

DELIMITATION AND AREA OF THE STUDY

To reach the research aims we compare the scaffold loaded with pre-differentiated, non-differentiated MSCs and scaffold which was not loaded with the MSCs applying the approach suggested by Rosset et al. (10). A group of rats was implanted with a bone scaffold loaded with pre-differentiated osteoblasts and pre-differentiated endothelial cells, and this group was compared to a group of rats implanted with the bone scaffold loaded with undifferentiated MSCs and group of rat implanted with the scaffold alone. To observe the early stage healing and new vessels creation the samples were taken back after 2 weeks *in vivo* and histologically evaluated. Results were compared in terms of immune reaction, new vessel formation and new bone formation.

METHODS

CELL PREPARATION

MSCs isolation was performed in GMP facility of Bioinova, Ltd. (Prague, Czech Republic). Adherent cells were cultured at 37 °C in a humidified atmosphere containing 5% CO₂ in enriched MEM Alpha media (Lonza, Walkersville, Maryland, USA) containing platelet lysate (5%; Bioinova) and gentamycin (10 µg/ml; Gentamicine Lek[®]; Lek Pharmaceuticals, Ljublanja, Slovenia). The media was changed twice a week. According to their surface markers expression (Figure 1), spindle-shaped morphology and plastic adherence (Figure 2a) the cells were identified as MSCs. After reaching near-confluency, cells were harvested by a TrypLE™ (Life Technologies, Carlsbad, California, USA), passaged and seeded again onto a fresh plastic surface. Cells in the 2nd passage were allowed to differentiate into osteoblasts and endothelial cells according to standard differentiation protocols. Seven days after, pre-differentiated cells were harvested and seeded onto a synthetic bone

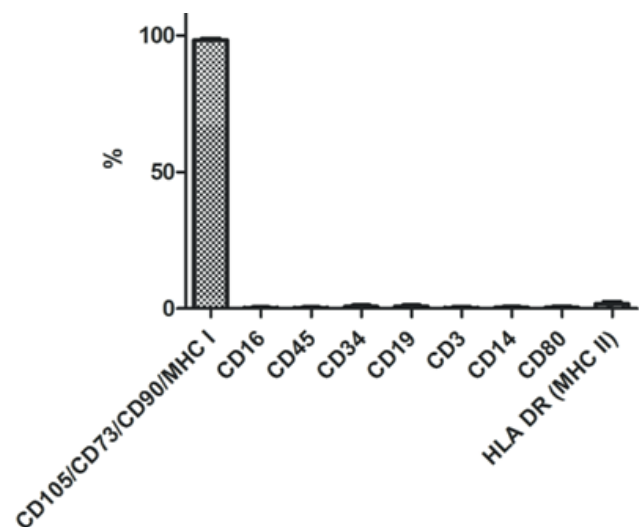


Fig. 1: Characterization of the MSCs in Suspension of autologous MSC 3P in 1.5 ml (Bioinova). Expression of MSCs surface markers was analyzed on fluorescence-activated cell sorting (FACS) using antigens against these surface markers: CD105, CD73, CD90, MHC I, CD16, CD45, CD34, CD19, CD3, CD14, CD80, HLA DR (MHC II).

scaffold. Undifferentiated cells in the 3rd passage were also harvested and seeded onto a synthetic bone scaffold.

OSTEOGENIC DIFFERENTIATION

MSCs were seeded onto a 75 cm² cultivation flask at a density of 3×10^3 cells/cm². The next day, cells were treated with a media consisting of MEM Alpha, 10% FBS, 1% P/STM, 0.1 μ M dexamethasone, 10 mM β -glycerolphosphate and 0.1 mM L-ascorbic acid (all from Sigma-Aldrich, St Louis, Missouri, USA). After 2 weeks in the culture, the cells were harvested and a control sample was fixed and stained with Alizarin Red S to detect calcium-rich deposits shown in Figure 2b.

ENDOTHELIAL DIFFERENTIATION

MSCs were seeded onto a 75 cm² cultivation flask coated at a density of 2×10^3 cells/cm². Cells were cultivated in media consisting of MEM Alpha, 10% FBS, 1% P/STM, 50 ng/ml vascular endothelial growth factor (VEGF; Sigma, St Louis, Missouri, USA) and 10 ng/ml basic fibroblast growth factor (bFGF, Sigma, St Louis, Missouri, USA). After 2 weeks, the cells were harvested and a control sample was counterstained with DAPI and von Willebrand's factor antibody (Sigma, St Louis, Missouri, USA) to detect endothelial-like cells shown in Figure 2c.

SYNTHETIC BONE SCAFFOLD

PORESORB[®]-TCP (Lasak Ltd, Prague, Czech Republic) was used as a synthetic bone scaffold. This material is based on tricalcium phosphate and its structure is similar to that of bone, possessing two main sizes of porosity: macro-pores, approximately 100–200 μ m in size, and micro pores, ranging from 1 to 5 μ m.

ANIMALS

Wistar rats (Velaz, Prague, Czech Republic) with body weights ranging from 550–600 g were used in this study. All experiments were done in compliance with the European Communities Council Directive of 24 November 1986 (86/609/EEC) regarding the use of animals in research and were approved by the Ethical Committee of the Institute of Experimental Medicine ASCR, Prague, Czech Republic. All efforts were made to minimize the number of animals used in the study. Rats were randomly divided into one of the following groups shown in Table 1: (i) rats implanted with 0.2 g of synthetic bone scaffold only (group 1; n = 14), (ii) rats implanted with 0.2 g of synthetic bone scaffold

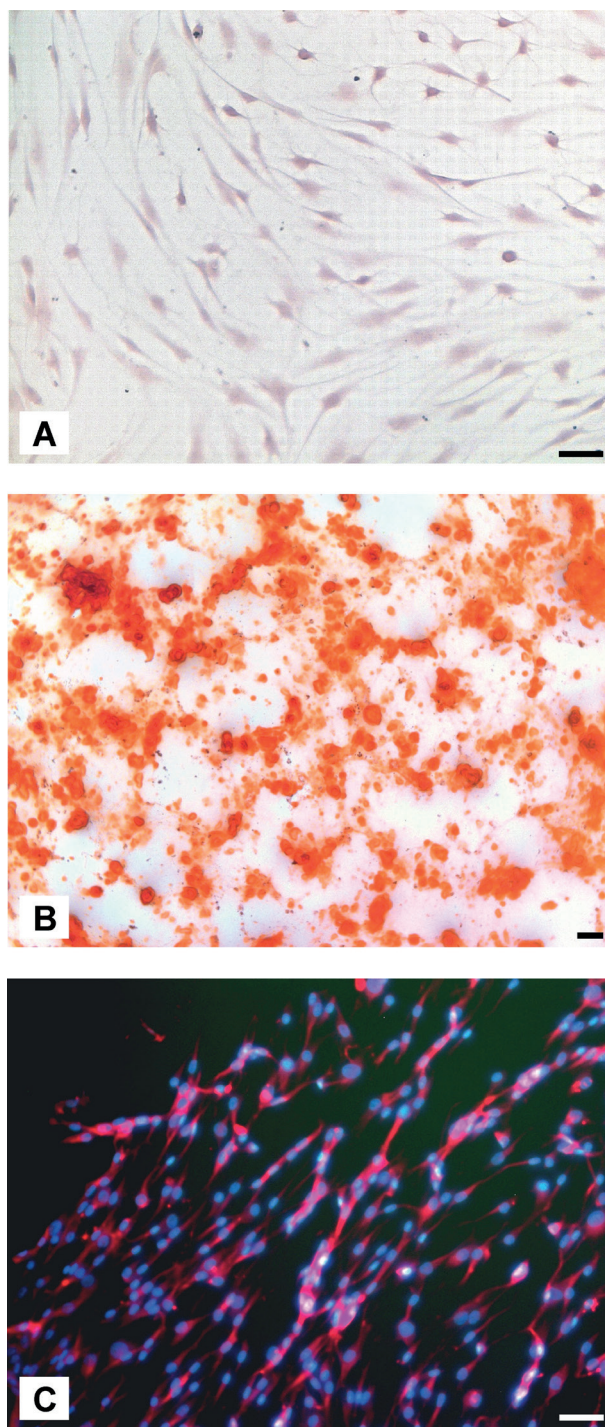


Fig. 2: Illustration of undifferentiated MSCs stained with hematoxylin-eosinofil (A, original magnification 100 \times); pre-differentiated osteoblasts stained with Alizarin Red S (B, original magnification 50 \times); pre-differentiated endothelial cells stained with DAPI and von Willebrand's factor antibody (C, original magnification 200 \times).

Group	Number of rats	Implanted material	Type and amount of MSCs
1	14	Poresorb [®] -TCP	-
2	7	Poresorb [®] -TCP	2×10^6 undifferentiated MSCs
3	7	Poresorb [®] -TCP	10^6 pre-differentiated osteoblasts + 10^6 pre-differentiated endothelial-like cells

Tab. 1: Characteristics of animal groups implanted with combined biomaterial based on tricalcium phosphate and mesenchymal stromal cells (MSCs).

seeded with 2×10^6 MSCs (group 2; $n = 7$), and (iii) rats implanted with 0.2 g of synthetic bone scaffold seeded with 1×10^6 pre-differentiated osteoblasts and 1×10^6 pre-differentiated endothelial cells (group 3; $n = 7$).

SURGERY

After the induction of anesthesia, using 5% isoflurane in room air (flow 300 mL/min), the animals were maintained in 2% isoflurane anesthesia (flow 300 mL/min) via a face mask throughout the operation. 0.1 ml of analgesic Rymadile (Pfizer Animal Health SA, Louvain-la-Neuve, Belgium) was injected intramuscularly. Under aseptic conditions, a 2 cm lateral skin incision was performed on the back of the animal. The osteogenic biomaterial was implanted into the intramuscular pocket. The soft tissue and skin was sutured with non-resorbable thread. Transplanted animals were immunosuppressed on a daily basis with 10 mg/kg cyclosporine (Sandimmun®, Novartis, Basel, Switzerland) administered intraperitoneally; this procedure started from the day before surgery and lasted until euthanasia. Bacterial infection was prevented by an intramuscular gentamycin injection (60 mg/kg; Gentamicine Lek®; Lek Pharmaceuticals, Ljubljana, Slovenia). The rats were euthanized 14 days after surgery.

HISTOLOGICAL ANALYSIS

At the end of the experiment, the animals were intracardially perfused under deep anesthesia (pentobarbital 150 mg/kg) with 4% formaldehyde in 0.1 M PBS (IKEM, Prague, Czech Republic). The tissue containing implants were dissected from the area, postfixed in 10% formaldehyde and further decalcified with formic acid (Fingerland's department of Pathology, Hradec Králové, Czech Republic). One paraffin block was prepared from each sample, cut into 4 μ m thin sections and stained with hematoxylin-eosin (H&E). Sections were examined under a light microscope and histomorphometrical analysis was performed using NIS-Elements software (Nikon Instruments, Inc., USA). Immunofluorescent staining for DAPI (Sigma, St Louis, Missouri, USA), RECA, COL1, MT-CO2 (all from Abcam, Princeton, New Jersey, USA) was used to identify the potential survival of transplanted cells. Antigen-antibody complexes were visualized using goat anti-mouse IgG secondary antibody conjugated with Alexa-Fluor 488 (Molecular Probes Invitrogen, Carlsbad, California, USA). The samples were examined using a spectral confocal microscope (Carl-Zeiss, Oberkochen, Germany). Results were calculated as a percentage of positive samples in the whole sample group.

RESULTS

All animals were successfully implanted with the osteoconductive biomaterial without rejection. Hematoxylin-eosin staining revealed deposits of calcified material surrounded by multinucleated foreign body giant cells in all three groups visualized in Figure 3a. Neither neutrophils, nor lymphocytes were present, implying that

there was no inflammation caused by implantation of the combined biomaterial or of the separate osteoconductive biomaterial, respectively (visualized in Figure 3b). However, no new bone or cartilage formation was detected by hematoxylin-eosin staining. In the vicinity of the implant, signs of skeletal muscle regeneration associated with surgery were evident according to small profiles of myotubes with centrally located nuclei.

Immunohistochemical analysis confirmed the biocompatibility of the human MSCs with the calcium triphosphate synthetic bone scaffold. MSCs were detected by positive DAPI and MTCO2 staining in 43% of all the samples implanted with MSCs, in 57% of samples with undifferentiated MSCs (group 2) and in 28% of samples with pre-differentiated MSCs (group 3) as shown in Table 2 and Figure 4a. MSC survival rate was not affected by differentiation. Positive RECA staining was found in 93% of all samples implanted with MSCs. No significant differences were found between group 3, which involved implantation with pre-differentiated MSCs (100% of samples stained positively), and group 2 with undifferentiated MSCs (86% of samples stained positively), as shown in Table 2 and in Figure 4b.

Results from the histological evaluation shown in Figure 4c were confirmed by COL1 staining. Positive COL1 staining was detected in only three samples, all of which were in group 2 and had been implanted with undifferentiated MSCs.

	MTCO2	RECA	COL1
Group 1	0/14	0/14	0/14
Group 2	4/7	6/7	3/7
Group 3	2/7	7/7	0/7

Tab. 2: Immunohistochemical analysis of tissue sections. Group 1 ($n = 14$) represents control animals implanted with PORE-SORB®-TCP; group 2 ($n = 7$) represents animals implanted with PORESORB®-TCP seeded with mesenchymal stromal cells (MSCs); group 3 ($n = 7$) represents animals implanted with PORESORB®-TCP seeded with pre-differentiated osteoblasts and endothelial-like cells; all groups stained with MTCO2, RECA and COL1. Data are presented as the number of positive stained sections in the whole sample group.

DISCUSSION

It has been established, that bone tissue engineering (BTE) using combinations of scaffold loaded with the cells is more effective than usage of scaffold or cells alone (1).

According to results of the presented study we proved that both predifferentiated and non-differentiated cells were able to survive within the scaffold for 14 days. But survival rate of the non-differentiated MSC were twice higher. Positive staining for human cells DNA and MTCO2 was positive in 57% slides acquired from the scaffolds loaded with undifferentiated MSC compared to 28% slides acquired from the scaffolds loaded with pre-differentiated MSC. As expected we haven't identified any newly created bone tissue within the samples of non-differentiated MSC group but surprisingly neither within the samples

used predifferentiated MSC, even though we proved the ability of osteoid matrix creation during in vitro study. We believed that this is the consequence of hypoxia and low nutrients supply. On the other side we were able to identify newly created vessels in all samples so we can predict that the proliferation, differentiation and creation of the bone tissue will start in the next phase of the regeneration. From above written we conclude that using the predifferentiated stem cells do not lead to the better results, but even more due to the lowered survival rate it can lead to delayed healing.

These findings are in contradiction with many other studies (12, 15) who reported that pre-differentiation of MSCs with inductive factors prior to transplantation may enhance the differentiation response and therefore enhance the healing process. This discrepancy can be explained by using different scaffold material, different size of scaffold, or more likely by using inductive factors within the scaffold. On the other side our finding supports the theory of Gronthos et al. (8) who presented that the survival of human MSCs depends on the immaturity of the cells, thus some applications may possibly require minimizing the maturation of MSCs. Shimizu et al. (11) observed the newly created bone 14 days after implantation, but compare to our study they used MSC pre-differentiated for 4 weeks and the cells were not seeded within the scaffold but in the multilayered sheet-like structure.

Our study supports Amini (2) who classifies the vascularization as the scaffold between the fundamental challenges of BTE. We have to take in mind that most of the in vivo studies (including our study) are done in the place where the scaffolds are surrounded by the soft tissue and not within the bone which will offer even lower chance for vascularization. How to deal with this challenging task? Vascularization depends on many different factors. First of all the scaffold porosity is crucial. In the study of Kara-

georgiou and Kaplan published in 2005 (9) was recommended to use at least 300 μm pores within the scaffold. Neo vascularization can be enhanced by the inclusion of the angiogenic growth factors (VEGF, PDGF and bFGF). The pros of this way are: easiness, possibility of controlled and prolonged releasing, but the cons are: high price and in case of not well balanced concentration the newly created vessels can lead to vascular leakage demonstrated by Zisch et al. (14). The last option is pre-vascularizations of the scaffold before implantation. This process can be done under in vivo or in vitro conditions. For in-vitro pre-vascularization is recommended to co-culture the scaffold with the endothelial and osteogenic cells before implantation. This leads to creation of immature vessels which will mature and connect with the recipient vessels after implantation. This method leads to increased bone formation in vivo (1, 4, 6). The second option is based upon the implantation of the scaffold within the well vascularized tissue. This will lead to ingrowth of the vessels into the scaffold and creation of mature arteries and veins. The pros of this procedure is the possibility to connect the scaffold vessel system directly to the recipient blood circulation using microsurgical and therefore obtained immediate blood perfusion. The cons consist in the long time preparation (the whole procedure takes several weeks – depending on the vascularization of the surrounding tissue), need of another surgical procedure (2).

CONCLUSION

Cell therapy is a perspective therapeutic approach in the treatment of bone defects and management of bone cysts. MSCs were compatible with the commercially available bone scaffold tricalcium phosphate and human MSCs were detected inside the implants 14 days after transplantation.

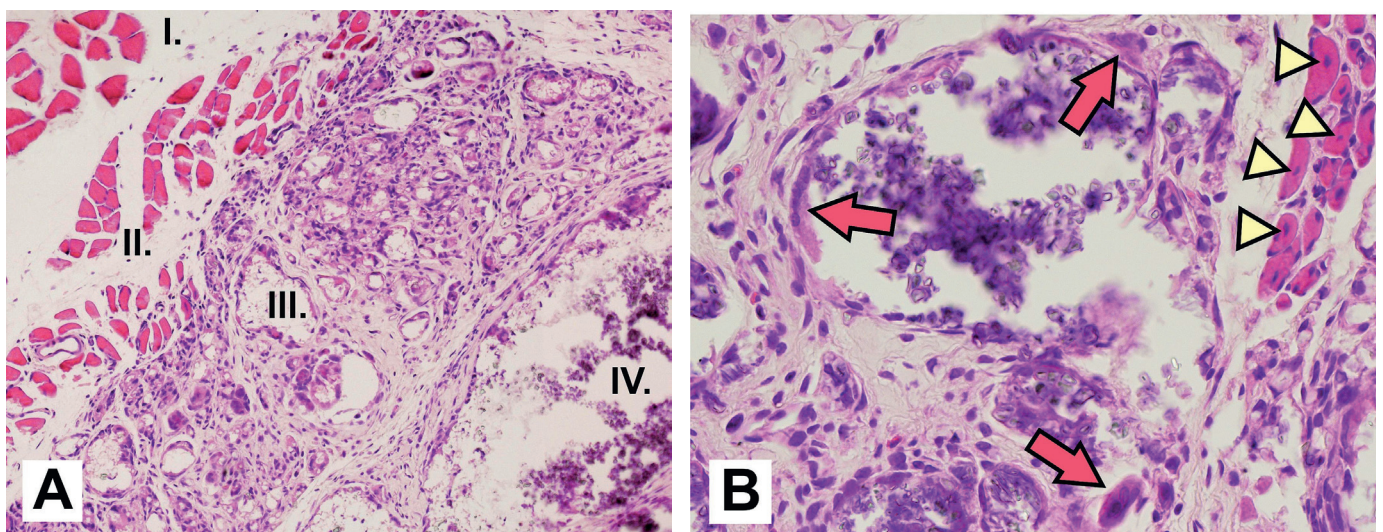


Fig. 3: Histological analysis of implant sections stained with hematoxylin eosin. A) Border area shows a stratification of reactions toward the implant. Zone I contains intact extrafusal skeletal muscle, zone II contains a muscle injured during implantation with signs of regeneration. The peripheral zone of the implanted material (zone III) is intermingled with degenerating muscle whereas the inner area (IV) shows the reaction of the host tissue to the implant. B) A detailed micrograph indicates the formation of giant multinucleated bodies at the surface of the implant (red arrows). Regenerating myotubes with centrally located nuclei are marked with yellow arrowheads (original magnification 400 \times).

This study showed no significant differences between using pre-differentiated osteoblasts combined with pre-differentiated endothelial cells in the bone scaffold and undifferentiated MSCs in the bone scaffold in terms of immune reaction, new vessel formation and bone formation. However, 14 days seem to be a short time for new bone formation assessment.

ACKNOWLEDGEMENTS

Supported by the PRVOUK P37/13 and PRVOUK P37/06.

CONFLICTS OF INTEREST

The authors declare that they have no conflicts of interests concerning this article.

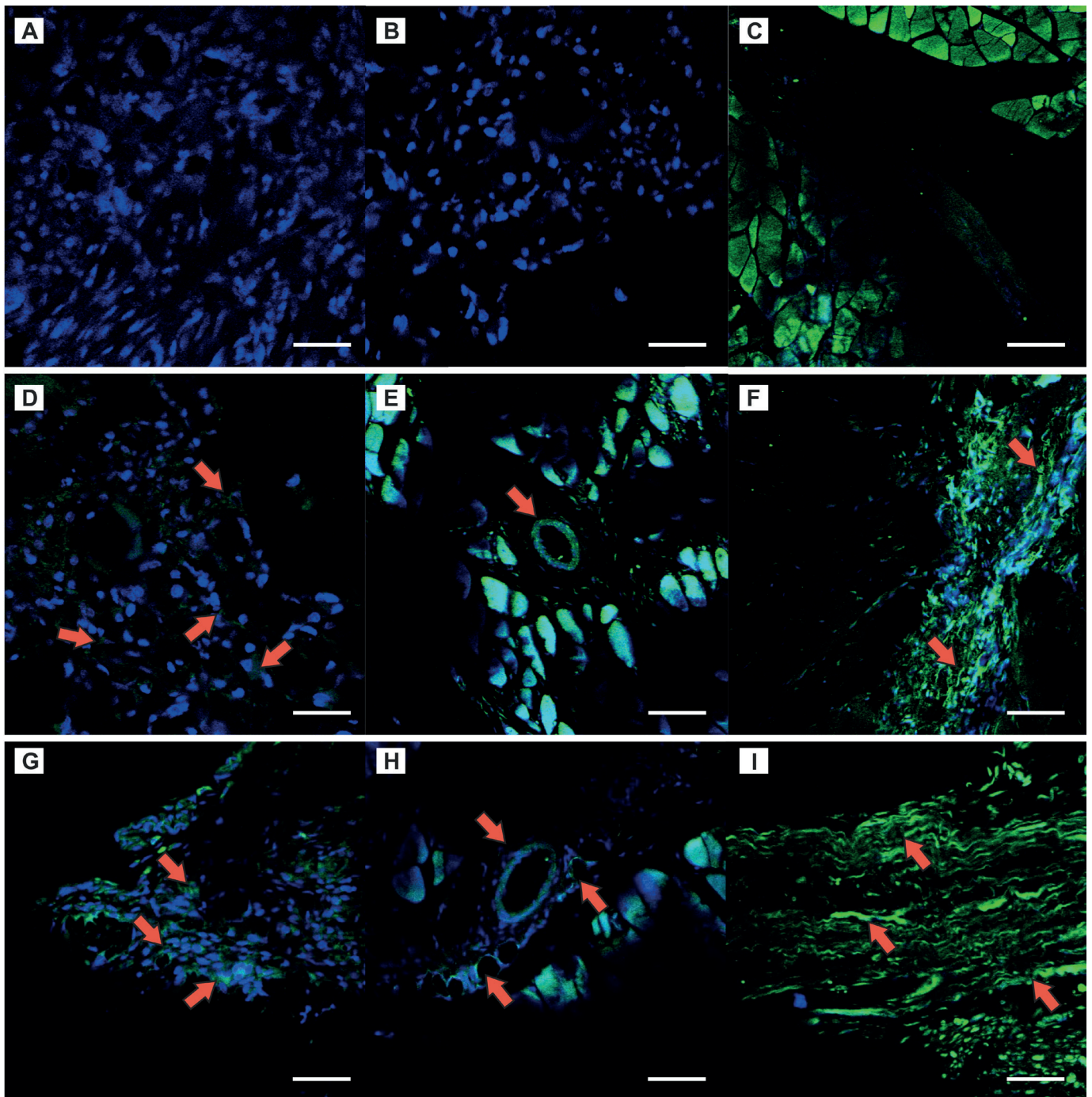


Fig. 4: Immunohistochemical analysis of implant sections. In rows sections from group 1 (n = 14), group 2 (n = 7) and group 3 (n = 7). Sections stained with DAPI and MTCO2 (A; D; G); arrows show mitochondria inside the cells of human origin. Sections stained with DAPI and RECA (B; E; H); arrows show endothelial cells (C; F; I). Arrows show positive COLL1 staining for detection of collagen type I of newly formed bone. Bars show 50 μ m.

REFERENCES

1. Amini AR, Laurencin CT, Nukavarapu SP. Bone tissue engineering: recent advances and challenges. *Crit Rev Biomed Eng* 2012; 40: 363–408.
2. Amini AR, Laurencin CT, Nukavarapu SP. Differential analysis of peripheral blood- and bone marrow-derived endothelial progenitor cells for enhanced vascularization in bone tissue engineering. *J Orthop Res* 2012; 30: 1507–1515.
3. Baroli B. From natural bone grafts to tissue engineering therapeutics: brainstorming on pharmaceutical formulative requirements and challenges. *J Pharm Sci* 2009; 98: 1317–1375.
4. Buschmann J, Welti M, Hemmi S, Neuenschwander P, Baltes C, Giovanoli P, Rudin M, Calcagni M. Three-dimensional co-cultures of osteoblasts and endothelial cells in DegraPol foam: histological and high-field magnetic resonance imaging analyses of pre-engineered capillary networks in bone grafts. *Tissue Eng Pt A* 2010; 17: 291–299.
5. Dimitriou R, Jones E, McGonagle D, Giannoudis PV. Bone regeneration: current concepts and future directions. *BMC Med* 2011; 9: 66.
6. Fedorovich NE, Haverslag RT, Dhert WJ, Alblas J. The role of endothelial progenitor cells in prevascularized bone tissue engineering: development of heterogeneous constructs. *Tissue Eng Pt A* 2010; 16: 2355–2367.
7. Gazdag AR, Lane JM, Glaser D, Forster RA. Alternatives to autogenous bone graft: efficacy and indications. *J Am Acad Orthop Sur* 1995; 3: 1–8.
8. Gronthos S, Chen S, Wang CY, Robey PG, Shi S. Telomerase accelerates osteogenesis of bone marrow stromal stem cells by upregulation of CBFA1, osterix, and osteocalcin. *J Bone Miner Res* 2003; 18: 716–22.
9. Karageorgiou V, Kaplan D. Porosity of 3D biomaterial scaffolds and osteogenesis. *Biomaterials* 2005; 26: 5474–5491.
10. Rosset P, Deschaseaux F, Layrolle P. Cell therapy for bone repair. *Orthop Traumatol Surg Res* 2014; 100: 107–112.
11. Shimizu K, Ito A, Yoshida T, Yamada Y, Ueda M, Honda H. Bone tissue engineering with human mesenchymal stem cell sheets constructed using magnetite nanoparticles and magnetic force. *J Biomed Mater Res B* 2007; 82: 471–480.
12. Schliephake H, Knebel JW, Aufderheide M, Tauscher M. Use of cultivated osteoprogenitor cells to increase bone formation in segmental mandibular defects: an experimental pilot study in sheep. *Int J Oral Max Surg* 2001; 30: 531–537.
13. Soucacos PN, Johnson EO, Babis G. An update on recent advances in bone regeneration. *Injury* 2008; 39: 1–4.
14. Zisch AH, Lutolf MP, Hubbell JA. Biopolymeric delivery matrices for angiogenic growth factors. *Cardiovasc Pathol* 2003; 12: 295–310.
15. Zhou G, Liu W, Cui L, Wang X, Liu T, Cao Y. Repair of porcine articular osteochondral defects in non-weightbearing areas with autologous bone marrow stromal cells. *Tissue Eng* 2006; 12: 3209–3221.

A Diagnostic Program of Vascular Tumor and Vascular Malformations in Children According to Modern Classification

Iryna Benzar*

ABSTRACT

The aim of the study was to analyze the cohort of inpatient children with vascular anomalies according to the globally accepted classification introduced by the ISSVA. Methods: The study included 205 inpatient children within the time period of the years 2010–2015. Types of vascular anomalies (VAs), age of patients, diagnostic procedures, and anatomical localization of VAs were analyzed. Results: 65 patients of first year of life had vascular tumors, with prevalence of infantile hemangiomas (IHs) in 57 (87.7%) patients. 45 children had IHs localized within soft tissues, whereas 7 patients suffered from IHs of the liver, and 5 children from IHs of the respiratory tract. Most patients with soft tissue IHs were diagnosed only with ultrasound; CT or MRI diagnostics were performed on 5 (8.8%) patients, and biopsy was carried out in 2 (4.4%) children. Vascular malformations (VM) were diagnosed in 140 (68.3%) patients. Ultrasound investigation (US) was the screening method. MRI was performed to confirm the diagnosis of low-flow VM, whereas for high-flow VM CT angiography and selective angiography were useful. Venous malformations were diagnosed in 17 (12.1%) patients, and 112 (80.0%) had cystic LM, among them children under the age of 2 years prevailed. Arteriovenous malformations were diagnosed in 5 (3.8%) patients, ages 2–14 years. Conclusions: Clinical manifestations of vascular anomalies have clear age features. Among hospitalized children vascular tumors add up to 31.7% and VM – up to 68.3%.

KEYWORDS

vascular anomalies; vascular tumors; vascular malformations; ISSVA Classification for vascular anomalies

AUTHOR AFFILIATIONS

Pediatric Surgery Department, Bogomolets National Medical University, Kyiv, Ukraine

* Corresponding author: 10G Vitryani Gory str, apt. 32, Kyiv, 04123, Ukraine; e-mail: ira_benzar@yahoo.com, iryna.benzar@nmu.ua

Received: 3 November 2016

Accepted: 12 January 2017

Published online: 26 May 2017

Acta Medica (Hradec Králové) 2017; 60(1): 19–26

<https://doi.org/10.14712/18059694.2017.47>

© 2017 The Author. This is an open-access article distributed under the terms of the Creative Commons Attribution License (<http://creativecommons.org/licenses/by/4.0>), which permits unrestricted use, distribution, and reproduction in any medium, provided the original author and source are credited.

BACKGROUND

The field of vascular anomalies (VAs) is considered to be a special focus of pediatric surgeons, and it has shown a rapid development during the last decade. Patients with VAs are always difficult to identify and clearly describe, given the large number of pathology and diverse terminology that is used in many medical institutions. Despite long-standing efforts to promulgate standard classification, nomenclature terminology of vascular anomalies is still confusing (1).

The long history of such confusing terminology complicated the communication between physicians of different specialties. The symbol of nomenclature inconsistencies is the term "hemangioma" which even now is widely used to describe various vascular lesions (2).

Because many VAs, including most uncomplicated IH, capillary local spots, etc., do not pose a threat to the life or health of the patient and do not require hospital treatment, these children may be under the supervision of outpatient pediatricians, dermatologists or surgeons. Other diseases are life threatening, have progressing outcome and potential dangers of complications. Introduction of the uniform classification will be the first step towards correct diagnosis and appropriate treatment.

The aim of this study was to analyze the inpatient group of patients with VAs and classify them according to the globally accepted classification introduced by the ISSVA (International Society for the Study of Vascular Anomalies) and to describe the diagnostic methods and findings used to distinguish separate groups.

The diagnosis of VAs was made according to the updated ISSVA (International Society for the Study of Vascular Anomalies) Classification of Vascular Anomalies that was adopted at the workshop in Melbourne, Australia (April 2014) (3). One of the goals of the ISSVA is to achieve a uniform classification (4). The new ISSVA classification scheme is based on the fundamental separation of vascular anomalies into those lesions with a proliferative component (named "vascular tumors") versus relatively static "vascular malformations," following Mulliken and Glowacki's (5).

MATERIAL AND METHODS

The retrospective study included 205 inpatient children with VAs in the time period from year 2010 to 2015, ages 1 month to 17 years. The age of patients, types of anomalies and their anatomical locations, type and amount of diagnostic procedures for the referred patient were analyzed. The first line investigation of all patients was ultrasound investigation with a 12-3 MHz linear transducer in gray scale mode, color Doppler scan (CDS) and partially in Doppler mode. The additional investigations included computed tomography (CT), both native and intravenous enhanced; magnetic resonance imaging (MRI), biopsy and selective angiography.

RESULTS

Vascular tumors were diagnosed in 65 patients with IHs predominance ($n = 57$; 87.7%). Soft tissue IHs were diagnosed in 45 children, 7 children had IHs of the liver and 7 children had IHs of the respiratory tract. The age of children with IHs at the time of hospitalization ranged from 1 to 11 months, with the age average of 3.8 months. The indications for hospitalization were IHs of difficult anatomical localization, which required further examination to clarify the underlying diagnosis, and complicated IHs, which needed hospital treatment.

To confirm the diagnosis of IHs of the skin, subcutaneous tissue, muscles, visible mucous membranes, ultrasound mode gray scale and color Doppler scans were used. The US features of IHs were determined by its growth phase. In proliferative phase they were presented as a hypoechoic lobular mass, CDS mode revealed maximum microcirculation and non-vascularized tissue was absent (Fig. 1).

In maturation and regression phases the structure of the IHs becomes hyperechoic, in CDS mode increasing ectatic drainage veins and declining arterialization of drainage veins were visualized (Fig. 2).

If the typical skin lesions were absent, and in cases of localization of IHs in deep tissues, additional method of visualization were used in 5 (8.8%) patients. It was intravenous enhanced CT (Fig. 3) in two cases, MRI in three children, and biopsy (Fig. 4) performed in two clinically unclear cases.

To confirm the diagnosis for IHs of the liver intravenous contrast-enhanced CT ($n = 6$) and MRI ($n = 1$) were performed. Three children had multiple skin hemangiomas and multiple hepatic hemangiomas. Diagnosis for IHs of the respiratory system in children with respiratory failure was determined by the results of laryngobronchoscopy. To determine the borders of lesions and the spreading throughout the mediastinum, an intravenous contrast-enhanced CT ($n = 4$) and MRI ($n = 1$) were performed.

Thrombocytopenia, the so-called Kasabach-Merritt phenomenon occurred only in two children with vascular tumors: in a newborn girl with Kaposiform hemangioendothelioma (platelet count $8-10 \times 10^3/\text{mL}$) and moderate thrombocytopenia in a 4-month-old girl with tufted angioma (platelet count $80-90 \times 10^3/\text{mL}$). There were no coagulation disorders in patients with IHs.

Rapidly involuting congenital hemangiomas (RICH) were diagnosed in 5 patients. Localizations of RICHs were at the head and neck region ($n = 2$), upon extremities ($n = 2$) (Fig. 5), and in the liver ($n = 1$).

Vascular malformations (VM) were diagnosed in 140 (68.3%) of the hospitalized patients. During the primary investigation of patients with vascular malformations US visualization with Doppler mode allowed to differentiate fast flow and slow flow malformations. To confirm the diagnosis of slow flow vascular malformation MRI was performed. High flow vascular malformations were visualized by CT angiography and selective angiography.

VM were diagnosed in 17 children ages from 1 month to 17 years, the average age being 7.4 years. The percentage rate of VM was 12.1% out of all vascular malformations.

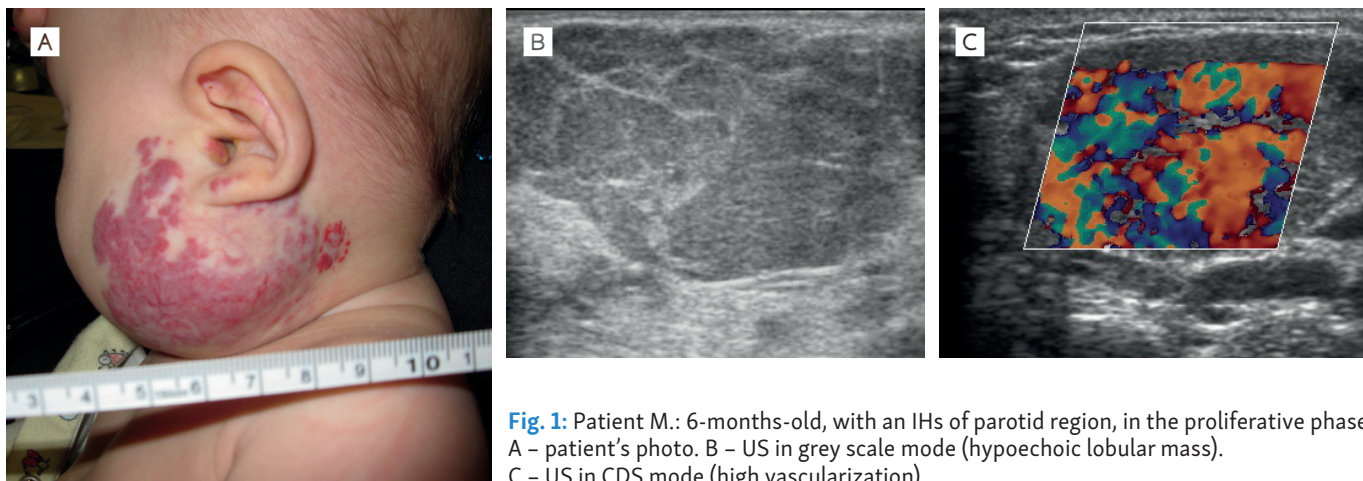


Fig. 1: Patient M.: 6-months-old, with an IHs of parotid region, in the proliferative phase. A – patient’s photo. B – US in grey scale mode (hypoechoic lobular mass). C – US in CDS mode (high vascularization).

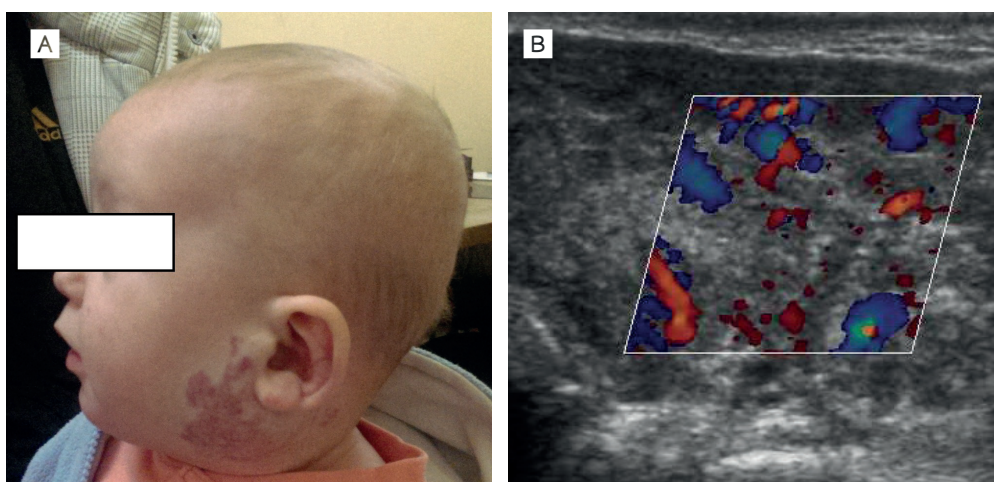


Fig. 2: Patient M.: 11-months-old, with an IHs of the parotid region, in the maturation phase. A – patient’s photo. B – US in CDS mode (circumscribed hyperechoic area, ectatic veins on the background of non-vascularized tissue).

At US, VM were represented as a compressible fluid-filled cavitory septate lesions with inhomogeneous echogenicity, its lumen could often reveal pathognomonic phleboliths with acoustic shadow. On MRI VM were visualized as single or multiple masses, lobular or cavernous structures sometimes with infiltration of the surrounding tissues. Loss of signal was the sign of clots or phleboliths (Fig. 6)

D-dimer level elevation more than three times occurred in 14 (82.4%) patients with VMs. Three of them had low fibrinogen level.

Most children (n = 112) had cystic lymphatic malformations (LM). The percentage rate of LM among the patients with vascular malformations was 80%. In 12 (10.7%) patients the diagnosis was made at an US screening investigation. Immediately after birth, the clinical manifestations

were found in 49 (43.75%) children. Before the age of two years LM were diagnosed in 35 (31.25%) patients. Overall, in 85.7% of patients with cystic LM, primary symptoms were revealed during first two years of life, and in the other 16 children (14.3%) these symptoms were found at different age periods, particularly in 9 children (8.0%) ages 2 to 5 years, in 4 children (3.6%) from 5 to 12 years, and in 3 (2.7%) of those over 12 years of age.

We usually performed MRI before treatment. According to the results of MRI, the size and structure of LM, and also their topographical relationship with neighboring organs and tissues were determined. LM were classified as macrocystic, microcystic, and mixed (Fig. 7).

Arteriovenous malformations (AVM) were diagnosed in 5 (2.4%) children. The patients’ age ranged from 2 to 14

Tab. 1: The anatomical localization of vascular tumors (n = 65).

	Head/neck	Trunk	Extremity	Visceral	Total / percentage
Total	26 (40.0%)	4 (6.2%)	22 (33.8%)	13 (20.0%)	65 (100%)
IHs	24 (42.1%)	4 (7.0%)	17 (29.8%)	12 (21.1%)	57 (87.7%)
Congenital hemangiomas	2 (40.0%)		2 (40.0%)	1 (20.0%)	5 (7.7%)
Tufted angioma / Kaposiform hemangioendothelioma			3 (100%)		3

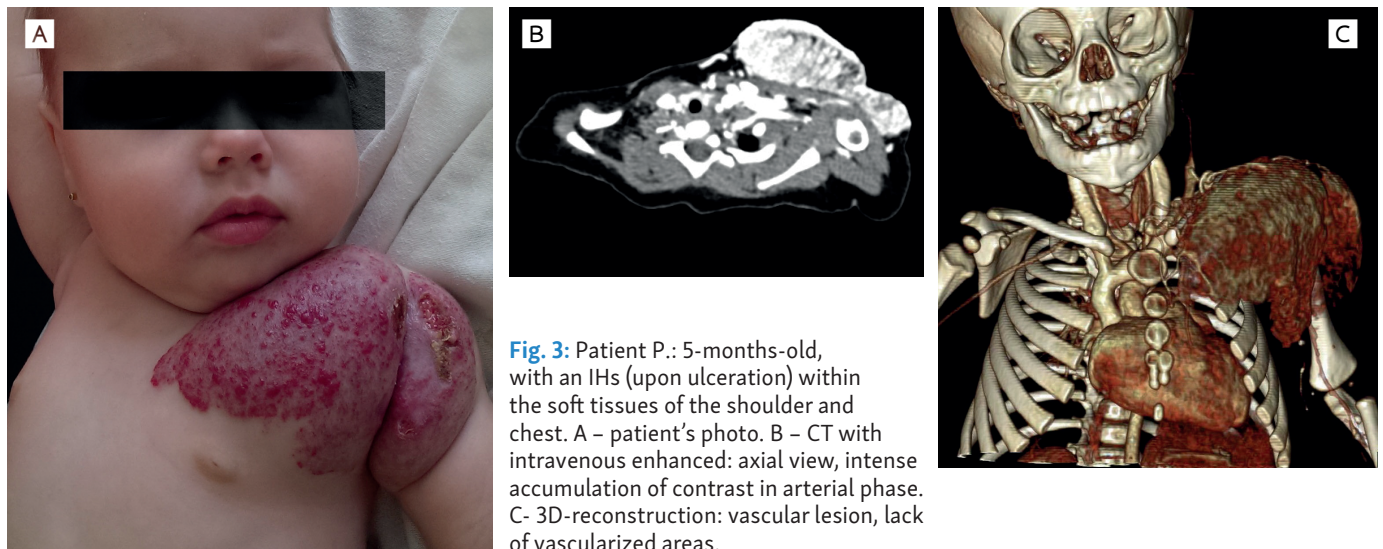


Fig. 3: Patient P.: 5-months-old, with an IHs (upon ulceration) within the soft tissues of the shoulder and chest. A – patient's photo. B – CT with intravenous enhanced: axial view, intense accumulation of contrast in arterial phase. C- 3D-reconstruction: vascular lesion, lack of vascularized areas.

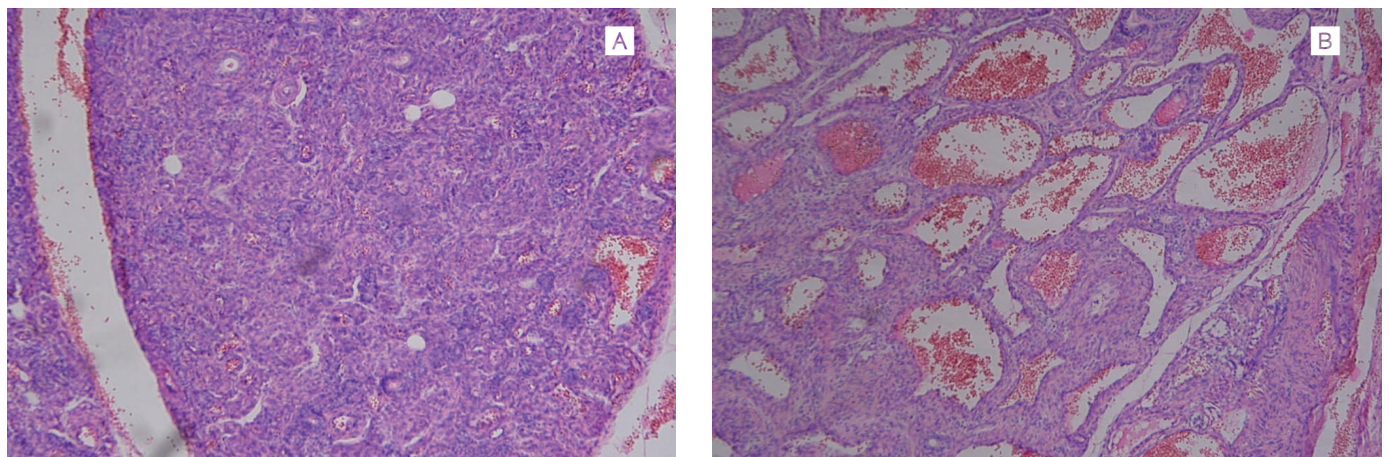


Fig. 4: Light microscopy, hematoxylin-eosin staining, $\times 10$. A – IH, proliferative phase: dense clusters of cells, lumens difficult to discern. B – IH, maturation phase: dilated vascular channels, small foci of proliferation.

years, with the age average of 8.2 years. AVM were often difficult to distinguish from other vascular malformations and some vascular tumors. AVM at US in CDS mode had the same features as IHs in proliferative phase, however vascularization intensity did not decrease with age (Fig. 8).

CT angiography was performed in all patients. This study allowed the visualization of both normal and pathologically altered vessels and their connections. Selective angiography was performed in three patients immediately before treatment. According to the results of investigation,

features of the anatomical location of vascular tumors and vascular malformations were established, and they are presented in Tab. 1 and Tab. 2.

DISCUSSION

A worrying sign is that more than half of patients with VAs come to specialized centers with an incorrect diagnosis (6). The reason for this may be lack of consistency in

Tab. 2: The anatomical localization of vascular malformations (n = 134*).

	Head/neck	Trunk	Exterimity	Viscera	Total / percentage
Total	74 (55.2%)	19 (14.2%)	16 (11.9%)	25 (18.7%)	134 (100%)
LM	67 (59.8%)	13 (11.6%)	9 (8.1%)	23 (20.5%)	112 (83.5%)
VM	3 (17.6%)	6 (35.3%)	6 (35.3%)	2 (11.8%)	17 (12.7%)
AVM	4 (80.0%)		1 (20.0%)		5 (3.8%)

* Combined vascular malformations are not taken into account because they affect different anatomical regions.

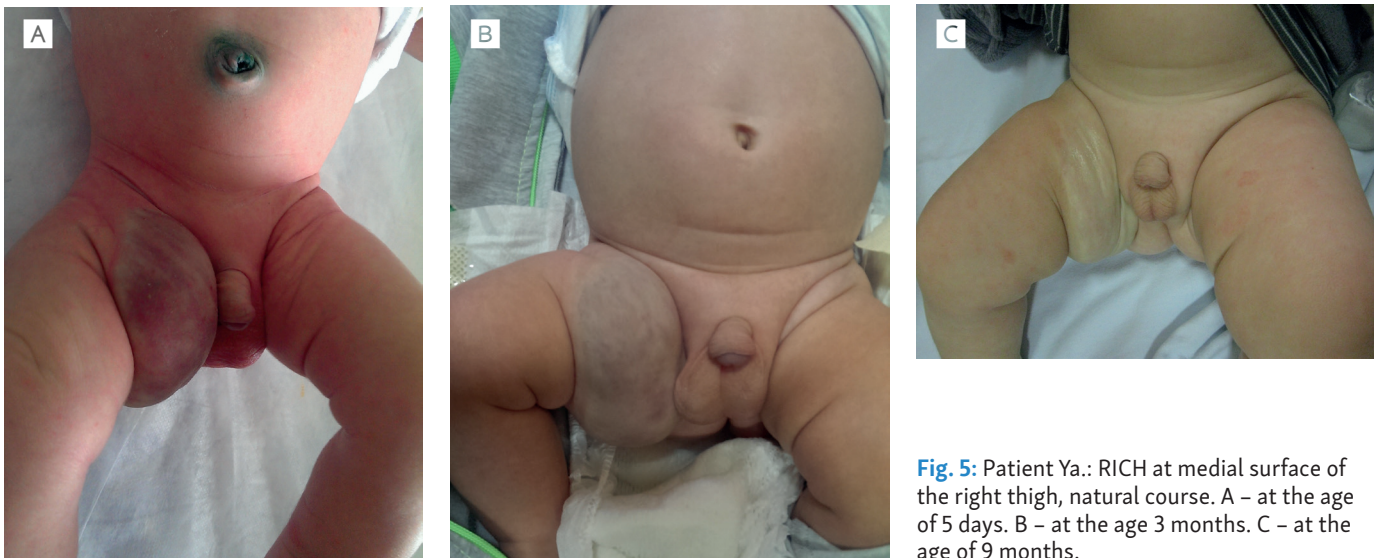


Fig. 5: Patient Ya.: RICH at medial surface of the right thigh, natural course. A – at the age of 5 days. B – at the age 3 months. C – at the age of 9 months.

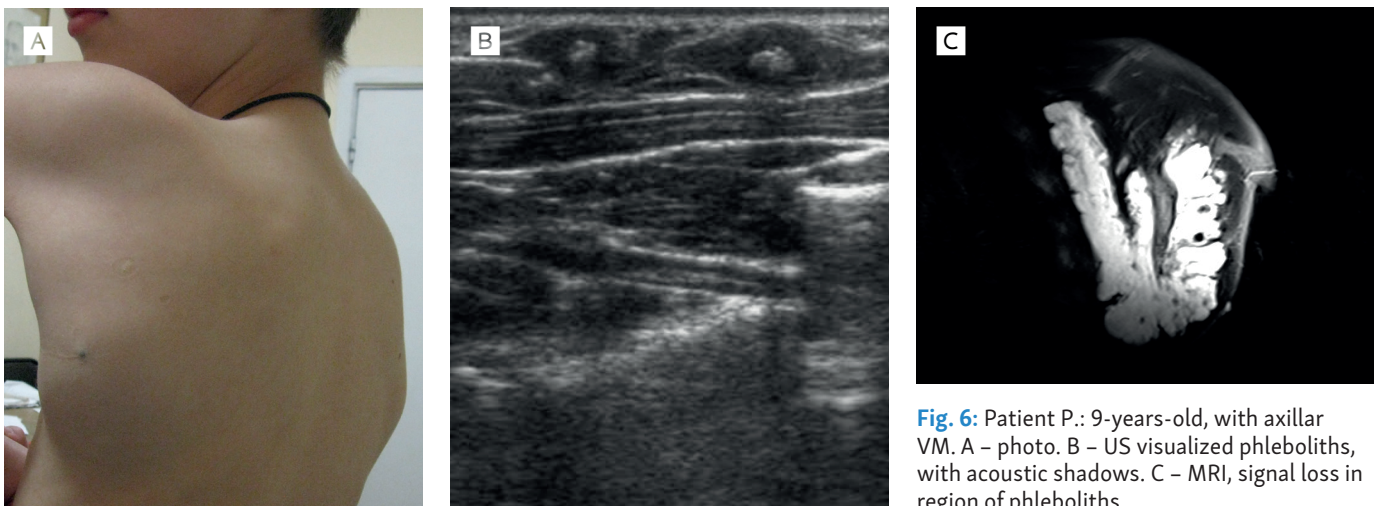


Fig. 6: Patient P.: 9-years-old, with axillar VM. A – photo. B – US visualized phleboliths, with acoustic shadows. C – MRI, signal loss in region of phleboliths.

terminology and use of inappropriate imaging techniques for diagnosis. The study confirms that VM are much more difficult to diagnose than vascular tumors, and require the use of a wide range of additional research methods. Although VM (1 in 200 people) occur 10 times less commonly than vascular tumors (1 in 20 people) (7), they account for over two thirds of patients who require hospitalization.

In most cases the diagnosis of IHs of the skin is made only according to the results of physical examination. However in some cases (for example, normal skin and a mass in deep soft tissues, and atypical cutaneous manifestations, complicated localization) diagnosis based solely on the examination of the patient may lead to diagnostic and, subsequently, to tactical mistakes (8). Early diagnosis is very important to determine the therapeutic tactics whether active or expectant (9). MRI in patients with IHs of the soft tissues is used as a reserved method of visualization only in unusual cases, atypical clinical presentation, and in patients with large IHs existing at birth, to determine the borders of the lesion and the characteristics of tissue and vascularization of effected area.

Congenital hemangiomas complete their growth and maturation prenatally and should be clearly differenti-

ated from IHs. Congenital hemangiomas, both with rapid involution and without involution, are solitary tumor, frequently located on the extremities near large joints or on the scalp (10). An US examination shows arteries and veins that pass vertically towards the surface of the tumor (11). Congenital hemangiomas are rare tumors, with various, sometimes not classic symptoms, that can mask other diseases, thus observation in medical centers is required.

Kaposiform hemangioendothelioma and tufted angioma are rare vascular tumors that occur in early childhood and can occasionally occur in adults. Both tumors are characterized by local aggressive growth and may be accompanied by a Kasabach-Merritt phenomenon, which is a coagulopathy, associated with severe thrombocytopenia and hypofibrinogenemia (12, 13).

Historically in young children VM are mistaken for IHs, and labeled with an outdated term “cavernous hemangiomas”. While the most common IHs are specific tumors of the childhood age with spontaneous involution, VM are remnants of embryonic tissue that never disappears spontaneously (14). A clear understanding of these critical factors and the exact wording of the diagnosis are essential for successful treatment (15). According to published

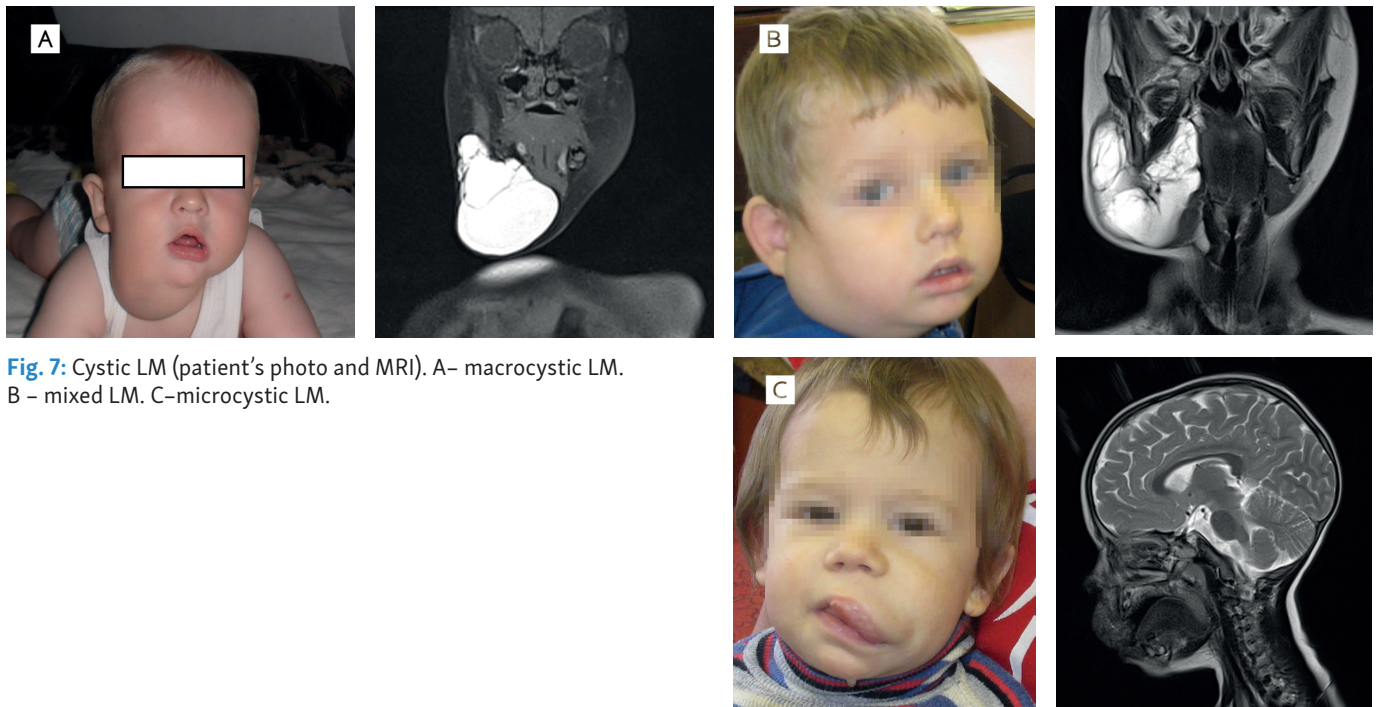


Fig. 7: Cystic LM (patient's photo and MRI). A- macrocystic LM. B - mixed LM. C-microcystic LM.

data, VM are the most common congenital vascular malformations with a frequency of 1-2 : 10,000 (16). However, in pediatric clinic, the percentage of VM was only 12.1% out of patients with vascular malformations. Abnormal veins sometimes are visible already at an early age, but the peak of clinical manifestations accounts for about 20 years, at least 10% of limbs VM are visually seen before the adolescent age (17). This may explain the discrepancy of statistical data in the general population and pediatric clinic. As well there are different statistics in different age groups. In particular, large lymphatic malformations with the compression of adjacent organs dominates among newborns, IHs dominate among children of the first three years of life, and LM causing primarily cosmetic deformity significantly prevail among children older than three years of age.

MRI sequences routinely are used to image vascular malformations. T1 and T2 weighted MRI are the "gold standard" for investigating slow flow vascular malformations, which is necessary to be performed before starting treatment. VM are visualized as a single or multiple lobular or cavernous masses, sometimes with infiltrative growth, isointensity or hypointensity on T1 weighted, and

hyperintensity on T2 weighted and STIR (Short Tau Inversion Recovery) (18).

VM are accompanied by spontaneous thrombosis and thrombolysis (19, 20). Coagulation disorders are the result of chronic venous blood stagnation within the large irregular vascular spaces, leading to activation of coagulation cascade reactions following production of thrombin, the conversion of fibrinogen into fibrin, which induces the blood clot formation. (21). Following thrombosis, the process of thrombolysis starts, a reflection of which is to increase fibrin degradation products, including derived plasmin epitope D-dimer, which is called "a new diagnostic biomarker" to VM (22), because D-dimer level is increased in most patients with VM. In patients within our study group it increased in 82.4% of patients with VM. The newly formed microclots bind with plasma ionized calcium and form so-called "phleboliths", pathognomonic stone-like structures (23). According to published data, only half of LM have clinical signs at birth, 90% of LM are detected within the first two years of life, and the rest 10% are diagnosed at any age (24). In our clinical group, symptoms of LM appeared during the first two years of life in 85.7% of patients. Sometimes LM, especially if they are

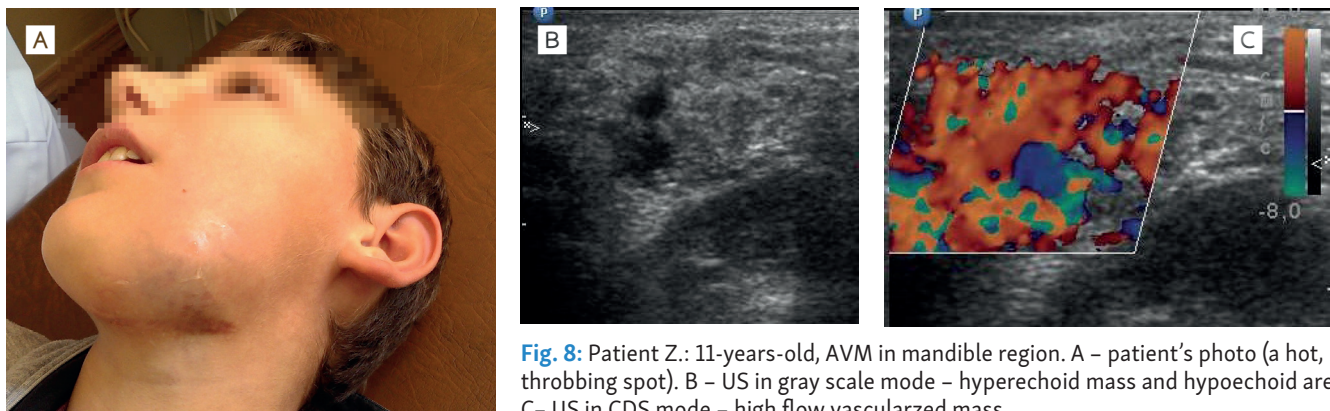


Fig. 8: Patient Z.: 11-years-old, AVM in mandible region. A - patient's photo (a hot, throbbing spot). B - US in gray scale mode - hyperechoid mass and hypoechoid areas. C- US in CDS mode - high flow vascularized mass.

large, can be detected during a prenatal screening ultrasound scan. The diagnosis was made prenatally in 10.7% of 112 children with LM. MRI is a routine diagnostic method in children with LM. At MRI it is possible to determine the structure of the mass, cyst size, thickness of membranes and conditional ratio of liquid, measure the borders of lesion, as well as determine the topographical relationships with the surrounding tissues. At MRI the boundaries between normal and affected soft tissue structures is clearly defined. Cysts filled with high protein fluid have high signal on T2, and are dark-color on T1. The most common is the classification of LM according the cyst's size: macrocystic, microcystic and mixed (25, 26). The size of cysts is relative, and in different data they range from 0.5 to 2 cm³. This division has practical importance. If the cyst can be successfully punctured and medication can be safely injected in its cavity, this LM is prognostically more favorable.

AVM are the congenital malformations of both arterial and venous blood vessels, resulting in the formation of connections between vessels of different origin, diameter and resistance (27). These connections can be either direct or passing through the reticular structures, which is a net of dysplastic small vessels that have broken capillaries to maturation, and are called "nidus".

The most common AVM are those of central nervous system (CNS). Extracranial AVM are relatively rare, and their true prevalence in children is unknown. Liu A.S. et al. presents the largest group of patients with extracranial AVM (28), including 272 patients, both children and young adults. AVM percentage rate is 14.3% among patients with vascular malformations (29), but they rarely have clinical manifestation in the childhood age. In our pediatric group of patients with AVM, there 3.8% of patients with vascular malformations, who presented with clinical symptoms (usually bleeding). The primary symptoms of superficial AVM are visible in early childhood, but during the period of childhood in most patients significant changes and complications are not observed. In newborn children AVM visually present as pink or red spots, and at this stage any known methods of visualization cannot distinguish AVM and capillary spots (30). Children with the suspicion of AVM should be treated by performing basic non-invasive and minimally invasive techniques: US and Doppler mode and CT angiography with 3D reconstruction. Selective angiography should be performed in children immediately before treatment.

CONCLUSIONS

Adaptation and implementation of a uniform system of classification in everyday practice is the first step towards determining the correct diagnosis and treatment of VAs. In our group, like tumors and malformations, VAs were most commonly localized in the head and neck region. Clinical manifestations of VAs had clear age features. Vascular tumors among hospitalized patients made up 31.7%, and the other 68.3% of patients had vascular malformations. Diagnosis of vascular malformations and rare vascular tumors

should be made in a specialized center by using a diagnostic algorithm, to avoid erroneous diagnosis and to exclude more invasive diagnostic procedures.

REFERENCES

- Hassanein AH, Mulliken JB, Fishman SJ, Greene AK. Evaluation of terminology for vascular anomalies in current literature. *Plast Reconstr Surg* 2011; 127(1): 347-51.
- Puttgen K, Pearl M, Tekes A, Mitchell SE. Update on pediatric extracranial vascular anomalies of the head and neck. *Childs Nerv Syst* (2010); 26: 1417-33.
- Dasgupta R, Fishman SJ. ISSVA classification. *Seminars in Pediatric Surgery* 2014; 23: 158-61.
- Wassef M, Blei F, Adams D, et al. Vascular Anomalies Classification: Recommendations From the International Society for the Study of Vascular Anomalies. *Pediatrics* 2015; 136(1): e203-15.
- Mulliken JB, Glowacki J. Hemangiomas and vascular malformations in infants and children: a classification based on endothelial characteristics. *Plast Reconstr Surg* 1982; 69: 412-22.
- Konez O, Burrows PE. Magnetic resonance of vascular anomalies. *Magn Reson Imaging Clin N Am* 2002; 10(2): 363-88.
- Greene AK, Liu AS, Mulliken JB, Chalache K, Fishman SJ. Vascular anomalies in 5621 patients: guidelines for referral. *Journal of Pediatric Surgery* 2011; 46:1784-89.
- Dubois J, Garel L. Imaging and therapeutic approach of hemangiomas and vascular malformations in the pediatric age group. *Pediatr Radiol* 1999; 29: 879-93.
- Eivazi B, Ardelean M, Bäumlner W, et al. Update on hemangiomas and vascular malformations of the head and neck. *European Archives of Oto-Rhino-Laryngology* 2008; 266(2): 187-97.
- Liang MG, Frieden IJ. Infantile and congenital hemangiomas. *Seminars in Ped Surg* 2014; 23: 162-7.
- Donaldson JS. Pediatric vascular anomalies: the role of imaging and interventional radiology. *Pediatr Ann* 2008; 37: 414-24.
- Ryan C, Price V, John P, et al. Kasabach-Merritt phenomenon: a single centre experience. *Eur J of Haematol* 2010; 84(2): 97-104.
- Croteau SE, Liang MG, Kozakewich HP, et al. Kaposiform hemangioendothelioma: atypical features and risks of Kasabach-Merritt phenomenon in 107 referrals. *Pediatr* 2013; 162(1): 142-7.
- Dasgupta R, Patel M. Venous malformations. *Seminars in Ped Surgery* 2014; 23: 221-6.
- Lee BB, Baumgartner I, Berlien P, et al. Diagnosis and treatment of venous malformations. Consensus Document of the International Union of Phlebology (IUP): Updated-2013. *Int Angiol* 2013; 34(2): 97-149.
- McRae MY, Adams S, Pereira J, Parsi K, Wargon O. Venous malformations: clinical course and management of vascular birthmark clinic cases. *Australas J Dermatol* 2013 54: 22-30.
- Upton J, Taghnia A. Special considerations in vascular anomalies: operative management of upper extremity lesions. *Clin Plast Surg* 2011; 38(1): 143-51.
- Fayad LM, Fayad L, Hazirolan T, Bluemke D, Mitchell S. Vascular malformations in the extremities: emphasis on MR imaging features that guide treatment options. *Skeletal Radiol* 2006; 35: 127-137.
- Domp Martin A, Acher A, Thibon P, et al. Association of Localized Intravascular Coagulopathy With Venous Malformations. *Arch Dermatol* 2008; 144(7): 873-7.
- Mazoyer E, Enjolras O, Bisdorff A, Perdu J, Wassef M, Drouet L. Coagulation disorders in patients with venous malformation of limbs and trunk: a case series of 118 patients. *Arch Dermatol* 2008; 144: 861-7.
- Redondo P, Aguado L, Marquina M, et al. Angiogenic and prothrombotic markers in extensive slow-flow vascular malformations: implications for antiangiogenic/antithrombotic strategies. *British Journal of Dermatology* 2010; 162: 350-6.
- Weibel L. Vascular anomalies in children. *Vasa* 2011; 40:439-47.
- Hein KD, Mulliken JB, Kozakewich HP, Upton J, Burrows PE. Venous malformations of skeletal muscle. *Plast Reconstr Surg* 2002; 110(7): 1625-35.
- Acevedo JL, Shah RK, Brietzke SE. Nonsurgical therapies for lymphangiomas: a systematic review. *Otolaryngology Head and Neck Surgery* 2008; 138(4): 418-24.
- Smith MC, Zimmerman MB, Burke DK, Bauman NM, Sato Yu, Smith RJH. Efficacy and Safety of OK-432 Immunotherapy of Lymphatic Malformations. *J Laryngoscope* 2009; 119: 107-15.
- Khunger N. Lymphatic Malformations: Current Status. *J Cutan Aesthet Surg* 2010; 3(3): 137-8.

27. Uller W, Alomari AI, Richter GT. Arteriovenous malformations. *Semin Pediatr Surg* 2014; 23(4): 203-7.
28. Liu AS, Mulliken JB, Zurakowski D, Fishman SJ, Greene AK. Extracranial arteriovenous malformations: natural progression and recurrence after treatment. *Plast Reconstr Surg* 2010; 125(4): 85-94.
29. Leeb BB, Lardeo J, Neville R. Arterio-venous malformation: how much do we know? *Phlebology* 2009; 24: 193-200.
30. Paltiel HJ, Burrows PE, Kozakewich HP, Zurakowski D, Mulliken JB. Soft-tissue vascular anomalies: Utility of US for diagnosis. *Radiology* 2000; 214: 747-54.

Serum Level of Antibodies (IgG, IgM) Against Benzo[a]pyrene-7,8-diol-9,10-epoxide-DNA Adducts in Children Dermatologically Exposed to Coal Tar

Pavel Borský¹, Ctirad Andrýs², Jan Krejsek², Květoslava Hamáková³, Jan Kremláček⁵, Andrea Málková¹, Lenka Bartošová¹, Zdeněk Fiala¹, Vladimír Palička⁴, Lenka Borská^{5,*}

ABSTRACT

Crude coal tar (CCT) contains polycyclic aromatic hydrocarbons (PAHs). Benzo[a]pyrene (BaP) is metabolized into a highly reactive metabolite benzo[a]pyrene-7,8-diol-9,10-epoxide (BPDE) that is able to bind to DNA and creates BPDE-DNA adducts. Adducted DNA becomes immunogenic and induces immune response by production of antibodies against BPDE-DNA adducts (Ab-BPDE-DNA). Circulating Ab-BPDE-DNA was proposed as potential biomarker of genotoxic exposure to BaP (PAHs). Goeckerman therapy (GT) of psoriasis uses dermal application of CCT ointment (PAHs). In presented study (children with psoriasis treated by GT; n = 19) the therapy significantly increased the level of Ab-BPDE-DNA (EI = 0.29/0.19–0.34 vs. 0.31/0.25–0.40; median/lower–upper quartile; p < 0.01). The results support the idea of Ab-BPDE-DNA level as a possible tentative indicator of exposure, effects and susceptibility of the organism to the exposure of BaP (PAHs).

KEYWORDS

polycyclic aromatic hydrocarbons; coal tar; BPDE-DNA adducts; antibodies; psoriasis; goeckerman therapy; children

AUTHOR AFFILIATIONS

¹ Institute of Hygiene and Preventive Medicine, Charles University, Faculty of Medicine, Hradec Králové, Czech Republic

² Institute of Clinical Immunology and Allergology, Charles University, Faculty of Medicine, Hradec Králové, Czech Republic

³ Clinic of Dermal and Venereal Diseases, Charles University Hospital, Hradec Králové, Czech Republic

⁴ Institute of Clinical Biochemistry and Diagnostics, Charles University Hospital and Faculty of Medicine, Hradec Králové, Czech Republic

⁵ Institute of Pathological Physiology, Charles University, Faculty of Medicine, Hradec Králové, Czech Republic

* Corresponding author: Institute of Pathological Physiology, Charles University, Faculty of Medicine in Hradec Králové, Šimkova 870, 500 03 Hradec Králové, Czech Republic; e-mail: borka@lfhk.cuni.cz

Received: 11 November 2016

Accepted: 21 January 2017

Published online: 3 May 2017

Acta Medica (Hradec Králové) 2017; 60(1): 27–31

<https://doi.org/10.14712/18059694.2017.46>

© 2017 The Authors. This is an open-access article distributed under the terms of the Creative Commons Attribution License (<http://creativecommons.org/licenses/by/4.0>), which permits unrestricted use, distribution, and reproduction in any medium, provided the original author and source are credited.

INTRODUCTION

Psoriasis is a multifactorial, chronic inflammatory skin disease, which often breaks out during childhood. Although the incidence of childhood psoriasis is unknown, some studies indicate that the first sign of psoriatic symptoms occurs in infants, children, and adolescents (1, 2). It is estimated that 30–50% of adults with psoriasis develop the condition before the age of 20 years (2). Psoriasis can adversely affect the quality of life (3) and represents the top 10 skin diagnoses in children (4).

Children are more susceptible to genotoxic effects of environmental exposures and medical treatments than adults because their organism is still developing (5). Recent trends in childhood cancers in the USA and Europe seem to confirm children's increased exposures to genotoxic/carcinogenic substances (6).

Goeckerman therapy (GT) represents a treatment of plaque psoriasis in children (7). The therapy combines dermal exposure of crude coal tar (CCT) ointment and UV radiation (UVR) (7–12). It seems that fundamental mechanism of therapeutic effects of CCT is based on immunosuppression induced by polycyclic aromatic hydrocarbons in coal tar (PAHs) without signs of systemic immunotoxicity (9, 12). Retrospective studies have demonstrated that GT is effective in children and adolescents with moderate to severe psoriasis (7–12). However, the use of GT has recently decreased for several reasons, including a supposed genotoxicity of CCT/PAHs (13–14).

Several PAHs are recognized as potential environmental mutagens and carcinogens requiring bioactivation (15). Typical representative of PAHs, benzo[a]pyrene (BaP), is bioactivated (metabolized) into a highly reactive genotoxic metabolite, benzo[a]pyrene-7,8-diol-9,10-epoxide (BPDE), which is able to bind to DNA or proteins and create corresponding BPDE-DNA or BPDE-protein adducts (14). Increased levels of BPDE adducts indicate recent genotoxic exposure to BaP (5). Cigarette smoke contains PAHs (including BaP) and this way contributes to the total level of BPDE and related adducts in smokers (16).

Adducted DNA becomes immunogenic and induces immune response by production of antibodies against BPDE-DNA adducts (Ab-BPDE-DNA). Circulating Ab-BPDE-DNA have been found in the serum of persons exposed to PAHs/BaP (occupational exposures, smokers) (17, 18) and subsequently they were proposed as a potential biomarker of genotoxic exposure to BaP (PAHs) (19, 20). The number of studies dealing with this biomarker is relatively small and its practical use is still associated with uncertainties. Those are associated with individual factors, which are still largely unidentified (20). In order to contribute to reduction of the uncertainties, the presented study describes level of Ab-DNA-BPDE in the group of children dermally exposed to PAHs.

MATERIALS AND METHODS

STUDY GROUP

Basic characteristics of the study group were described in our previous work (8). Briefly, the group was formed

of children with chronic stable plaque psoriasis, treated by GT at the Clinic of Dermal and Venereal Diseases, University Hospital, Hradec Králové (Czech Republic). Over the period of two years, we collected the data of 19 children (12 girls and 7 boys; average age of 12 years; range 5–17 years). Patients' exposure history to PAHs (including smoking) was checked by the questionnaire and patients who admitted previous significant exposure were excluded from the monitored group. The study was approved by the Ethics Committee of the University Hospital in Hradec Králové, Czech Republic. Informed written consent was obtained from the parents of each patient.

GOECKERMAN THERAPY (GT)

Detailed treatment procedure and the content of 16 selected PAHs in dermatological CCT were described previously (8). The therapy was based on daily application of dermatological ointment, containing 3% of CCT. According to the extent of lesions, 17–40% of the total body surface was covered by CCT ointment. Simultaneously, the patients were daily whole-body irradiated by UVR. Duration of the treatment was modified according to its effectiveness (average duration of 18 days; range 14–22 days). The effectiveness of the therapy was expressed by PASI score (Psoriasis Area and Severity Index) (21).

SERUM LEVEL OF AB-BPDE-DNA

The samples of heparinized venous blood were collected by venipuncture of the cubital vein before the first treatment and again after the total completion of GT. The obtained serum samples were stored in under -70°C until they were analyzed. The level of Ab-BPDE-DNA (IgG, IgM) was determined by ELISA method. The results were expressed as the Evaluation Index (EI = absorbance of evaluated serum / absorbance of high positive control serum). Samples with EI less than 0.5 were termed as the serum with low level of Ab-BPDE-DNA. Analogously, the serum samples with EI greater than 0.5 were referred to as the serum with high level of Ab-BPDE-DNA (ELISA-VIDITEST anti-BPDE-DNA human, VIDIA, Jesenice, Czech Republic).

STATISTICAL ANALYSIS

The data were analyzed by using MATLAB rel. 2014b software (Mathworks, Inc., Massachusetts, USA). Because the Lilliefors test of normality had rejected the hypothesis of normal distribution, the nonparametric tests were used. Data were analyzed by the Wilcoxon signed rank test. The association between the serum level of Ab-BPDE-DNA after the therapy and the selected parameters was evaluated by Spearman rank Order Correlations.

RESULTS

In the group of children with psoriasis, dermatologically exposed to coal tar (within the GT) we evaluated the efficacy of the therapy and observed the level of Ab-BPDE-DNA. Smoking was reported by five patients. The number

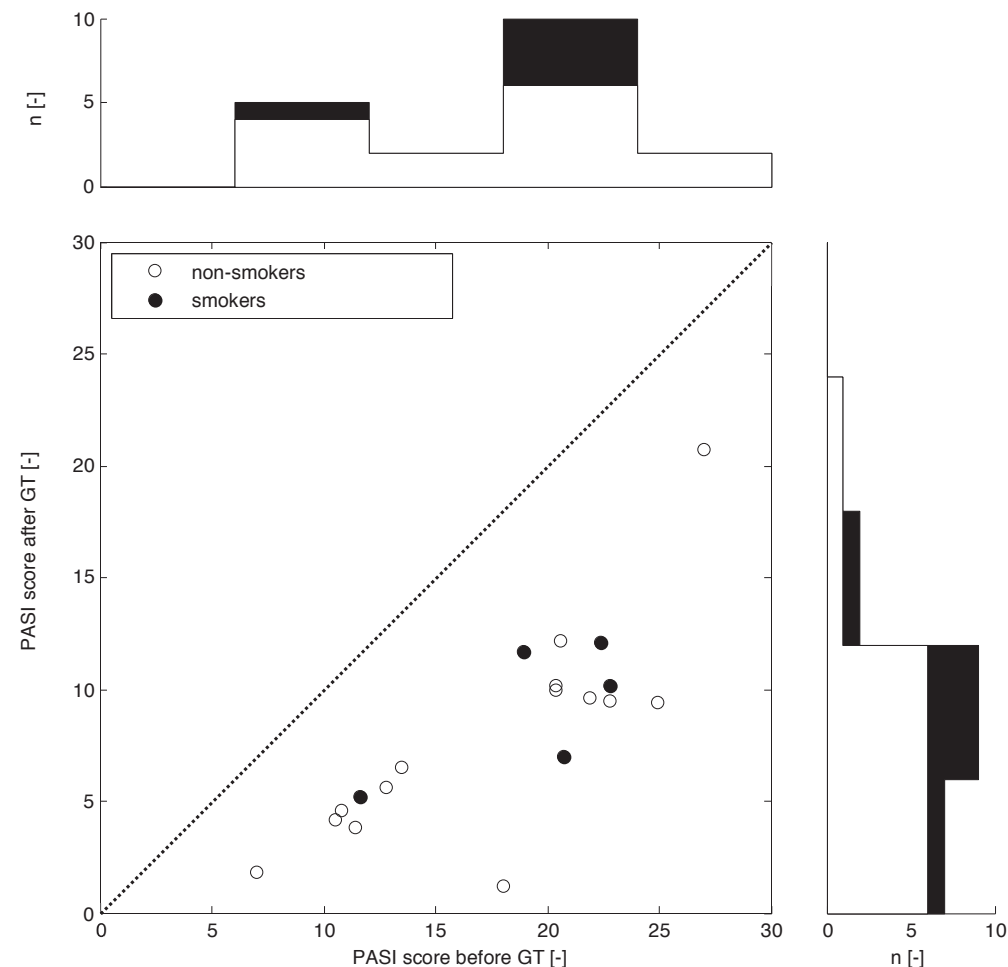


Fig. 1: The levels of PASI score. Legend: The levels are dimensionless. Scatter plot depicts PASI score before and after the GT therapy. Altogether 19 dots represent 38 measurements each dot belongs to one patient. The top histogram shows data distribution before treatment, the right side histogram corresponds to the after treatment values distribution. The white zones represent non-smokers data, and the black zones depict smokers' ones.

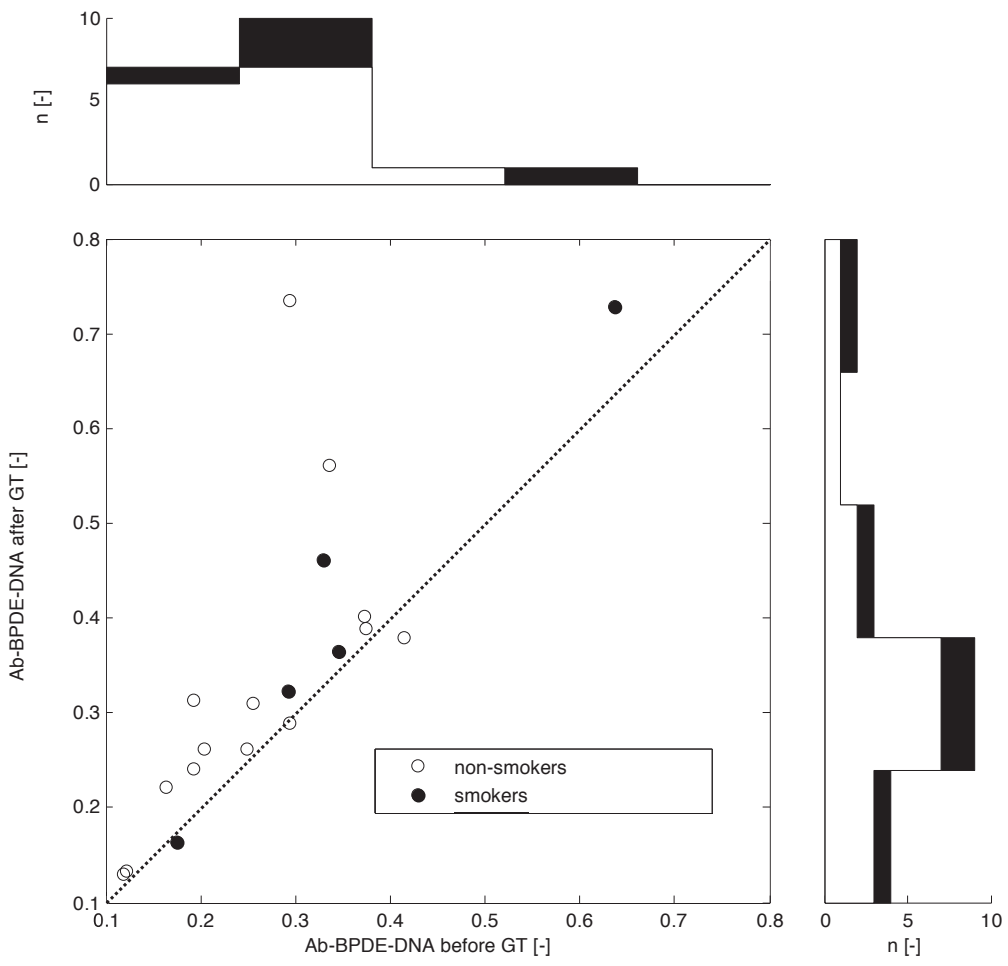


Fig. 2: The levels of Ab-BPDE-DNA. Legend: The levels are dimensionless (EI). Scatter plot depicts Ab-BPDE-DNA before and after the GT therapy. Altogether 19 dots represent 38 measurements, each dot belongs to one patient. The top histogram shows data distribution before treatment, the right side histogram corresponds to the after treatment values distribution. The white zones represent non-smokers data, and the black zones depict smokers' ones.

of smoked cigarettes was overall low, irregular and ranged from one to four cigarettes per “normal” day (outside the hospital). During hospitalization, they almost did not smoke at all. Due to the low number of patients, the group of “smokers” was not statistically evaluable. Therefore, the statistical evaluation was performed only for the whole group of respondents (see below).

The therapy was highly effective because the PASI score significantly decreased (20.4/11.9–22.3 vs. 9.4/4.8–10.2; median/lower–upper quartile; $n = 19$; $p < 0.001$) (Fig. 1).

After the therapy we found significantly increased serum level of Ab-BPDE-DNA (EI = 0.29/0.19–0.34 vs. 0.31/0.25–0.40; median/lower–upper quartile; $n = 19$; $p < 0.01$) (Fig. 2). We did not find a significant relationship between the level of Ab-BPDE-DNA (after GT) and total duration of the therapy ($r = 0.30$), body surface area covered by CCT ointment ($r = 0.02$), total time of UV radiation ($r = 0.09$) and PASI score ($r = 0.21$).

DISCUSSION

Genotoxic effects of chemical and physical factors have been studied largely in adult population, however only a limited number of studies have investigated genotoxic damage in children. It is rather surprising because children represent a population group with high sensitivity to chemical and physical factors. The studies suggest that early exposures during childhood can play an important role in the development of chronic diseases in adulthood: the earlier the exposure, the greater the risk of chronic disease, including cancer (22).

In our previous works, we studied genotoxic and immuno-toxic effects of combined exposure to PAHs and UVR on human organism. Monitored groups consisted of patients (men, women, and children) suffering from psoriasis treated by GT. In the groups of children, we found high degree of dermal absorption of PAHs (elevated levels of urinary 1-hydroxypyrene and hydroxylated phenanthrenes), elevated urinary mutagenicity (Ames test), and increased genotoxicity (chromosomal aberration in peripheral lymphocytes) (8, 10, 11). In addition, we found an elevated level of cellular stress (heat shock proteins; Hsp70) (11), oxidative stress (8-hydroxy-2'-deoxyguanosine, 8-hydroxyguanosine and 8-hydroxyguanine), and BPDE-DNA adducts (8).

In the presented study, the serum level of Ab-BPDE-DNA increased significantly ($p < 0.01$) after the therapy. However, it should be noted that the majority of Ab-BPDE-DNA values (84% of all samples) were found in the zone of low levels (EI < 0.5). Three samples ranged in high values (EI > 0.5), whilst one of them was higher even before the treatment. Similar results were obtained in our previous study focused on the level of Ab-BPDE-DNA in two groups of adult patients with psoriasis, treated by GT (3% and 5% CCT) (8). Other literary data concerning the levels of Ab-BPDE-DNA after therapeutic exposure to CCT are very limited and comparison with these data is complicated because of the use of different methodologies (23).

The term of biological monitoring includes markers of exposure, effect and susceptibility. Circulating Ab-BPDE-DNA signals the presence of genotoxic BPDE-DNA adducts in the organism. It means the level of Ab-BPDE-DNA must be influenced by the same factors as the level of BPDE-DNA adducts, i.e., by the level of exposure to PAHs, by the individual character of BaP metabolism and by the degree of adaptation and reparation processes. In addition, the serum level of Ab-BPDE-DNA also reflects the immune status and a protective capacity of the immune system against BaP induced cancer (18).

The previous paragraphs suggest that the level of circulating Ab-BPDE-DNA could serve as a marker of exposure to PAHs. Elevation of exposure to PAHs increases both the level of BPDE adducts and the related level of Ab-BPDE-DNA.

The BPDE-DNA adducts are assumed to be genotoxic and present a biological response of the organism to genotoxic exposure of PAHs. In this context, the level of Ab-BPDE-DNA can be considered a marker of genotoxic effect (marker of effect).

Finally, the Ab-BPDE-DNA level reflects individual character of metabolism (BaP), condition of adaptation and reparation processes, immune status and protective capacity of the immune system. All of these systems determine the level of individual susceptibility. For this reason, the level of Ab-BPDE-DNA can serve as a tentative marker of individual sensitivity to exposure to BaP.

Application of CCT (PAHs) increases the level of BPDE-DNA adducts and consequently increases the production of Ab-BPDE-DNA. However, PAHs have also an immunosuppressive effect and in this way they can reduce the production of Ab-BPDE-DNA. Therefore, the final level of Ab-BPDE-DNA is probably the result of these opposite processes. It seems likely that repeated or chronic exposure to PAHs (for instance, by occupational atmosphere or by smoking) reduces body immune response and presumably can reduce levels of anti-PAHs antibodies (9, 17). Described mechanisms may be one of the reasons why we found no significant association between the level of Ab-BPDE-DNA and the characteristics of exposure (particularly the duration and the extent of exposure).

We found only few epidemiological studies of PAHs exposed population to assess the impact of carcinogen-specific antibodies on the risk of tumor development and on the relation to other indicators of genotoxic exposure (17, 18, 20). Few attempts have also been made, both in vivo and in vitro, to understand the implications of an antibody response to metabolic activation of carcinogens and carcinogenesis (24, 25). Recent study provided the evidence that specific humoral immunity might modulate the genotoxic effect induced by subsequent carcinogen exposure, however, the mechanisms involved remain largely unexplored (19).

GT is an effective treatment for moderate and severe psoriasis in children (7–12). In this study, the high effectiveness of the therapy was confirmed by a significant decrease of the PASI score.

CONCLUSION

The results of presented study support the idea of Ab-BPDE-DNA level as a possible tentative indicator of exposure, effects and susceptibility of an organism to the exposure of BaP (PAHs).

ACKNOWLEDGEMENTS

Supported by Charles University, Faculty of Medicine in Hradec Králové, Czech Republic, project PROGRES Q40-09, Q40-10. Acknowledgement to Dana Knajflová for text proofreading and linguistics.

CONFLICT OF INTEREST

None declared.

APPROVAL AND INFORMED CONSENT

The study was approved by the Ethics Committee of the University Hospital in Hradec Králové, Czech Republic. Informed written consent was obtained from each patient.

REFERENCES

- Lysell J, Tessma M, Nikamo P, et al. Clinical Characterisation at Onset of Childhood Psoriasis – A Cross Sectional Study in Sweden. *Acta Derm Venereol* 2015; 95: 457–461.
- Matusiewicz D, Koerber A, Schadendorf D, et al. Childhood psoriasis – an analysis of German health insurance data. *Pediatr Dermatol* 2014; 31: 8–13.
- Kim GE, Seidler E, Kimball AB. Effect of Age at Diagnosis on Chronic Quality of Life and Long-Term Outcomes of Individuals with Psoriasis. *Pediatr Dermatol* 2015; 32: 656–662.
- Kakande B, Gumedze F, Hlela C, et al. Focus on the Top Ten Diagnoses Could Reduce Pediatric Dermatology Referrals. *Pediatr Dermatol* 2016; 33: 99–102.
- Sram RJ, Binkova B, Dostal M, et al. Health impact of air pollution to children. *Int J Hyg Environ Health* 2013; 216: 533–540.
- Neri M, Ugolini D, Bonassi S, et al. Children's exposure to environmental pollutants and biomarkers of genetic damage. II. Results of a comprehensive literature search and meta-analysis. *Mutat Res* 2006; 612: 14–39.
- Kortuem KR, Davis MD, Witman PM, et al. Results of Goeckerman treatment for psoriasis in children: a 21-year retrospective review. *Pediatr Dermatol* 2010; 27: 518–524.
- Borska L, Andrys C, Krejsek J, et al. Oxidative Damage to Nucleic Acids and Benzo(a)pyrene-7,8-diol-9,10-epoxide-DNA Adducts and Chromosomal Aberration in Children with Psoriasis Repeatedly Exposed to Crude Coal Tar Ointment and UV Radiation. *Oxid Med Cell Longev* 2014; ID302528: 1–10a.
- Borska L, Andrys C, Krejsek J, et al. Serum level of antibody against benzo[a]pyrene-7,8-diol-9,10-epoxide-DNA adducts in people dermally exposed to PAHs. *J Immunol Res* 2014; ID834389: 1–6b.
- Borska L, Smejkalova J, Cerna M, et al. Urinary mutagenicity and genotoxic risk in children with psoriasis after therapeutic exposure to polycyclic aromatic hydrocarbons and ultraviolet radiation. *Mutat Res* 2010; 696: 144–147.
- Borska L, Andrys C, Krejsek J, et al. Genotoxic hazard and cellular stress in pediatric patients treated for psoriasis with the Goeckerman regimen. *Pediatr Dermatol* 2009; 26: 23–27.
- Borska L, Fiala Z, Krejsek J, et al. Immunologic changes in TNF-alpha, sE-selectin, sP-selectin, sICAM-1, and IL-8 in pediatric patients treated for psoriasis with the Goeckerman regimen. *Pediatr Dermatol* 2007; 24: 607–612.
- Paghdal KV, Schwartz RA. Topical tar: back to the future. *J Am Acad Dermatol* 2009; 61: 294–302.
- Roelofzen JH, Aben KK, Van de Kerkhof PC, et al. Dermatological exposure to coal tar and bladder cancer risk: A case-control study. *Urol Oncol* 2015; 33: 19–22.
- Roelofzen JH, van der Valk PG, Godschalk R, et al. DNA adducts in skin biopsies and 1-hydroxypyrene in urine of psoriasis patients and healthy volunteers following treatment with coal tar. *Toxicol Lett* 2012; 213: 39–44.
- Lee BK, Chung MY, Lee KW. Benzo[a]pyrene-7,8-diol-9,10-epoxide inhibits gap junction intercellular communication via phosphorylation of tumor progression locus 2 in WB-F344 rat liver epithelial cells. *Mol Carcinog* 2015; 54: 351–358.
- Pauk N, Klimesova S, Kara J, et al. The relevance of monitoring of antibodies against the polycyclic aromatic hydrocarbon (PAH) and PAH-DNA adducts in serum in relation to lung cancer and chronic obstructive pulmonary disease (COPD). *Neoplasma* 2013; 60: 182–187.
- Petruzzelli S, Celi A, Pulerà N, et al. Serum antibodies to benzo(a)pyrene diol epoxide-DNA adducts in the general population: effects of air pollution, tobacco smoking, and family history of lung diseases. *Cancer Res* 1998; 58: 4122–4126.
- Pavanello S, Dioni L, Hoxha M, et al. Mitochondrial DNA copy number and exposure to polycyclic aromatic hydrocarbons. *Cancer Epidemiol Biomarkers Prev* 2013; 22: 1722–1729.
- Galati R, Zijno A, Crebelli R, et al. Detection of antibodies to the benzo(a)pyrene diol epoxide-DNA adducts in sera from individuals exposed to low doses of polycyclic aromatic hydrocarbons. *J Exp Clin Cancer Res* 2001; 20: 359–364.
- Chow C, Simpson MJ, Luger TA, et al. Chubb H, Ellis CN. Comparison of three methods for measuring psoriasis severity in clinical studies (Part 1 of 2): change during therapy in Psoriasis Area and Severity Index, Static Physician's Global Assessment and Lattice System Physician's Global Assessment. *J Eur Acad Dermatol Venereol* 2015; 29: 1406–1414.
- Feretti D, Ceretti E, De Donno A, et al. Monitoring air pollution effects on children for supporting public health policy: the protocol of the prospective cohort MAPEC study. *BMJ Open* 2014; 4: e006096.
- Santella RM, Perera FP, Young TL, et al. Polycyclic aromatic hydrocarbon-DNA and protein adducts in coal tar treated patients and controls and their relationship to glutathione S-transferase genotype. *Mutat Res* 1995; 334: 117–124.
- Saladi R, Austin L, Gao D, et al. The combination of benzo[a]pyrene and ultraviolet A causes an in vivo time-related accumulation of DNA damage in mouse skin. *Photochem Photobiol* 2003; 77: 413–419.
- Wani MA, El-Mahdy MA, Hamada FM, et al. Efficient repair of bulky anti-BPDE DNA adducts from non-transcribed DNA strand requires functional p53 but not p21(waf1/cip1) and pRb. *Mutat Res* 2002; 505: 13–25.

Investigation of P120catenin Expression in Human Basal Cell Carcinoma of the Skin

Vladimír Bartoš^{1,*}, Milada Kullová²

ABSTRACT

Background: P120(ctn) is a specific membranous adhesion protein, that maintains the stability of intercellular junctions. An altered expression of p120(ctn), either reduced in the cell membrane or increase in the cytoplasm, plays a crucial role in carcinogenesis. No research has analysed the expression of p120(ctn) in basal cell carcinoma (BCC) of the skin so far. Therefore, we immunohistochemically studied p120(ctn) in a set of cutaneous BCCs in order to determine, whether there is difference in the expression pattern related to the histologic subtypes and tumor growth characteristics. Material and Methods: The study group consisted of 38 BCCs categorized into low-risk (non-infiltrative) subgroup (8 superficial and 12 nodular subtypes) and high-risk (infiltrative) subgroup (10 nodular-infiltrative and 8 infiltrative subtypes). Specific monoclonal antibody against p120(ctn) was used for staining. Results: Overall, there were 12 cases (31.6%) with normal preserved and 26 cases (68.4%) with abnormal p120(ctn) expression. In superficial, nodular, nodular-infiltrative and infiltrative subtypes, abnormal p120(ctn) immunoreactivity was found in 37.5% (3/8), 41.7% (5/12), 100% (10/10) and 100% (8/8), respectively. We have confirmed a strong correlation between the expression of p120(ctn) and both given, non-infiltrative and infiltrative BCC growth phenotypes. In the latter subgroup, almost all lesions showed diffusely reduced membranous staining, of which five also manifested an aberrant immunoreactivity in the cytoplasm. This cytoplasmic positivity occurred solely at the invasive front of the infiltrative tumor formations. Conclusion: Our results showed that decreased membranous expression of p120(ctn) was a frequent event in human cutaneous BCC and it was associated with infiltrative growth phenotype. Considering that nearly half of the BCCs with non-infiltrative growth pattern also exhibited reduced membranous expression, aberrant cytoplasmic immunoreactivity of p120(ctn), which was found exclusively in the high-risk BCC variants, can more reliably reflect and predict biological behaviour and malignant potential.

KEYWORDS

basal cell carcinoma; biological behaviour; P120catenin

AUTHOR AFFILIATIONS

¹ Department of Pathology, Faculty Hospital in Žilina, V. Spanyola 43, Žilina, 012 07, Slovakia

² Department of Dermatovenerology, Faculty Hospital in Žilina, V. Spanyola 43, Žilina, Slovakia

* Corresponding author: Björnsonova 3/5, Martin, 036 01; Slovakia; e-mail: vladim.bartos@gmail.com

Received: 28 December 2016

Accepted: 23 March 2017

Published online: 7 June 2017

Acta Medica (Hradec Králové) 2017; 60(1): 32–36

<https://doi.org/10.14712/18059694.2017.48>

© 2017 The Authors. This is an open-access article distributed under the terms of the Creative Commons Attribution License (<http://creativecommons.org/licenses/by/4.0>), which permits unrestricted use, distribution, and reproduction in any medium, provided the original author and source are credited.

INTRODUCTION

p120catenin (p120(ctn)) is a specific cell-cell adhesion protein with multiple roles in different cellular compartments. It is functionally linked to a wide variety of oncogenes and tumor suppressors, such as Src kinases, receptor tyrosine kinases and phosphatases, E-cadherin, β -catenin, RhoGTPases, Kaiso, and Wnt signaling effectors (1). A major role of p120(ctn) is to serve as a cadherin “gatekeeper”. Under normal conditions, p120(ctn) is expressed in the cell membrane and binds directly to the juxtamembrane domain of E-cadherin. This stabilizes cadherin and maintains the stability of intercellular adhesions (1). In contrast, when p120(ctn) is phosphorylated, it is dissociated from the cadherin tail, leading to cadherin internalization and consequently, the weakening of the cell-cell junctions. As a result, p120(ctn) expression is reduced in the cell membrane and increased in the cytoplasm. Therefore, the subcellular distribution of p120(ctn) significantly modulate adhesion status of the cells and plays an important role in the carcinogenesis (1). There is accumulating evidence that altered expression of p120(ctn) is related to tumor invasion and metastasis and its expression pattern correlates with cancer prognosis. Until now, aberrant p120(ctn) expression has been reported as a potential prognostic indicator in many human malignancies, such as gastroesophageal adenocarcinoma (2), breast cancer (3), urinary bladder cancer (4), lung cancer (5), esophageal carcinoma (6), oral squamous cell carcinoma (7), colonic cancer (8), prostatic cancer (9), cholangiocellular carcinoma (10), hepatocellular carcinoma (11), and cutaneous squamous cell carcinoma (12). To the best of our knowledge, no research has analysed the expression of p120(ctn) in basal cell carcinoma (BCC) of the skin despite the fact, it is currently the most common malignancy in humans. Therefore, the present study focused on the expression pattern of p120(ctn) in the series of cutaneous BCCs using immunohistochemistry. The main goal was to explain, whether there is difference in the expression patterns related to the histologic subtypes and tumor growth characteristics.

MATERIAL AND METHODS

CLINICAL DATA AND TUMOR SPECIMENS

Biopsy samples from 38 chosen cases of cutaneous BCCs from various topographic sites were enrolled into this study. They were obtained from 33 patients (13 males, 20 females) in the age range of 49–94 years (mean age 74.9 y.), who have been treated at the clinical departments of the Faculty Hospital in Žilina (Slovakia) and all biopsy specimens were histopathologically investigated at the Department of Pathology in Faculty Hospital in Žilina. For the purpose of this study, we selected a set of representative samples of cutaneous BCCs included four histomorphological subtypes: superficial (8 cases), nodular (12 cases), mixed nodular-infiltrative (10 cases), and infiltrative (8 cases). Further, according to the previous reports (13, 14) and recommendations proposed recently by The Royal College of Pathologists (15), they were divided into two separate subgroups for statistical analysis. The first sub-

group comprised 20 low-risk (non-infiltrative) BCC subtypes (superficial and nodular). The second subgroup comprised 18 high-risk BCCs with (at least focal) infiltrative growth pattern (mixed nodular-infiltrative and infiltrative subtypes).

IMMUNOHISTOCHEMISTRY

Biopsy samples were routinely processed and immunohistochemically stained for calponin according to manufacturer's instructions. Shortly, representative 4- μ m tissue sections applied on silanized slides were baked for 2 hours in an oven at 56 °C. Then the sections were deparaffinized in xylene, rehydrated in series of descending ethanol concentrations and treated with microwaves in Dako Target Retrieval Solution (0.01 M citrate buffer, pH 6.0) for 20 minutes. The endogenous peroxidase activity was blocked with 3% hydrogen peroxide. Subsequently, specific monoclonal mouse antibody against p120catenin (clone MRQ-5, DAKO, dilution 1:25) was used for staining. After incubation at ambient temperature, post primary antibody was applied and an immunoreaction was visualised by means of the DAB (3,3'-diaminobenzidine) detection chromogen solution. Slides were counterstained with Mayer's hematoxylin, dehydrated, mounted and finally evaluated in the light microscope. Positive reaction on epithelium of eccrine glands served as internal control.

DATA INTERPRETATION AND STATISTICAL ANALYSIS

Based on the previous paper published by Wang et al. (5), we semiquantitatively classified tumors into 3 categories, according to the proportion of cancer cells that were immunoreactive for p120(ctn). When $\geq 90\%$ of the cancer cells stained in the cell membrane, the case was defined as normal membranous expression. When $< 90\%$ of the cancer cells stained for membranous expression, the case was defined as reduced membranous expression. Further, when $\geq 10\%$ of the cancer cells apparently stained within the cytoplasm, the case was defined as aberrant cytoplasmic expression. Both, reduced membranous and aberrant cytoplasmic expression (either alone or simultaneous within a single lesion) was considered abnormal. Data were collected in a databank, using a software SPSS Statistics. For the statistical analysis, chi-square test was employed and P value < 0.05 was considered to indicate statistical significance.

RESULTS

In our series, p120(ctn) was expressed in 36 tumor samples with variable quantitative range and intensity. Two BCCs (one nodular and one nodular-infiltrative subtype) showed a completely negative staining. Overall, there were 12 cases (31.6%) with normal preserved and 26 cases (68.4%) with abnormal (including two lesions with negative) p120(ctn) expression. In the latter subgroup, almost all lesions showed diffusely reduced membranous staining, of which five (all of them comprising infiltrative growth pattern) also manifested an aberrant immunoreactivity in the cytoplasm. This cytoplasmic positivity was

only focal, however, it occurred exclusively at the invasive front of tumor nests. No nuclear immunoreactivity was detected. Immunohistochemical status of p120(ctn) expression seemed to be related to histopathological BCC subtypes. In superficial, nodular, nodular-infiltrative and infiltrative subtypes, abnormal p120(ctn) immunoreactivity was found in 37.5% (3/8), 41.7% (5/12), 100% (10/10) and 100% (8/8), respectively. We have confirmed a strong correlation between the expression of p120(ctn) and both

given, low-risk and high-risk BCC subgroup ($p = 0.001$). While non-infiltrative histologic subtypes of BCC manifested a normal preserved expression in the majority of the cases (60%, 12/20) (Figure 1 and 2), all BCCs with infiltrative growth features (100%, 18/18) showed abnormal type of p120(ctn) expression, including a strong cytoplasmic immunoreactivity (Figure 3 and 4). A summary of the immunohistochemical findings in our set of BCCs investigated is presented in Table 1.

Tab. 1: A summary of the immunohistochemical findings in the set of 38 BCCs we investigated (* including a case with completely negative staining).

BCC subtype	N	Membranous expression of p120catenin	Aberrant cytoplasmic expression of p120catenin
superficial	8	normal 5 (62.5%) reduced 3 (37.5%)	no 8 (100%) present 0 (0%)
nodular	12	normal 7 (58.3%) reduced* 5 (41.7%)	no 12 (100%) present 0 (0%)
nodular-infiltrative	10	normal 0 (0%) reduced* 10 (100%)	no 8 (80.0%) present 2 (20.0%)
infiltrative	8	normal 0 (0%) reduced 8 (100%)	no 5 (62.5%) present 3 (37.5%)

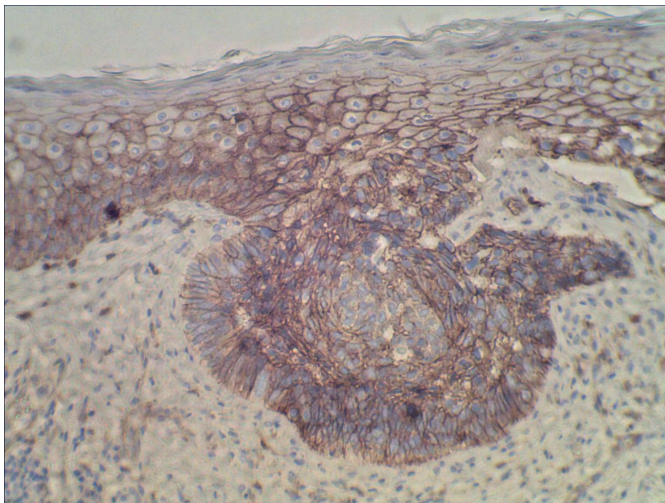


Fig. 1: Preserved diffuse membranous expression of p120(ctn) in superficial BCC (original magnification 200 \times).

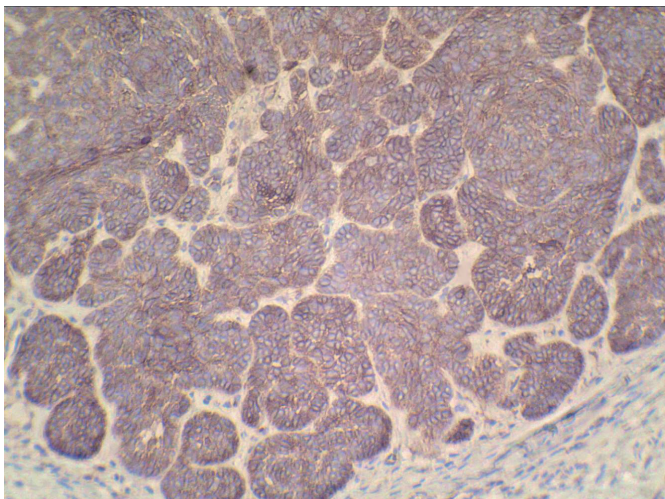


Fig. 2: Preserved diffuse membranous expression of p120(ctn) in nodular BCC (original magnification 100 \times).

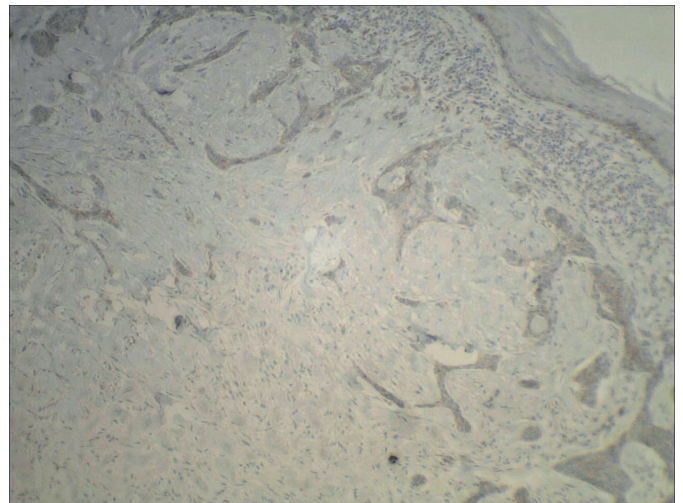


Fig. 3: Virtually completely absent expression of p120(ctn) in infiltrative BCC (original magnification 40 \times).

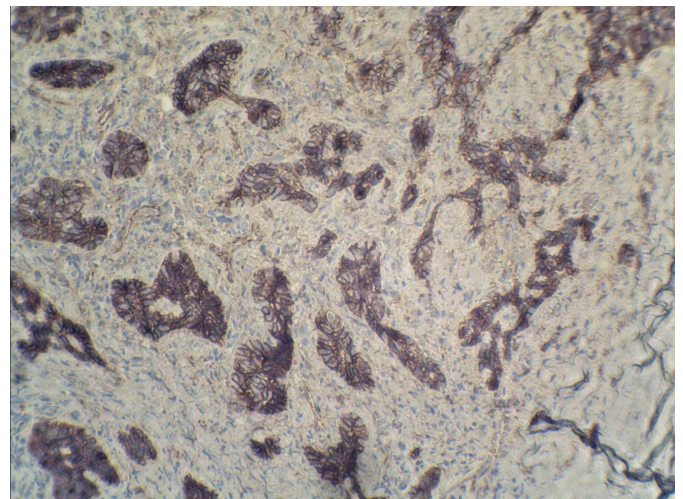


Fig. 4: Strong cytoplasmic expression of p120(ctn) within the tumor cells in infiltrative BCC. Some cells also show a concomitant immunoreactivity in the cell membrane (original magnification 200 \times).

DISCUSSION

BCC of the skin is histomorphologically and phenotypically very heterogeneous oncological entity. It possess some unique features, such as slow local growth, strong stroma-dependency, and virtual absence of metastases (16, 17). Although it generally pursues a favourable clinical course, some cases show an aggressive behaviour, rapidly infiltrating deeper tissue structure and leading to treatment difficulties with local recurrences (16, 17). Many various molecular markers have been studied in cutaneous BCC until now (17), however, it is still not clearly understood, which of them are directly responsible for aggressive tumor behaviour and conversely, which potentially prevent cancer cells to metastasize.

This paper describes immunohistochemical expression status of cell-cell adhesion molecule p120(ctn) in a panel of 38 human BCCs of the skin. We have found that more than two thirds of the cases were accompanied by abnormal p120(ctn) expression. Therefore, a loss of normal membranous p120(ctn) expression is very frequent histopathological finding in cutaneous BCC. Of note, it has been found to be associated with infiltrative tumor growth. Our results are similar to those reported for other cancers (2–12, 18, 19) which suggests that the decrease or loss of p120(ctn) in the cell membrane plays a crucial role in tumorigenesis and a rising malignant potential. Interestingly, only a few cases concurrently exhibited an aberrant strong cytoplasmic immunoreactivity. This somewhat contradicts with many previous studies (4, 5, 8, 12, 20–22) which have shown that the transition of p120(ctn) from the cell membrane to the cytoplasm (or even into the nuclei) in various malignancies is associated with potentially invasive phenotype and disease progression and it might be more relevant prognostic indicator. In our study, among 26 BCCs with reduced or lost membranous immunostaining, only 5 lesions manifested apparent cytoplasmic accumulation of p120(ctn), which was not very extensive. Although this feature seemed to be link with infiltrative growth character of BCC, due to small number of such cases we did not evaluate a statistical significance. Since as far as we know, this is the first study addressing immunohistochemical investigation of p120(ctn) in cutaneous BCC, we had no opportunity to compare our results with another observations. At this point, it seems likely that an invasive growth of BCC is accompanied by loss of membranous p120(ctn) expression, however, usually without concomitant accumulation in the cytoplasm. This may be a special molecular feature of this human malignancy. A similar situation is known, for example, in the breast tumors, in which the lesions of ductal and lobular origin exhibit distinct expression patterns of p120(ctn). While the lobular neoplasms show a markedly increased cytoplasmic immunoreactivity without discernible cell membrane staining, ductal neoplasias show reduced membrane expression without appreciable cytoplasmic accumulation (18, 19).

In conclusion, our study showed that decreased membranous expression of p120(ctn) was a frequent event in human cutaneous BCC and it was associated with infiltrative growth phenotype. Further, aberrant cytoplasmic immunoreactivity occurred only in a few cases, but

it was found exclusively in the high-risk BCC variants at the invasive front of the infiltrative tumor formations. Considering that nearly half of the BCCs with non-infiltrative growth pattern also exhibited reduced membranous expression of p120(ctn), cytoplasmic positivity can more reliably reflect and predict biological behaviour and malignant potential. Further investigations are needed to elucidate the mechanism and role of p120(ctn) in BCC biology and our present study may provide the basis for them.

ACKNOWLEDGEMENTS

The authors would like to thank Dr. Daniela Melova for her outstanding educational and technical assistance.

REFERENCES

- Schackmann RC, Tenhagen M, van de Ven RA, Derksen PW. p120-catenin in cancer - mechanisms, models and opportunities for intervention. *J Cell Sci* 2013; 126: 3515–25.
- Wijnhoven BP, Pignatelli M, Dinjens WN, Tilanus HW. Reduced p120ctn expression correlates with poor survival in patients with adenocarcinoma of the gastroesophageal junction. *J Surg Oncol* 2005; 92: 116–23.
- Talvinen K, Tuikkala J, Nykänen M, et al. Altered expression of p120catenin predicts poor outcome in invasive breast cancer. Altered expression of p120catenin predicts poor outcome in invasive breast cancer. *J Cancer Res Clin Oncol* 2010; 136: 1377–87.
- Silva Neto B, Smith GL, Mandeville JA, et al. Prognostic significance of altered p120ctn expression in bladder cancer. *BJU Int* 2008; 101: 746–52.
- Wang EH, Liu Y, Xu HT, et al. Abnormal expression and clinicopathologic significance of p120-catenin in lung cancer. *Histol Histopathol* 2006; 21: 841–7.
- Chen T, Wang C, Wu F, et al. Altered localization of p120 catenin in the cytoplasm rather than the membrane correlates with poor prognosis in esophageal squamous cell carcinoma. *PLoS One* 2015; 10: e0118645. doi: 10.1371/journal.pone.0118645.
- Jiang Y, Liao L, Shrestha C, et al. Reduced expression of E-cadherin and p120-catenin and elevated expression of PLC- γ 1 and PIKE are associated with aggressiveness of oral squamous cell carcinoma. *Int J Clin Exp Pathol* 2015; 8: 9042–51.
- Bellovin DI, Bates RC, Muzikansky A, Rimm DL, Mercurio AM. Altered localization of p120 catenin during epithelial to mesenchymal transition of colon carcinoma is prognostic for aggressive disease. *Cancer Res* 2005; 65: 10938–45.
- Van Oort IM, Tomita K, van Bokhoven A, et al. The prognostic value of E-cadherin and the cadherin-associated molecules alpha-, beta-, gamma-catenin and p120ctn in prostate cancer specific survival: a long-term follow-up study. *Prostate* 2007; 67: 1432–8.
- Zhai B, Yan HX, Liu SQ, et al. Reduced expression of p120 catenin in cholangiocarcinoma correlated with tumor clinicopathologic parameters. *World J Gastroenterol* 2008a; 14: 3739–44.
- Zhai B, Yan HX, Liu SQ, et al. Reduced expression of E-cadherin/catenins complex in hepatocellular carcinomas. *World J Gastroenterol* 2008b; 14: 5665–73.
- Ishizaki Y, Omori Y, Momiyama M, et al. Reduced expression and aberrant localization of p120catenin in human squamous cell carcinoma of the skin. *J Dermatol Sci* 2004; 34: 99–108.
- Nedved D, Tonkovic-Capin V, Hunt E, et al. Diagnostic concordance rates in the subtyping of basal cell carcinoma by different dermatopathologists. *J Cutan Pathol* 2014; 41: 9–13.
- Bartoš V, Kullová M. Basal cell carcinoma of the skin with mixed histomorphology: a comparative study. *Cesk Patol* 2016; 52: 222–6.
- Slater D, Walsh M. Standards and dataset for reporting cancers. Dataset for the histological reporting of primary cutaneous basal cell carcinoma. The Royal College of Pathologists. 3rd ed., May 2014. 29 pages.
- Crowson AN. Basal cell carcinoma: biology, morphology and clinical implications. *Mod. Pathol* 2006; 19(Suppl 2): S127–S147.
- Bartoš V, Adamicová K, Kullová M, Pěč M. Basal cell carcinoma of the skin - biological behaviour of the tumor and a review of the most important molecular predictors of disease progression in pathological practice. *Klin Onkol* 2011; 24: 8–17. (in Slovak)

18. Dabbs DJ, Bhargava R, Chivukula M. Lobular versus ductal breast neoplasms: the diagnostic utility of p120 catenin. *Am J Surg Pathol* 2007; 31: 427-37.
19. Sarrió D, Pérez-Mies B, Hardisson D, et al. Cytoplasmic localization of p120^{ctn} and E-cadherin loss characterize lobular breast carcinoma from preinvasive to metastatic lesions. *Oncogene* 2004; 23: 3272-83.
20. Lo Muzio L, Pannone G, Staibano S, et al. p120^(cat) Delocalization in cell lines of oral cancer. *Oral Oncol* 2002; 38: 64-72.
21. Mayerle J, Friess H, Büchler MW, et al. Up-regulation, nuclear import, and tumor growth stimulation of the adhesion protein p120 in pancreatic cancer. *Gastroenterology* 2003; 124: 949-60.
22. Shibata T, Kokubu A, Sekine S, Kanai Y, Hirohashi S. Cytoplasmic p120^{ctn} regulates the invasive phenotypes of E-cadherin deficient breast cancer. *Am J Pathol* 2004; 164: 2269-78.

The Evaluation of Benefit of Newly Prepared Reversible Inhibitors of Acetylcholinesterase and Commonly Used Pyridostigmine as Pharmacological Pretreatment of Soman-Poisoned Mice

Jiří Kassa*, Jan Korábečný, Eugenie Nepovimová

ABSTRACT

Aim: The ability of four newly prepared reversible inhibitors of acetylcholinesterase (6-chlorotacrine, 7-phenoxytacrine, compounds 1 and 2) and currently used carbamate pyridostigmine to increase the resistance of mice against soman and the efficacy of antidotal treatment of soman-poisoned mice was evaluated. **Methods:** The evaluation of the effect of pharmacological pretreatment is based on the identification of changes of soman-induced toxicity that was evaluated by the assessment of its LD₅₀ value and its 95% confidence limit using probit-logarithmical analysis of death occurring within 24 h after administration of soman. **Results:** 6-chlorotacrine was only able to markedly protect mice against acute toxicity of soman. In addition, the pharmacological pretreatment with 6-chlorotacrine or compound 2 was able to increase the efficacy of antidotal treatment (the oxime HI-6 in combination with atropine) of soman-poisoned mice. The other newly prepared reversible inhibitors of acetylcholinesterase (7-phenoxytacrine, compound 1) as well as commonly used pyridostigmine did not influence the efficacy of antidotal treatment. **Conclusion:** These findings demonstrate that pharmacological pretreatment of soman-poisoned mice can be promising and useful in the case of administration of 6-chlorotacrine and partly compound 2.

KEYWORDS

soman; reversible inhibitors of acetylcholinesterase; antidotes; pharmacological pretreatment; mice

AUTHOR AFFILIATIONS

Department of Toxicology and Military Pharmacy, University of Defence, Faculty of Military Health Sciences, Hradec Králové, Czech Republic

* Corresponding author: Třebešská 1575, Faculty of Military Health Sciences, 500 01 Hradec Králové, Czech Republic; e-mail: kassa@pmfhk.cz

Received: 17 January 2017

Accepted: 9 March 2017

Published online: 18 April 2017

Acta Medica (Hradec Králové) 2017; 60(1): 37–43

<https://doi.org/10.14712/18059694.2017.45>

© 2017 The Authors. This is an open-access article distributed under the terms of the Creative Commons Attribution License (<http://creativecommons.org/licenses/by/4.0>), which permits unrestricted use, distribution, and reproduction in any medium, provided the original author and source are credited.

INTRODUCTION

The highly toxic organophosphorus compounds, called nerve agents, are still considered to be the most dangerous chemical warfare agents. They pose potential threats to both military and civilian populations, as evidenced in terroristic attacks in Japan (1). Organophosphorus nerve agents exert their toxic effects mainly by inhibiting acetylcholinesterase (AChE, EC 3.1.1.7) and subsequent accumulation of acetylcholine (ACh) in the central and peripheral nervous systems and stimulation of both muscarinic and nicotinic cholinergic receptors. Death occurs due to an acute cholinergic crisis, with signs and symptoms such as excessive salivation, lacrimation, urination, defecation, sweating, bronchoconstriction, neuromuscular block, generalized seizures, respiratory distress and respiratory failure (2–3).

The current standard treatment for poisoning by nerve agents consists of the combined administration of anticholinergic drugs such as atropine sulfate and AChE reactivators such as pralidoxime, obidoxime or HI-6. Generally, anticholinergics (mainly atropine) are used for relieving muscarinic signs and symptoms whereas AChE reactivators (generally nucleophilic compounds with high affinity for phosphorus), also called oximes, are used to repair the biochemical lesion by dephosphorylation of AChE and restoring its activity. Although the antidotes against nerve agents and organophosphorus insecticides have been developed based on the knowledge of above-mentioned basic mechanism of acute toxicity, their efficacy is limited (4–5).

One of the most resistant nerve agents is soman (pinacolyl methylfluorophosphonate). Its deleterious effects are extraordinarily difficult to counteract due to the very rapid aging of soman-inhibited AChE (2, 6). In addition, the main action of soman is in the central nervous system where the reactivating efficacy of all oximes is low owing to their limited penetration through blood-brain barrier (7–8). The unsatisfactory antidotal treatment available for acute nerve agent poisonings, especially in the case of soman, cyclosarin and tabun exposure, has brought another approach how to protect the humans from nerve agent-induced acute lethal toxic effects – using “pharmacological pretreatment” in the case the threat of exposure to nerve agents occurs. This approach generally represents the medical countermeasures applied relatively shortly before the penetration of a toxic agent into the organism with the aim of protecting the organism against the toxic drug and increasing the effects of post-exposure antidotal treatment. It appears from toxicodynamic point of view that prophylactic countermeasures can bring two main actions: protection of AChE against irreversible inhibition and antagonisation of the action of accumulated ACh. Thus, the pharmacological pretreatment allows survival and increase the resistance of organisms exposed to nerve agents as previously described (9–11).

Up to date, the most common principle of pharmacological pretreatment is the protection of AChE against nerve agent-induced irreversible inhibition that is focused on the use of reversible cholinesterase inhibitors. Among reversible inhibitors of AChE, the carbamate pyridostig-

mine bromide is generally accepted and commonly used for the pharmacological pretreatment of nerve agent poisonings. However, pyridostigmine is only able to protect peripheral AChE from irreversible nerve agent-induced AChE phosphorylation, while nerve agents, especially fluorophosphonates, can cross the blood-brain barrier (BBB) and, thus, express their deleterious effects through their central toxic effects including centrally mediated seizure activity that can rapidly progress to *status epilepticus* and finally contribute to brain damage (2).

Thus, the replacement of pyridostigmine bromide with sufficiently effective reversible inhibitors of AChE with low toxicity and ability to cross the blood-brain barrier has been an important goal for the pharmacological pretreatment of nerve agent poisonings because the small decrease of the brain AChE activity (up to 20%) was found to be beneficial for an increase in the efficacy of pharmacological pretreatment and does not affect the behavioral and neurophysiological functions of experimental animals according to our neurobehavioral research (12). Recently, four novel reversible inhibitors of AChE – 6-chlorotacrine (6-chloro-1,2,3,4-tetrahydroacridine-9-amine hydrochloride), 7-phenoxytacrine (7-phenoxy-1,2,3,4-tetrahydroacridine-9-amine hydrochloride), compound 1 (6-hydrazil-N-{6-[(7-methoxy-1,2,3,4-tetrahydroacridine-9-yl)amino]hexyl}pyridine-3-carboxamide hydrochloride) and compound 2 (6-hydrazil-N-{6-[(1,2,3,4-tetrahydroacridine-9-yl)amino]hexyl}pyridine-3-carboxamide hydrochloride) (Figure 1) were synthesized at our Department of Toxicology and Military Pharmacy to improve the efficacy of pharmacological pretreatment against nerve agents and potentially for the treatment of Alzheimer's disease. All newly prepared reversible inhibitors of AChE are tacrine-related compounds. Tacrine itself failed as a prophylactic agent because of small difference between pharmacologically effective and toxic doses. Therefore, we were searching for tacrine-related compounds with bigger differences between therapeutic and toxic doses.

In the present study, the influence of pyridostigmine and four newly prepared reversible inhibitors of AChE (6-chlorotacrine, 7-phenoxytacrine, compounds 1 and 2) on the resistance of soman-exposed mice and on the therapeutic efficacy of currently used antidotal treatment (the oxime HI-6 in combination with atropine) of soman-induced acute poisoning was compared.

MATERIALS AND METHODS

ANIMALS

Male NMRI mice weighing 18–22 g were purchased from VELAZ (Prague, Czech Republic). They were kept in an air-conditioned room (22 ± 2 °C and $50 \pm 10\%$ relative humidity, with lights from 7.00 hrs a.m. to 7.00 hrs p.m.) and allowed access to standard food and tap water *ad libitum*. The rats were divided into groups of eight animals ($N = 8$). Handling of experimental animals was done under the supervision of the Ethics Committee of the Faculty of Military Health Sciences in Hradec Králové (Czech Republic).

CHEMICALS

Soman was obtained from the Military Technical Institute in Brno (Czech Republic) and was 95.0% pure. Its purity was assayed by acidimetric titration. The purity of all reversible inhibitors of AChE (Figure 1) was higher than 98%. They were synthesized earlier at the Department of Toxicology and Military Pharmacy of the Faculty of Military Health Sciences in Hradec Kralove (Czech Republic)

with the exception of pyridostigmine bromide that was purchased from LITOLAB (Chudobin, Czech Republic). The purity of newly synthesized reversible inhibitors of AChE was analysed using HPLC. All other drugs and chemicals of analytical grade were obtained commercially and used without further purification. All substances were administered intramuscularly (i.m.) at a volume of 10 mL/kg body weight (b.w.).

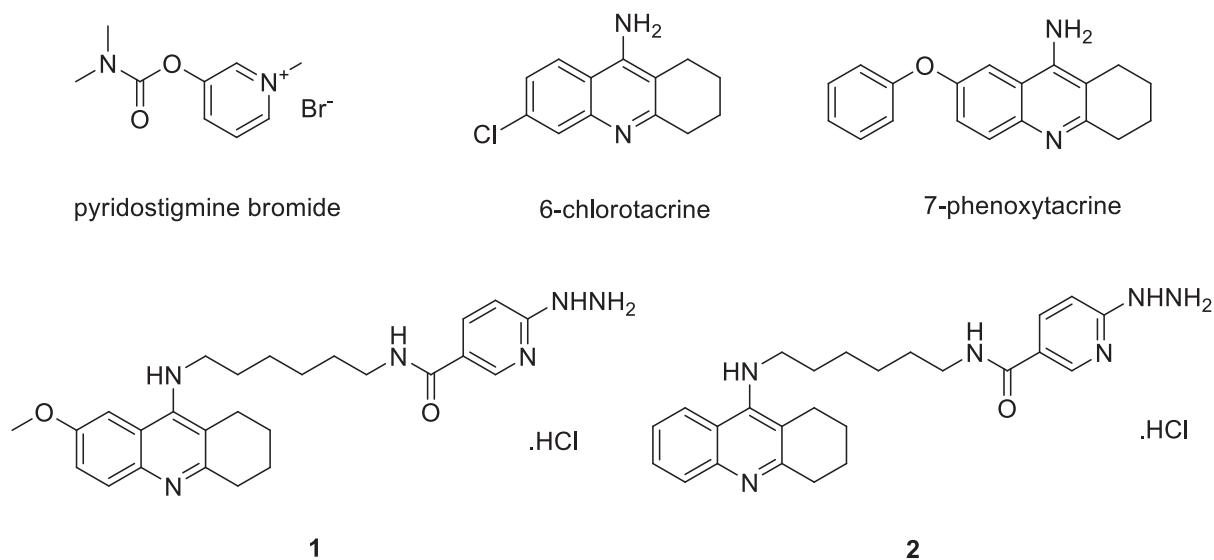


Fig. 1: Chemical structure of reversible inhibitors of AChE studied.

EVALUATION OF ACUTE TOXICITY OF REVERSIBLE INHIBITORS OF AChE

Before starting the evaluation of prophylactic efficacy of AChE reversible inhibitors, the acute toxicity of all tested inhibitors was evaluated in mice by the assessment of their LD_{50} values and their 95% confidence limits (CL) using probit-logarithmical analysis of death occurring within 24 hours after i.m. administration of each inhibitor at five different doses with eight animals per dose (13).

EVALUATION OF PROPHYLACTIC EFFICACY OF REVERSIBLE INHIBITORS OF AChE

To evaluate prophylactic efficacy of tested reversible inhibitors of AChE, the inhibitors (pyridostigmine, 6-chlorotacrine, 7-phenoxytacrine, compounds 1 and 2) were administered i.m. at doses corresponding to 5% of their LD_{50} values 30 minutes before i.m. soman challenge. The doses of tested reversible inhibitors of AChE were chosen to be sufficiently safe to avoid the potential adverse drug reactions in the peripheral as well as central compartment. Soman-induced toxicity was evaluated by the assessment of its LD_{50} value and its 95% confidence limit using probit-logarithmical analysis of death occurring within 24 h after administration of soman at five different doses with eight animals per dose (13). The efficacy of tested prophylactic drugs was expressed as protective ratio (LD_{50} val-

ue of soman in pretreated mice / LD_{50} value of soman in non-pretreated mice).

EVALUATION OF THE INFLUENCE OF REVERSIBLE INHIBITORS OF AChE ON THE THERAPEUTIC EFFICACY OF ANTIDOTAL TREATMENT

To evaluate the influence of reversible inhibitors of AChE on the therapeutic efficacy of antidotal treatment, all tested AChE reversible inhibitors were administered 30 minutes before soman poisoning while antidotal treatment (the oxime HI-6 at a dose corresponding to 5% of its LD_{50} in combination with atropine - 10 mg/kg) was carried out by i.m. injection 1 min after soman administration. Soman-induced toxicity was evaluated by the assessment of LD_{50} value and its 95% confidence limit using probit-logarithmical analysis of death occurring within 24 h after administration of soman at five different doses with eight animals per dose (13). The influence of tested prophylactic drugs on the antidotal treatment of soman poisoning was expressed as protective ratio A (LD_{50} value of soman in pretreated mice with antidotal treatment / LD_{50} value of soman in non-pretreated mice without antidotal treatment) and protective ratio B (LD_{50} value of soman in pretreated mice with antidotal treatment / LD_{50} value of soman in non-pretreated mice with antidotal treatment). The differences between LD_{50} values were considered to be significant when $p < 0.05$ (13).

RESULTS

The acute i.m. toxicity of all reversible inhibitors of AChE in mice is summarized in Table 1. The results show that the acute toxicity of newly prepared reversible inhibitors of AChE is quite different. While the acute toxicity of 7-phenoxytacrine, compound 2 and, especially, compound 1 is relatively low, the acute toxicity of 6-chlorotacrine is markedly higher although it is still lower than the acute toxicity of commonly used pyridostigmine. According to our results, the compound 1 seems to be the least toxic reversible inhibitor of AChE among all compounds studied.

A comparison of the prophylactic efficacy of pyridostigmine and all newly prepared reversible AChE inhibitors is presented in Table 2. Among all reversible inhibitors of AChE studied, 6-chlorotacrine was only able to markedly increase the resistance of experimental animals against acute toxicity of soman. Due to the prophylactic administration of 6-chlorotacrine, the LD₅₀ value of soman was increased from 49.5 µg/kg to 67.3 µg/kg. On the other hand, other reversible inhibitors of AChE including commonly used pyridostigmine were not able to influence the LD₅₀ value of soman.

A comparison of the benefit of pyridostigmine and all newly prepared reversible AChE inhibitors for the therapeutic efficacy of antidotal treatment of soman poisoning is presented in Table 3. Two newly prepared reversible inhibitors of AChE (6-chlorotacrine, compound 2) markedly increased the efficacy of the antidotal treatment of soman-poisoned mice consisting of the oxime HI-6 and at-

ropine. Due to the prophylactic administration of 6-chlorotacrine or compound 2, the protective ratio induced by antidotal treatment of soman poisoning was increased from 2.39 to 3.25, resp. 3.27. On the other hand, the prophylactic administration of other newly prepared reversible AChE inhibitors (7-phenoxytacrine, compound 1) as well as currently used pyridostigmine bromide did not influence the therapeutic efficacy of chosen antidotal treatment of soman-poisoned mice.

Reversible inhibitor of AChE	LD ₅₀ (mg/kg) ± 95% CL
Pyridostigmine bromide	3.24 (2.56–4.37)
6-chlorotacrine	10.08 (8.28–12.24)
7-phenoxytacrine	86.0 (61.0–109.1)
1	402.81 (314.7–513.0)
2	57.28 (46.5–78.0)

Tab. 1: Acute toxicity of reversible inhibitors of AChE in mice.

Pretreatment	LD ₅₀ (mg/kg) ± 95% CL	Protective ratio
–	49.5 (34.0–72.1)	–
Pyridostigmine bromide	47.0 (39.3–78.1)	0.95
6-chlorotacrine	67.3 (58.5–75.7)	1.36
7-phenoxytacrine	50.2 (38.5–65.7)	1.01
1	48.2 (35.1–63.1)	0.97
2	50.1 (34.6–54.0)	1.01

Tab. 2: Prophylactic effect of reversible inhibitors of AChE on the LD₅₀ value of soman in mice.

Pretreatment	Treatment	LD ₅₀ (mg/kg) ± 95% CL	Protective ratio A	Protective ratio B
–	–	92.3 (73.7–143.6)	–	–
–	HI-6 atropine	220.5 (189.8–297.3)*	2.39	–
Pyridostigmine bromide	HI-6 atropine	238.1 (202.4–309.4)*	2.58	1.08
6-chlorotacrine	HI-6 atropine	299.9 (240.8–408.2)*	3.25	1.36
7-phenoxytacrine	HI-6 atropine	196.7 (150.9–239.5)*	2.13	0.89
1	HI-6 atropine	201.4 (182.6–221.7)*	2.18	0.91
2	HI-6 atropine	302.0 (235.6–386.9)*	3.27	1.37

Tab. 3: The influence of pharmacological pretreatment on the effect of antidotal treatment on the LD₅₀ value of soman in mice. Statistical significance: * p < 0.05 (between non-pretreated and non-treated mice and pretreated and/or treated mice).

DISCUSSION

Sufficiently effective pretreatment is considered to be very important especially in the case of soman exposure because soman-induced deleterious effects are extraordinarily difficult to counteract due to very low reactivating efficacy of currently used oximes (14). The reason for the weak reactivating potency of the oximes is very rapid aging of phosphonylated AChE (15–16).

Better therapeutic effects of antidotal treatment can be achieved by pretreatment with reversible AChE inhib-

itors (9, 17). The protection of AChE against inhibition focused on the use of reversible AChE inhibitor is the most common principle of pharmacological pretreatment of nerve agent poisoning. Protection of AChE against inhibition – i.e. remaining intact AChE is a basic requirement for normal function of peripheral and central cholinergic nervous systems. Due to this pretreatment, the enzyme AChE became resistant to nerve agent-induced irreversible inhibition (18). It can be achieved by using reversible inhibitors (preferably carbamates) which are able to inhibit AChE reversibly with spontaneous recovery of the

activity (decarbamylation). Recovered activity of AChE serves as a source of the active enzyme (9). The reversible cholinesterase inhibitor pyridostigmine bromide, a well-known cholinesterase inhibitor, can be used for the treatment of Myasthenia gravis or for the prophylaxis against intoxication caused by organophosphorous nerve agents, especially against soman poisoning (19–21). Pyridostigmine is rapidly absorbed following oral administration determined as inhibition of the blood cholinesterases. The maximum inhibition is achieved 2–3 hours and lasts more than 8 hours. The half-life of inhibition is about 20 hours (18–19, 22). Based on these results, pyridostigmine was introduced into some armies as a prophylactic drug against nerve agents. Pyridostigmine bromide is stockpiled by various armed forces for pretreatment purpose against nerve agent poisoning and has been used by several thousand servicemen during UN operation against Iraq in 1991 (23). The important benefit of pyridostigmine bromide is the fact that it does not affect the combat readiness of the soldiers prior to nerve agent exposure and, therefore, it was chosen for the pretreatment of soldiers in the case of the threat of exposure to nerve agents. Nevertheless, our results demonstrate the shortage of effectiveness of pyridostigmine bromide alone to increase the resistance of nerve agent-exposed experimental animals (24). Its prophylactic effect is increased with its dose, however, higher doses cause more pronounced side effects. As pyridostigmine bromide is relatively toxic and the difference between its therapeutic and toxic dose is small, the safe dose for pharmacological pretreatment of nerve agent poisonings is limited and its prophylactic efficacy, when administered at safe doses, is unsatisfactory (25–26). In addition, it was demonstrated that exposure to physiologically relevant doses of pyridostigmine leads to neurobehavioral deficits and region-specific alterations in AChE and ACh receptors (27). It is known that commonly used pyridostigmine bromide as a prophylactic drug in the case of threat of exposure to nerve agents is able to protect just peripheral AChE. On the other hand, nerve agents, especially fluorophosphonates such as soman, sarin and cyclosarin, easily penetrate through BBB and markedly inhibit brain AChE. In addition, the currently used reactivators of nerve agent-inhibited AChE, monopyridinium or bispyridinium oximes poorly penetrate through BBB and, therefore, their ability to reactivate nerve agent-inhibited AChE in the brain is very limited. The usage of reversible inhibitors of AChE, that are able to cross the BBB, brings the protection of brain AChE from irreversible inhibition by nerve agents. This fact is important and useful for the increase of resistance of organism against nerve agents and the increase of the efficacy of post-exposure antidotal treatment. Of course, it is necessary to be careful with the dosage of centrally acting prophylactic drug. The doses of reversible inhibitors of AChE must be sufficiently safe to avoid peripheral as well as central adverse drug reactions and to maintain battle readiness of troops. Therefore, the searching for less toxic, more effective and centrally active reversible inhibitors of AChE seems to be rationale to increase the effectiveness of pharmacological pretreatment of nerve agent poisonings. During recent years, numerous alternative substances with known anti-cholinesterase

activity have been studied to evaluate their prophylactic efficacy in comparison with pyridostigmine bromide (28–31). Some of them are already in clinical use or have been developed as potential therapeutics for other indications such as Myasthenia gravis (32) or Alzheimer's disease (AD) (33–34).

One of the promising approaches how to find sufficiently effective reversible inhibitor of AChE for the pharmacological pretreatment of nerve agent poisonings is to develop substituted analogues of tacrine. Tacrine (9-amino-1,2,3,4-tetrahydroacridine) is a reversible inhibitor of AChE that was launched in 1993 as the first drug for the symptomatic treatment of AD (35). However, recent evaluations of the clinical effects of tacrine have confirmed the adverse events consisting in the elevated liver transaminase levels and in dose-related peripheral cholinergic effects (36). Therefore, its clinical use as a drug for the treatment of AD was discontinued. Substituents in position 6 of the tetrahydroacridine moiety exerted relative steric freedom and favorable electron-attracting effect that represents a possibility of a hydrophobic interaction between some amino acid residues and substituents in position 6 of tacrine in the active site of AChE. On the other hand, substituents in position 7 of the tetrahydroacridine moiety exerted detrimental steric effect that represents strongly negative contribution for their enzyme inhibitory activity (37). This conclusion corresponds to our results. While tacrine derivative substituted in the position 6 (6-chlorotacrine) due to its increased inhibitory potency towards AChE was able to increase the resistance of experimental animals against lethal toxicity of soman and to increase the therapeutic efficacy of recommended antidotal treatment of acute soman poisoning, the tacrine derivative with a substitution in the position 7 (7-phenoxytacrine) was not effective. Novel multi-target directed ligands (tacrine-pyridine-3-carboxamide hybrids) 1 and 2 were selected upon their IC_{50} values (1: $hAChE IC_{50} = 3.81 \pm 2.4 \mu M$; 2: $hAChE IC_{50} = 0.097 \pm 0.009 \mu M$) to confront the multifactorial nature of AD by combining $hAChE$ inhibitor with antioxidant action provided by hydrazinonicotinamide (38–39). Based on the inhibitory properties, compound 2 was able to increase the therapeutic efficacy of antidotal treatment of acute soman poisoning, while analogue of 7-methoxytacrine (compound 1) is not effective because the potency of 7-methoxytacrine to inhibit AChE is generally much lower compared to tacrine (7-methoxytacrine: $hAChE IC_{50} = 10.00 \pm 1.0 \mu M$; tacrine: $hAChE IC_{50} = 0.32 \pm 0.01 \mu M$) (40). Generally, the tacrine analogues exerting the sufficient prophylactic efficacy due to their potency to reversibly inhibit AChE in the peripheral and central nervous systems are more toxic. However, the acute toxicity of effective tacrine analogues studied is significantly lower compared to commonly used pyridostigmine and, therefore, their safe dose is higher and more effective.

CONCLUSION

In spite of some promising results in the case of prophylactic administration of 6-chlorotacrine and compound 2, the basic principle of pharmacological pretreatment of

nerve agent poisonings – the protection of AChE from nerve agent-induced irreversible inhibition by administration of reversible AChE inhibitors is somewhat limited, especially by relatively high toxicity of sufficiently effective reversible inhibitors of AChE. On the other hand, our results also show that it is possible to develop sufficiently effective, centrally acting reversible inhibitors of AChE that are more effective and less toxic drugs for pharmacological pretreatment of nerve agent exposure than commonly used pyridostigmine bromide.

ACKNOWLEDGEMENTS

The authors express their appreciation to Mrs J. Uhlířová for her skill technical assistance. The study was funded by the grant of Ministry of Defense of the Czech Republic – “Long-term organization development plan Medical Aspects of Weapons of Mass Destruction of the Faculty of Military Health Sciences, University of Defence”.

REFERENCES

- Yanagisawa N, Morita H, Nakajima T. Sarin experience in Japan. Acute toxicity and long-term effects. *J Neurol Sci* 2006; 249: 76–85.
- Bajgar J. Organophosphate/nerve agent poisoning: mechanism of action, diagnosis, prophylaxis and treatment. *Adv Clin Chem* 2004; 38: 151–216.
- Colovic MB, Krstic DZ, Lazarevic-Pasti TD, Bondzic AM, Vasic VM. Acetylcholinesterase Inhibitors: Pharmacology and Toxicology. *Curr Neuropharmacol* 2013; 11: 315–35.
- Jokanovic M, Prostran, M. Pyridinium oximes as cholinesterase reactivators. Structure-activity relationship and efficacy in the treatment of poisoning with organophosphorus compounds. *Curr Med Chem* 2009; 16: 2177–88.
- Kassa, J. Review of oximes in the antidotal treatment of poisoning by organophosphorus nerve agents. *J Toxicol Clin Toxicol* 2002; 40: 803–16.
- Shih TM. Comparison of several oximes on reactivation of soman-induced blood, brain and tissue cholinesterase activity in rats. *Arch Toxicol* 1993; 67: 637–46.
- Lorke DE, Kalasz H, Petroianu GA, Tekes K. Entry of oximes into the brain: A review. *Curr Med Chem* 2008; 15: 743–53.
- Zdarova Karasova J, Zemek F, Bajgar J et al. Partition of bispyridinium oximes (trimedoxime, K074) administered in therapeutic doses into different parts of the rat brain. *J Pharm Biomed Anal* 2011; 54: 1082–7.
- Bajgar J, Fusek J, Kassa J, Kuca K, Jun D. Chemical aspects of pharmacological prophylaxis against nerve agent poisoning. *Curr Med Chem* 2009; 16: 2977–86.
- Layish I, Krivoy A, Rotman E, Finkelstein A, Tashma Z, Yehezkeili Y. Pharmacologic prophylaxis against nerve agent poisoning. *Isr Med Assoc J* 2005; 7: 182–7.
- Patočka J, Jun D, Bajgar J, Kuca K. Prophylaxis against nerve agent intoxication. *Def Sci J* 2006; 56: 775–84.
- Kassa J, Koupilova M., Herink J, Vachek J. The long term influence of low-level sarin exposure on behavioral and neurophysiological functions in rat. *Acta Medica (Hradec Kralove)* 2001; 44: 21–7.
- Tallarida R, Murray R. *Manual of Pharmacological Calculation with Computer Programs*, New York: Springer-Verlag, 1987.
- Mercey G, Verdelet T, Renou J et al. Reactivators of acetylcholinesterase inhibited by organophosphorus nerve agents. *Acc Chem Res* 2012; 45: 756–66.
- Antonijevic B, Stojilkovic MP. Unequal efficacy of pyridinium oximes in acute organophosphate poisoning. *Clin Med Res* 2007; 5: 71–82.
- Marrs TC, Rice P, Vale JA. The role of oximes in the treatment of nerve agent poisoning in civilian casualties. *Toxicol Rev* 2006; 25: 297–323.
- Lorke DE, Hasan MY, Nurulain SM, Shafullah M, Kuca K, Petroianu GA. Acetylcholinesterase inhibitors as pretreatment before acute exposure to organophosphates: assessment using methyl-paraoxon. *CNS Neurol Dis Drug Targets* 2012; 11: 1052–60.
- Tuovinen K, Kaliste-Korhonen E, Raushel FM, Hanninen O. Success of pyridostigmine, physostigmine, eptastigmine and phosphotriesterase treatments in acute sarin intoxication. *Toxicology* 1999; 134: 169–78.
- Gordon RK, Haigh JR, Garcia GE, Feaster SR, Riel MA, Lenz DE. Oral administration of pyridostigmine bromide and huperzine A protects human whole blood cholinesterases from ex vivo exposure to soman. *Chem-Biol Interact* 2005; 157: 239–46.
- Komloova M, Musilek K, Dolezal M, Gunn-Moore F, Kuca K. Structure-activity relationship of quaternary acetylcholinesterase inhibitors – outlook for early myasthenia gravis treatment. *Curr Med Chem* 2010; 17: 1810–24.
- Maxwell DM, Brecht KM, Doctor BP, Wolfe AD. Comparison of antidote protection against soman by pyridostigmine, HI-6 and acetylcholinesterase. *J Pharmacol Exp Therap* 1993; 264: 1085–9.
- Fusek J, Bajgar J, Merka V. Prophylaxe von Vergiftungen mit Nerven-kampfstoffen (Ergebnisse einer klinischen Studie). *Koord Sanitatsdienst* 2006; 24: 48–53.
- Wenger B, Quigley MD, Kokla MA. Seven-day pyridostigmine administration and thermoregulation during rest and exercise in dry heat. *Aviation Space Environ Med* 1993; 64: 905–11.
- Kassa J, Vachek J. A comparison of the efficacy of pyridostigmine alone and the combination of pyridostigmine with anticholinergic drugs as pharmacological pretreatment of tabun-poisoned rats and mice. *Toxicology* 2002; 177: 179–85.
- Dunn MA, Hackett BE, Sidell FR. Pretreatment for nerve agent exposure. In: Zajtchuk R, Bellamy RF, eds. *Textbook of Military Medicine: Medical Aspects of Chemical & Biological Warfare*, Washington DC: Office of the Surgeon General, Department of the Army, 1997: 181–96.
- Myhrer T, Aas P. Pretreatment and prophylaxis against nerve agent poisoning: Are undesirable behavioral side effects unavoidable? *Neurosci Biobehav Rev* 2016; 71: 657–70.
- Abou-Donia MB, Goldstein LB, Jones KH et al. Locomotor and sensorimotor performance deficit in rats following exposure to pyridostigmine bromide, DEET, and permethrin, alone and in combination. *Toxicol Sci* 2001; 60: 305–14.
- Kassa J, Musilek K, Koomlova M., Bajgar J. A comparison of the efficacy of newly developed reversible inhibitors of acetylcholinesterase with commonly used pyridostigmine as pharmacological pre-treatment of soman-poisoned mice. *Bas Clin Pharmacol Toxicol* 2012; 110: 322–6.
- Lorke DE, Hasan MY, Nurulain SM, Shafullah M, Kuca K, Petroianu GA. Pretreatment for acute exposure to diisopropylfluorophosphate: in vivo efficacy of various acetylcholinesterase inhibitors. *J Appl Toxicol* 2011; 31: 515–23.
- Petroianu GA, Hasan MY, Nurulain SM, Arafat K, Sheen R, Nagelkerke N. Comparison of two pre-exposure treatment regimens in acute organophosphate (paraoxon) poisoning in rats: tiapride vs pyridostigmine. *Toxicol Appl Pharmacol* 2007; 219: 235–40.
- Petroianu GA, Nurulain SM, Shafullah M, Hasan MY, Kuca K, Lorke DE. Usefulness of administration of non-organophosphate cholinesterase inhibitors before acute exposure to organophosphates: assessment using paraoxon. *J Appl Toxicol* 2013; 33: 894–900.
- Komloova M, Musilek K, Horova A et al. Preparation, in vitro screening and molecular modelling of symmetrical bis-quinolinium cholinesterase inhibitors-implications for early Myasthenia gravis treatment. *Bioorg Med Chem Lett* 2011; 21: 505–9.
- Korabecny J, Musilek O, Holas O et al. Synthesis and in vitro evaluation of N-(bromobut-3-en-7-yl)-7-methoxy-1,2,3,4-tetrahydroacridine-9-amine as a cholinesterase inhibitor with regard to Alzheimer's disease treatment. *Molecules* 2010; 15: 8804–12.
- Spilovska K, Korabecny J, Kral J et al. 7-methoxy-tacrine-adamantylamine heterodimers as cholinesterase inhibitors in Alzheimer's disease treatment – synthesis, biological evaluation and molecular modelling studies. *Molecules* 2013; 18: 2397–418.
- Davis KL, Powchik P. Tacrine. *Lancet* 1995; 345: 625–30.
- Gracon SI, Berghoff WG. Cholinesterase inhibition in the treatment of Alzheimer's disease: further evaluation of the clinical effects of tacrine. In Brioni JD, Decker MW, eds. *Pharmacological Treatment of Alzheimer's Disease. Molecular and Neurobiological Foundations*. New York: Wiley-Liss Inc, 1997: 389–408.
- Recanatini M, Cavalli A, Belluti F et al. SAR of 9-amino-1,2,3,4-tetrahydroacridine-based acetylcholinesterase inhibitors: synthesis, enzyme inhibitory activity, QSAR and structure-based CoMFA of tacrine analogues. *J Med Chem* 2000; 43: 2007–18.
- Szymański P, Markowicz M, Mikiciuk-Olasik E. Synthesis and biological activity of derivatives of tetrahydroacridine as acetylcholinesterase inhibitors. *Bioorg Chem* 2011; 39: 138–42.

39. Zemek F, Drtinova L, Nepovimova E et al. Outcomes of Alzheimer's disease therapy with acetylcholinesterase inhibitors and memantine. *Expert Opin Drug Saf* 2014; 13: 759-74.
40. Nepovimova E, Korabecny J, Dolezal R et al. Tacrine-trolox hybrids: a novel class of centrally active, nonhepatotoxic multi-target-directed ligands exerting anticholinesterase and antioxidant activities with low in vivo toxicity. *J Med Chem* 2015; 58: 8985-9003.

Papillary Thyroid Carcinoma: Analysis of the Central Compartment's Lymph Nodes Metastases



Ján Sojak^{1,2,3,*}, Marian Sičák¹, Adrian Kališ⁵, Michal Slašťan⁴

ABSTRACT

Background: Papillary thyroid carcinoma is typical by regional lymph nodes metastases. Therefore we decided to analyse associated risk factors. **Objective:** In this retrospective study we focused on the incidence of metastatic involvement of the central compartment's lymph nodes correlated with age, size of the primary tumour, infiltration of thyroid gland capsule, positive lymphangioinvasion in order to assess risk factors. **Method:** We analysed group of 156 patients with papillary carcinoma, who have undergone total thyroidectomy and bilateral elective central compartment neck dissection. We evaluated the occurrence of metastases, size, infiltration and lymphangioinvasion based on definitive histology of the whole group and separately for subgroups of patients under and over 45 years. **Result:** We found metastatic involvement in 88 (56.4%) patients. When comparing the subgroups of patients under (73 patients) and over 45 years (83 patients), we found metastases in 56 vs. 32 (76.7% vs. 38.6%) patients. In the subgroup of younger patients we found significant higher incidence of metastases compared with the group of over 45 years, $P < 0.001$ ($P = 0.000027$). We found significant higher incidence of metastases in patients with positive capsule infiltration in the whole group, $P < 0.001$ ($P = 0.00049$); in the subgroup of under 45 years, $P < 0.001$ ($P = 0.00091$) and in patients with positive lymphangioinvasion in the whole group, $P < 0.01$ ($P = 0.00177$); in the subgroup of over 45 years, $P < 0.001$ ($P = 0.0002$). In patients with metastases we found tumour size $\geq 1\text{cm}$ more frequently in all groups. **Conclusion:** We recorded higher incidence of regional metastases in patients under 45 years, positive capsule infiltration, lymphangioinvasion. Age under 45 years itself does not correlate with less aggressive disease, to the contrary some of other analysed risk factors correlate with more aggressive disease.

KEYWORDS

papillary carcinoma; thyroid gland; metastases; regional lymph nodes; age

AUTHOR AFFILIATIONS

¹ Slovak Medical University in Bratislava, Faculty of Medicine, The Clinic of Otorhinolaryngology and Head and Neck Surgery, Central Military Hospital in Ružomberok, Slovakia

² Comenius University in Bratislava, Jessenius Faculty of Medicine in Martin (JFM CU), Department of Pathological Physiology JFM CU, Slovakia

³ Biomedical Centre Martin JFM CU, Slovakia

⁴ Department of Medical Biochemistry JFM CU, Slovakia

⁵ Catholic University in Ružomberok, Faculty of Health, Department of Pathological Anatomy, Central Military Hospital in Ružomberok, Slovakia

* Correspondence author: Klinika ORL a CHHaK, Ústredná vojenská nemocnica SNP-FN, Ul. gen. Miloša Vesela 21, 034 01 Ružomberok, Slovakia; e-mail: jansojak@gmail.com

Received: 25 November 2016

Accepted: 20 December 2016

Published online: 1 June 2017



Acta Medica (Hradec Králové) 2017; 60(1): 44–50

<https://doi.org/10.14712/18059694.2017.49>

© 2017 The Authors. This is an open-access article distributed under the terms of the Creative Commons Attribution License (<http://creativecommons.org/licenses/by/4.0>), which permits unrestricted use, distribution, and reproduction in any medium, provided the original author and source are credited.

INTRODUCTION

Papillary thyroid carcinoma (PTC) and its variants belong to the group of differentiated thyroid carcinomas and to the most common oncological disease of the thyroid gland (1). To stage PTC we use the TNM classification (Table 1), where patients younger than 45 years without remote metastases (M0) belong to the stage I regardless of the T and N (2).

Tab. 1: TNM classification – staging (2).

Papillary or follicular carcinoma, patient under 45 years			
Stage I	any T	any N	M0
Stage II	any T	any N	M1
Papillary or follicular carcinoma, patient above 45 years			
Stage I	T1	N0	M0
Stage II	T2	N0	M0
Stage III	T3	N0	M0
	T1, T2, T3	N1a	M0
Stage IV A	T1, T2, T3	N1b	M0
	T4a	N0, N1	M0
Stage IV B	T4b	any N	M0
Stage IV C	any T	any N	M1

T1 – tumour ≤ 2cm, intraglandular; T2 – tumour >2 to 4cm, intraglandular; T3 – tumour > 4cm or limited spread; T4a – skin, larynx, trachea, oesophagus or nervus laryngeus recurrens infiltration; T4b – prevertebral fascia, mediastinal vessels or arteria carotis infiltration; N0 – without metastases in regional lymph nodes; N1a – metastases in region VI; N1b – metastases in other regions; M0 – no remote metastases; M1 – remote metastases

Mortality in patients with PTC ranges from 1.2 to 17%; the average five-year survival in PTC limited to the thyroid gland tissue is 99.7%, in case of metastases into regional lymph nodes (LN) 96.9%, and with remote metastases 57.8% (3); the average ten-year survival is between 85 to 99% (4) and drops with increasing tumour size and extra-thyroid growth (5). Some papers point to higher risk of nodal recurrence, worse prognosis and increase of risk of death by 46% related to occurrence of regional LN metastases (3, 6).

Regional LN metastases are found in 20–80% patients (56.4% in the whole group of our patients). The central compartment (region VI) is involved with a frequency reaching 90% including micro metastases (1, 3, 4); less frequently are affected areas III, IV and rarely areas II and V (7). Persistence and recurrence of PTC are influenced by regional LN metastatic involvement, size of the primary tumour, extracapsular growth, and remote metastases. Persistence and recurrence of the illness decrease average survival independently from the age of patients and decrease quality of life by more radical and repeated surgical interventions and oncological treatment with radioactive iodine and external radiotherapy (1, 8, 9).

The aim of this study was to analyse the incidence of metastatic involvement of central compartment LN correlated to the age limit of 45 years.

MATERIAL AND METHODS

We performed a retrospective analysis of collected archived data obtained from 336 patients suffering from PTC (out of which 276 cases were the conventional variant, in 44 cases the follicular variant and in 16 cases oncocyary variant of PTC; 259 females and 77 males) who had surgery at our clinic during the time frame of 2003 till 2015. These patients underwent a standard diagnostic and therapeutic procedure which was not affected by this study. Patients signed an informed consent allowing us to analyse all collected personal and medical data.

Included in the group, there were patients meeting the following inclusion criteria: The patient underwent a model of initial surgical therapy – lobectomy on the side of the suspected carcinoma with intraoperative biopsy (frozen section). In case of a positive finding of PTC from intraoperative biopsy surgery was finished with total thyroidectomy and a bilateral elective central compartment neck dissection (level VI) regardless of age. In case of a negative finding in the intraoperative biopsy, the surgery was finished as a lobectomy; with positive finding of PTC in definite biopsy following the lobectomy a reoperation was performed within 6 weeks of the primary surgery – finished total thyroidectomy and a bilateral elective central compartment neck dissection regardless of age. Selective neck dissection of LN groups in levels I, II, III, IV, V was only performed if deemed necessary by individual case with clinical suspicion of regional metastasizing (cN+) to those cervical levels (Table 2). None of the patients underwent any forms of adjuvant therapy as this therapy was implied only post-surgery by an endocrinologist. Patients who have met the following exclusion criteria are not included (in spite of a positive find of PTC in intraoperative and/or definite histology) – patient has not undergone total thyroidectomy, has not undergone bilateral elective central compartment neck dissection, underwent only unilateral elective central compartment neck dissection, has not undergone neck dissection, relevant data was not available, patient underwent surgery in a different way than that described in inclusion criteria.

156 patients met the criteria with histologically verified PTC, who underwent total thyroidectomy and bilateral neck dissection of regional LN in minimal range of bilateral elective central compartment neck dissection. This group has been divided by the age limit 45 years (using by TNM classification) into a subgroup of patients under 45 years (73 patients) and a subgroup of patients over 45 years (83 patients). Only 46.4% of patients with pathologically verified carcinomas met the inclusion criteria. The most frequent unmet inclusion criterion was above described unmet model of initial surgical therapy (total thyroidectomy and a bilateral elective central compartment neck dissection regardless of age). The reason dwells in fact that this model has been applied at our clinic gradually, e.g. in years 2003, 2005, 2007 it has not been applied in any of the patients, in years 2004, 2006, 2008 it was applied only in one patient per year, and yet, for instance, in year 2015 there were already 24 patients subjected to this initial surgery model.

Tab. 2: Patients after total thyroidectomy and bilateral neck dissection.

Range of surgical intervention	All patients (N = 156)	Under 45 y. (N = 73)	Over 45 y. (N = 83)
	n (%)	n (%)	n (%)
TTE + bilateral central compartment ND	120 (76.9)	55 (75.3)	65 (78.3)
TTE + bilateral central compartment ND + unilateral selective ND	29 (18.6)	14 (19.2)	15 (18.1)
TTE + bilateral central compartment ND + bilateral selective ND	7 (4.5)	4 (5.5)	3 (3.6)

n – number of patients, % – relative percentage, N – number of patients in the whole group, TTE – total thyroidectomy, ND – neck dissection

Tab. 3: Histologically verified metastatic involvement of regional lymph nodes.

Regional lymph nodes metastases	All patients (N = 156)	Under 45 y. (N = 73)	Over 45 y. (N = 83)
	n (%)	n (%)	n (%)
Positive metastases	88 (56.4)	56 (76.7)	32 (38.6)
– Positive metastases unilateral	52 (33.3)	34 (46.6)	18 (21.7)
– Positive metastases bilateral	36 (23.1)	22 (30.1)	14 (16.9)
Negative metastases	68 (43.6)	17 (23.3)	51 (61.4)

n – number of patients, % – relative percentage, N – number of patients in the whole group

In a group of patients who underwent preoperative ultrasonography, a suspicious lymphadenopathy (cN+) was diagnosed in 29%, however based on the definitive histology we have confirmed regional LN metastases on the level of 56.4%. Sensitivity of preoperative fine needle aspiration biopsy (FNAB) at our workplace equalling to 94.7% and sensitivity of intraoperative biopsy equalling to 89.7%. Incidence of after surgery complications was not for this particular group patients evaluated due to the missing data, however as far as our department is concerned there was not higher risk in connection with thyroid surgery noted. Due to the lower percentage of suspicious lymphadenopathy identified by the preoperative ultrasonography examination and high incidence of regional LN metastases verified by definitive histology we consider the elective central neck dissection in case of histological confirmed PTC as reasonable.

Based on definitive histology we evaluated the occurrence of metastases in central compartment LN, size of the primary tumour, infiltration of thyroid gland capsule and lymphangiogenesis for the whole group, and separately for both subgroups defined by age. As positive metastatic involvement we assessed the case of at least one LN metastasis in central compartment verified by definitive histology, while the size of the LN metastasis was not taken into consideration. It is not relevant whether the positive histology is from the primary intervention or reoperation (within 6 weeks of the primary surgery).

This study is limited by certain factors, which could be potentially removed by planning of a prospective study that would specify the exact definition of studied criteria. What I mean is unreliable, improper or missing data and information concerning size and the exact number of me-

tastases, precise measurement of thyroid gland capsule infiltration, and precise analysis of affection levels I.-V. Histological findings were evaluated by different pathologists and surgeries performed by various surgeons in a long time period. We are missing the exact information regarding the occurrence of complications. A more precise post-surgery follow up, documentation of possible recurrences, remote metastases, process of complications as well as adjuvant therapy used is needed. These are missing due to the fact that the post-surgery aftercare in our region is managed by endocrinologist. We would also need correlation of the LN metastases incidence and increased risk of local recurrences and death. Due to the long survival in PTC, long term survival data is needed.

The results were interpreted using relative quantity and one-dimensional chi-square test with Yates correction on the level of significance 0.01 and 0.001 (software Statistica 8).

RESULTS

METASTATIC INVOLVEMENT IN REGIONAL LYMPH NODES

In our group of 156 patients with PTC, who underwent total thyroidectomy and bilateral neck dissection of regional LN in minimal range of bilateral elective central compartment neck dissection, we evaluated metastatic involvement based on definitive histological study of the central compartment LN. The information concerning metastatic involvement of LN was available in 100% of the patients. We evaluated the whole group, the subgroup under 45 years and the subgroup of patients over 45 years (Table 3).

Tab. 4: Size of primary tumour.

Size of primary tumour	All patients (N = 150)	Under 45 y. (N = 72)	Over 45 y (N = 78)
<i>No. of patients in the whole group (156 patients)</i>	n (%)	n (%)	n (%)
Tumour size < 1cm	59 (39.3)	24 (33.3)	35 (44.9)
Tumour size ≥ 1cm	91 (60.7)	48 (66.7)	43 (55.1)
Tumour size undetermined	6	1	5
Patients with MTS - pN+	84 (56)	55 (76.4)	29 (37.2)
Tumour size < 1cm, pN+	31 (20.7)	17 (23.6)	14 (17.9)
Tumour size ≥ 1cm, pN+	53 (35.3)	38 (52.8)	15 (19.2)
Tumour size undetermined, pN+	4	1	3
Patients without MTS – pN0	66 (44)	17 (23.6)	49 (62.8)
Tumour size < 1cm, pN0	28 (18.7)	7 (9.7)	21 (26.9)
Tumour size ≥ 1cm, pN0	38 (25.3)	10 (13.9)	28 (35.9)
Tumour size undetermined, pN0	2	0	2

n – number of patients, % – relative percentage, N – number of patients in the evaluated group, MTS – metastatic involvement, pN+ – histologically verified metastases in regional lymph nodes, pN0 – histologically verified status without metastases in regional lymph nodes

Comparing the subgroups of under 45 years and over 45 years we found metastatic involvement in 76.7% vs. 38.6% patients. In the subgroup of under 45 years we found on the level of statistical significance 0.001 higher incidence of metastatic involvement of central compartment LN when compared to patients over 45 years, $P < 0.001$ ($P = 0.000027$).

SIZE OF THE PRIMARY TUMOUR

We evaluated the tumour size <1cm and ≥1cm based on the results of the histology. We made the evaluation for the group of all patients, the group of under 45 years, the group of over 45 years, correlated to metastatic involvement as well (Table 4). The information about the tumour size was available in 150 patients (96.2%).

During statistical analysis we have not found statistically significant higher incidence of metastatic involvement linked with tumour size ≥ 1cm in the group of all patients ($P = 0.604$); in the subgroup of patients under 45 years ($P = 0.62$); in the subgroup of patients over 45 years ($P = 0.818$). However, in patients with verified metastatic involvement we have found the size of tumour ≥1cm more frequently in all groups.

INFILTRATION OF THE CAPSULE OF THYROID GLAND

We evaluated the groups for infiltration of the capsule based on the histological finding, whereas even the finding of limited focal thyroid gland capsule infiltration without extrathyroid spreading was regarded as positive case. The evaluation was done for the whole group of patients, for the subgroup of under 45 years, and for the subgroup of over 45 years, correlated to metastatic involvement (Table 5). The information was available in 151 patients (96.8%).

During the statistical evaluation we noted on a level of statistical significance 0.001 in patients with positive infiltration of thyroid gland capsule more frequent metastatic involvement and in patients with negative infiltration less frequent metastatic involvement in the whole group of patients, $P < 0.001$ ($P = 0.00049$) and in the group of patients under 45 years $P < 0.001$ ($P = 0.00091$). In the group of patients over 45 years we haven't found significantly more frequent metastatic involvement with positive infiltration of thyroid gland capsule ($P = 0.146$).

LYMPHANGIOINVASION

Based on the definitive histological examination and findings we have evaluated the presence of lymphangiogenesis. The evaluation was done for the whole group, for the subgroup of under 45 years of age and for the subgroup over 45 years, correlated to metastatic involvement (Table 6). The information concerning lymphangiogenesis was available in 142 (91%) patients.

During statistical evaluation we found on levels of statistical significance 0.01 a 0.001 patients with positive lymphangiogenesis more frequent metastatic involvement and in patients without lymphangiogenesis less frequent metastatic involvement in the group of all patients, $P < 0.01$ ($P = 0.00177$) and in the subgroup of over 45 years, $P < 0.001$ ($P = 0.0002$). In the subgroup of patients under 45 years of age we have not found significantly more frequent metastatic involvement with positive lymphangiogenesis ($P = 0.085$).

Tab. 5: Thyroid gland capsule infiltration.

Capsule infiltration	All patients (N = 151)	Under 45 y. (N = 71)	Over 45 y. (N = 80)
<i>No. of patients in the whole group (156 patients)</i>	n (%)	n (%)	n (%)
Capsule infiltration positive	107 (70.9)	53 (74.6)	54 (67.5)
Capsule infiltration negative	44 (29.1)	18 (25.4)	26 (32.5)
Capsule infiltration undetermined	5	2	3
Patients with MTS – pN+	83 (55)	54 (76.1)	29 (36.3)
Capsule infiltration positive, pN+	69 (45.7)	46 (64.8)	23 (28.8)
Capsule infiltration negative, pN+	14 (9.3)	8 (11.3)	6 (7.5)
Capsule infiltration undeterm., pN+	5	2	3
Patients without MTS – pN0	68 (45)	17 (23.9)	51 (63.8)
Capsule infiltration positive, pN0	38 (25.2)	7 (9.9)	31 (38.8)
Capsule infiltration negative, pN0	30 (19.9)	10 (14.1)	20 (25)
Capsule infiltration undeterm., pN0	0	0	0

n – number of patients, % – relative percentage, N – number of patients in the evaluated group, MTS – metastatic involvement, pN+ – histologically verified metastases in regional lymph nodes, pN0 – histologically verified status without metastases in regional lymph nodes

DISCUSSION

The aim of this study was to analyse the incidence of metastatic involvement of the central compartment LN correlated to the age limit of 45 years. We also analysed size of primary tumour, infiltration of thyroid gland capsule and lymphangiogenesis in order to evaluate these relevant risk factors. Our intention is to offer an impulse to analyse surgical approaches and re-evaluate their effect with the emphasis on younger patients whereas age under 45 years in our study does not correlate with less aggressive disease and we regard to use age itself as an independent risk factor to be controversial.

The frequency of metastatic involvement of regional LN in patients under 45 years in our study reached 76.7% (in all patients 56.4%; in patients over 45 years 38.6%). In our previous study we analysed metastatic involvement also in the whole cohort of our 336 patients with PTC regardless of model of initial surgical therapy. We found frequency of metastatic involvement of regional LN in 54.1% of patients under 45 years (in 37.8% of all patients; in 26.9% of patients over 45 years) (10). It also proves that the bilateral elective central compartment neck dissection increased in our collection frequency of metastasis verification in all groups of patients.

It is a matter to consider when thinking about the TNM staging, which in age group of patients younger than 45 years seemingly ignores the fact that the presence of metastases in regional LN can influence the rate of persistence, recurrence of the illness and quality of life.

For patients suffering from PTC is typical long term survival and the evaluation of the outcomes of treatment

algorithms and surgical approaches is time consuming. Opinions about benefits of different surgical approaches are controversial, especially about effect of elective central compartment neck dissection. Patients have a comparable ten-year survival with no regard to the scale of surgical treatment, this fact advocate the tendency of implementing limited surgical intervention and caution in more radical intervention indication (5, 11), but the incidence of regional LN metastases on the level of 56.4% in the whole group and as high as 74.6% in the group of under 45 years makes us rethink the possibility of performing total thyroidectomy and elective central compartment neck dissection as a standard surgical procedure in patients with positive intraoperative or definite histology. Some authors do not consider lobectomy itself to be an adequate primary radical intervention in patients with verified PTC because it is bound to a higher risk of local recurrence, contralateral lobe malignancy development in case of multifocal occurrence and this risk is higher in tumours ≥ 1 cm, regardless of age (1, 5). The lobectomy also deprives the patients of the possibility of adjuvant oncological treatment, monitoring (body scan, serum Tg measurement) and it increases the risk of revision (1).

It is suitable to take into account regardless of the long term survival also the quality of life of patients which is influenced by possibility of persistence, recurrence, generalization, the need for repeated surgical and radioiodine therapeutic procedures. If standard surgical approaches are maintained, a percentage of complications is low even in bigger scale primary interventions (5, 12), contrariwise long term complications after the reoperation can be twice as high as after the primary intervention (5, 13). When

Tab. 6: Lymphangioinvasion.

Lymphangioinvasion	All patients (N = 142)	Under 45 y. (N = 66)	Over 45 y. (N = 76)
No. of patients in the whole group (156 patients)	n (%)	n (%)	n (%)
Lymphangioinvasion positive	35 (24.6)	17 (25.8)	18 (23.7)
Lymphangioinvasion negative	107 (75.4)	49 (74.2)	58 (76.3)
Lymphangioinvasion undetermined	14	7	7
Patients with MTS – pN+	75 (52.8)	50 (75.8)	25 (32.9)
Lymphangioinvasion positive, pN+	27 (19)	16 (24.2)	11 (14.5)
Lymphangioinvasion negative, pN+	48 (33.8)	34 (51.5)	14 (18.4)
Lymphangioinvasion undet., pN+	13	6	7
Patients without MTS – pN0	67 (47.2)	16 (24.2)	51 (67.1)
Lymphangioinvasion positive, pN0	8 (5.6)	1 (1.5)	7 (9.2)
Lymphangioinvasion negative, pN0	59 (41.5)	15 (22.7)	44 (57.9)
Lymphangioinvasion undet., pN0	1	1	0

n – number of patients, % – relative percentage, N – number of patients in the evaluated group, MTS – metastatic involvement, pN+ – histologically verified metastases in regional lymph nodes, pN0 – histologically verified status without metastases in regional lymph nodes

making a decision regarding treatment strategy it is important to remember that a proper surgical intervention is still the most important treatment and treatment with radioiodine, TSH suppression, and external radiotherapy have adjuvant roles (1). Properly chosen initial surgery and following observation can achieve permanently cured state in 90% of the patients, it has a long term impact on recurrence and survival, reduces the risk of reoperation (12).

To inseparable part of thyroid gland surgery belong perioperative examinations, especially in cases of suspected thyroid cancer. Preoperative ultrasonography and FNAB can help us to make decisions concerning the extent of surgical intervention and intraoperative biopsy can coordinate further approaches of the surgeon (14). Preoperative ultrasonography identifies roughly half of regional LN found during the surgery and identifies suspect metastases in regional LN in 20–31% of cases (1). It is because LN are overlaid by thyroid gland tissue. The overall sensitivity reported for some of the suspicious ultrasound features in large-volume centres is 83–93% (15). FNAB sensitivity in experienced hands reaches 98.9% (16) and should be performed on all nodes >10 mm and in the case of clearly benign ultrasonography appearance only on those larger than 15 mm or 20 mm, respectively (1).

CONCLUSIONS

PTC is the most common oncological disease of the thyroid gland and its typical feature is good survival prognosis and high rate of regional metastases. When comparing metastatic involvement in the age groups of under and over

45 years, we have found statistically significantly higher incidence of metastatic involvement in the group of under 45 years compared to the group of over 45 years. We have also noted statistically significant higher incidence of metastatic involvement in patients with positive capsule infiltration and lymphangioinvasion. In patients with metastatic involvement we have also found the size of tumour ≥ 1 cm more frequently in all groups. Age under 45 years itself in our study does not correlate with less aggressive disease, to the contrary more aggressive disease correlate with positive capsule infiltration and lymphangioinvasion.

Actually the most effective treatment modality remains surgery and its aim is to eradicate the disease by primary intervention, to reduce the amount of incidental findings, the number of reinterventions, to avoid persistence, recurrence and to enable adjuvant oncotherapy.

REFERENCES

- Haugen BR, Alexander EK, Bible KC, et al. 2015 American Thyroid Association Management Guidelines for Adult Patients with Thyroid Nodules and Differentiated Thyroid Cancer: The American Thyroid Association Guidelines Task Force on Thyroid Nodules and Differentiated Thyroid Cancer. *Thyroid* 2016; 26(1): 1–133.
- Brierley JD, Panzarella T, Tsang RW, et al. A comparison of different staging systems predictability of patient outcome. *Thyroid carcinoma as an example. Cancer* 1997; 79(12): 2414–2423.
- Teixeira G, Teixeira T, Gubert F, et al. The incidence of central neck micrometastasis disease in patients with papillary thyroid cancer staged preoperatively and intraoperatively as N0. *Surgery* 2011; 150(6): 1161–1167.
- Patron V, Hitier M, Bedfert C, et al. Predictive factors for lateral occult lymph node metastasis in papillary thyroid carcinoma. *Eur Arch otorhinolaryngol* 2013; 270(7): 2095–2100.

5. Bilimoria KY, Bentrem DJ, Ko CY, et al. Extent of surgery affects survival for papillary thyroid cancer. *Ann Surg* 2007; 246(3): 375-381.
6. Zaydfudim V, Feurer ID, Griffin MR, et al. The impact of lymph node involvement on survival in patients with papillary and follicular thyroid carcinoma. *Surgery* 2008; 144(6): 1070-1078.
7. Hartl DM, Mamelle E, Borget I, et al. Influence of prophylactic neck dissection on rate of retreatment for papillary thyroid carcinoma. *World J Surg* 2013; 37(8): 1951-1958.
8. Lebolleux S, Rubino C, Baudin E, et al. Prognostic factors for persistent or recurrent disease of papillary thyroid carcinoma with neck lymph node metastases and/or tumor extension beyond the thyroid capsule at initial diagnosis. *J Clin Endocrinol Metab* 2005; 90(10): 5723-5729.
9. Links TP, van Tol KM, Jager PL, et al. Life expectancy in differentiated thyroid cancer: a novel approach to survival analysis. *Endocr Relat Cancer* 2005; 12(2): 273-280.
10. Sičák M, Sojak J, Slašťan M, et al. Papilárny karcinóm štítnej žľazy: Analýza veľkosti primárneho tumoru, infiltrácie puzdra štítnej žľazy a lymfangoinvázie vzhľadom k lokoregionálnemu metastázovaniu a veku. *Otorinolaryng a Foniatic (Prague)* 2016; 65(4): 224-231.
11. Takami H, Ito Y, Okamoto T, et al. Therapeutic strategy for differentiated thyroid carcinoma in Japan based on a newly established guideline managed by Japanese Society of Thyroid Surgeons and Japanese Association of Endocrine Surgeons. *World J Surg* 2011; 35(1): 111-121.
12. Carling T, Carty SE, Ciarleglio MM, et al. American thyroid association design and feasibility of a prospective randomized controlled trial of prophylactic central lymph node dissection for papillary thyroid carcinoma. *Thyroid* 2012; 22(3): 237-243.
13. Esnaola NF, Cantor SB, Sherman SI, et al. Optimal treatment strategy in patients with papillary thyroid cancer: a decision analysis. *Surgery* 2001; 130(6): 921-930.
14. Guevara N, Lassalle S, Benaim G, et al. Role of frozen section analysis in nodular thyroid pathology. *Eur Ann Otorhinolaryngol Head Neck Dis* 2015; 132(2): 67-70.
15. Cairncross L, Panieri E. Pre-operative diagnosis of thyroid cancer: clinical, radiological and pathological correlation. *S Afr J Surg* 2013; 51(2): 46-49.
16. Ito Y, Urano T, Nakano K, et al. An observation trial without surgical treatment in patients with papillary microcarcinoma of the thyroid. *Thyroid* 2003; 13(4): 381-387.

Aberrant Cutaneous Nerve Loops in the Axilla

Vishwajit Ravindra Deshmukh, Harshita Bhardwaj, Feroz Khan, Tony George Jacob*

ABSTRACT

During routine dissection classes, conducted for first year undergraduate medical students, we encountered a rare anatomical variation in relation to the intercostobrachial nerve (ICBN). The ICBN represents the lateral undivided cutaneous branch of second intercostal nerve. In this case, the ICBN formed nerve loops with branches of the lateral cutaneous branch of the third intercostal nerve. These loops eventually gave branches that probably supplied the floor of the axilla and proximal arm. Nowadays, this ICBN is gaining clinical importance during the axillary lymph node dissections and mammary gland surgeries. Damage to the ICBN, may results in the sensory deficits in patients undergoing surgery. In our case report, ICBN was making aberrant nerve loop along with the branches from the third intercostal nerve. Knowledge regarding the origin, formation and route of ICBN is of clinical significance to axillary surgeons, radiologist and anesthesiologists.

KEYWORDS

axilla; lymph node; nerve plexus; intercostobrachial nerve; surgery

AUTHOR AFFILIATIONS

Department of Anatomy, All India Institute of Medical Sciences, New Delhi, India

* Corresponding author: Room no. 55, Ground floor, Department of Anatomy, All India Institute of Medical Sciences, New Delhi, India; e-mail: tonygeorgejacob@gmail.com

Received: 5 January 2017

Accepted: 7 April 2017

Published online: 7 June 2017

Acta Medica (Hradec Králové) 2017; 60(1): 51–54

<https://doi.org/10.14712/18059694.2017.50>

© 2017 The Authors. This is an open-access article distributed under the terms of the Creative Commons Attribution License (<http://creativecommons.org/licenses/by/4.0>), which permits unrestricted use, distribution, and reproduction in any medium, provided the original author and source are credited.

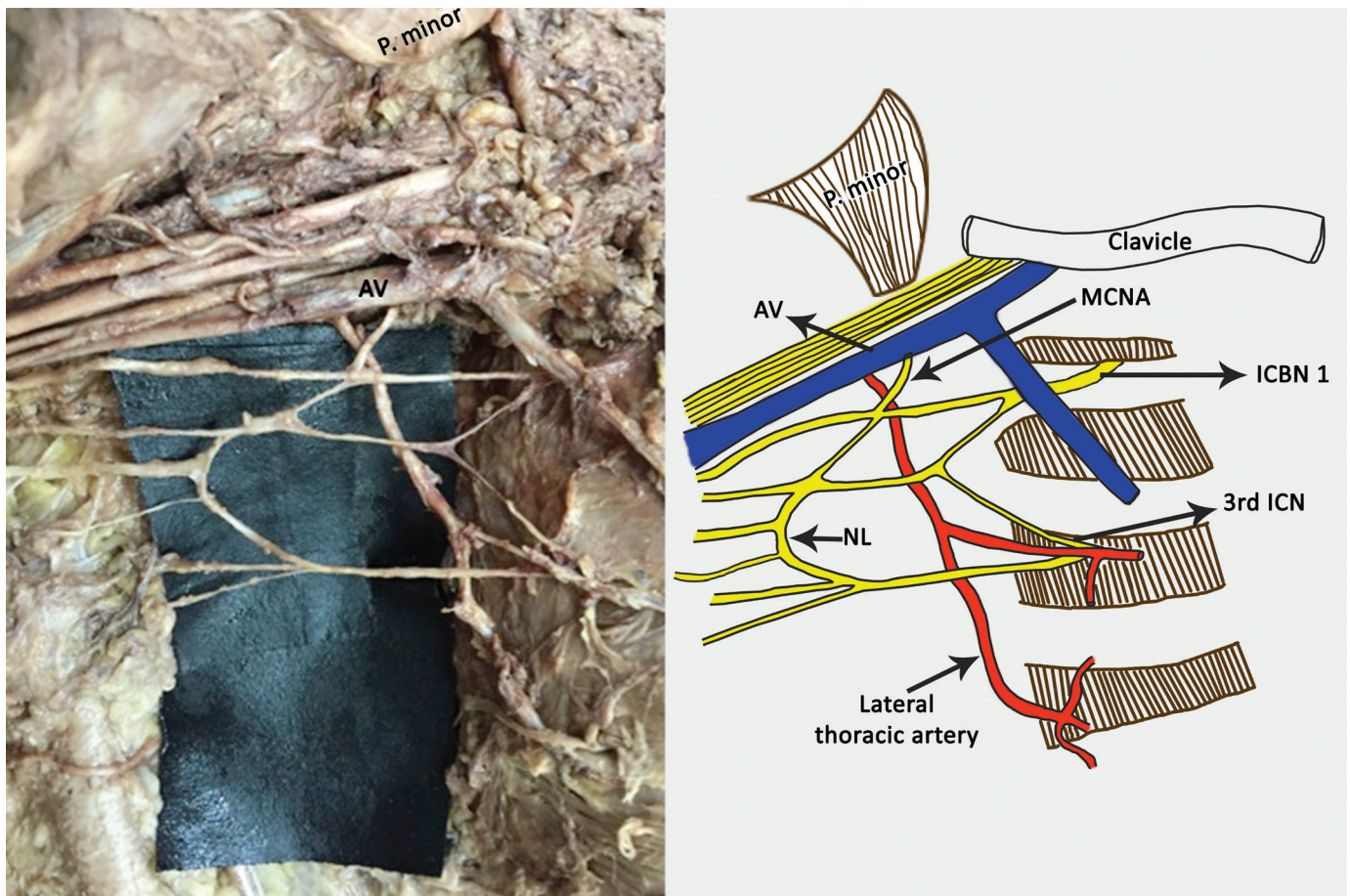


Fig. 1: Photograph showing the formation of nerve loop from the ICBN and third intercostal nerve. Along with nerve loop, branch of lateral thoracic artery is passing between the two-nerve roots of third intercostal nerve (3rd ICN). MCNA: Medial cutaneous nerve of arm; ICBN 1: Intercostobrachial nerve 1; AV: Axillary vein; NL: Nerve loop; P. minor: Pectoralis minor.

INTRODUCTION

The axilla is a truncated space, forming the passage for neurovascular structures between the upper limb, neck, and thoracic cavity. Variations in the neurovascular structures in this region may affect the outcome of axillary surgeries such as sentinel node identification and biopsy as well as axillary node dissection during a mastectomy for malignancies of the breast (1).

The cords (lateral, medial and posterior) of the brachial plexus in the axilla can be identified with the help of their relative positions to the axillary artery. The three cords enter the axilla at the apex and are arranged, according to the names, around the second and third parts of the axillary artery. In relation to the first part of the artery, however, the lateral and posterior cords are lateral, and the medial cord lies posterior to the artery (2). The lateral cutaneous branch of the second intercostal nerve is termed as the intercostobrachial nerve (ICBN) and can be identified easily because it emerges from the second intercostal space near the mid-axillary line (midway between the anterior and posterior axillary folds) (3). The ICBN is nearly parallel to the axillary vein, at a distance of about 1.5 centimeters (4). The ICBN pierces the intercostal muscles of second intercostal space and serratus anterior muscle around the midaxillary line, crosses the axilla and finally joins with the medial cutaneous nerve of the arm (MCNA). When the

nerve passes through the axilla, it gives off the posterior axillary branch, which innervates the skin of the posterior axillary fold. Thereafter, it gives sensory innervations to the skin of upper half of medial and posterior part of the arm (up to the apex of axilla), where it joins with the posterior cutaneous nerve of the arm, which is a branch of the radial nerve (5). Knowledge of the origin of ICBN and its branching pattern is necessary to avoid injury to it during axillary node dissection and mastectomy procedures. There is a paucity of information in published literature regarding the route, location, branching pattern and formation of a plexus or nerve loops in the axilla.

Axillary lymphadenectomy is done for sentinel lymph node identification in mammary gland malignancies or as a component of surgical treatment offered to patients with breast cancers or suspected cancers (6). Post-surgical morbidities in axillary node dissection are restricted mobility of shoulder and arm, sensory changes, pain, and lymphedema. It is reported that in patients with breast cancer, even a sentinel lymph node biopsy can result in the chronic sequelae, such as limitation in arm abduction (0–41.4%), pain (5.6–51.1%), paresthesia (5.1–51.1%) and lymphedema (0–27.3%) (7). These result from accidental harm to nerves, arteries and lymph vessels, respectively. Preservation of nerves during surgery can significantly decrease alterations of pain sensitivity in the arm after surgery (8).

Therefore, in this case report, we present a peculiar pattern of formation and distribution of the ICBN that may add to the body of literature and may alert axillary surgeons about possible variations to beware of to reduce the chronic sequelae of nerve injury in their patients.

CASE REPORT

During routine dissection of the axilla, we encountered the variation of ICBN in right upper limb of a female cadaver, who was 60 years of age at her time of death. The donor had died of natural causes. The cadaver had no visible signs of trauma, surgery or other pathological lesions in the neck, axilla, and thorax. Here, the ICBN after piercing intercostal muscles and serratus anterior muscle, bifurcated into two branches. The larger of the two branches joined with the medial cutaneous nerve of the arm and continued posteriorly towards the axilla, where it probably ended by supplying the skin of the posterior part of the arm. It did not have any branches innervating muscles of the region. The smaller branch of the ICBN joined the lateral cutaneous branch of the third intercostal nerve arising from the 3rd intercostal space in the mid-axillary line and formed a proximal nerve loop (Figure 1). A distal nerve loop was also formed between the larger and smaller branches of the ICBN and the lateral cutaneous branch of the third intercostal nerve. This distal nerve loop was found in the axilla and this loop gave off five branches that probably innervated the skin of the floor of the axilla and the upper medial part of the arm. None of the dissected branches of the loop or the parent nerves entered any of the muscles surrounding the axilla. The lateral thoracic artery passed deep to the nerve loops in the axilla, but a branch from this artery passed beside the roots of the lateral cutaneous branch of the third intercostal nerve.

DISCUSSION

Here, we report the formation of aberrant nerve loops and their branches between the lateral cutaneous branches of the second and third intercostal nerves in the axilla. The intercostobrachial nerve is an undivided lateral cutaneous branch of the second intercostal nerve (3). Cunnick grouped the anatomical variation of this nerve into various subcategories: in type 1 the ICBN arises from T2 and does not give off any branches; type 2 arises from T2 alone and divides into a large main trunk and a much smaller branch; in type 3 the ICBN arises from T2 alone and then divides equally into two branches; in type 4 the ICBN is formed by two equally sized branches from the T1 and T2 nerves; in type 5 the nerve arises from two separate T2 radicals to form a single nerve, which does not give off any branches in the axilla and lastly in type 6 it arises from T2 alone and is divided into the large main trunk and at least two smaller branches. The ICBN innervates the skin of the medial and posterior part of the arm and also communicates with the medial cutaneous nerve of the arm (MCNA) (9).

Breast cancer is the most common diagnosed malignancy in women worldwide (22%) and in India (18.5%) it

ranks second to cervical cancer (10). The ICBN is closely related to axillary lymph nodes, which are traditionally divided into three levels (I, II, III) by pectoralis minor muscle. Nowadays, it is commonly accepted principle that during surgery, lymph node should be extracted from level I to level III (11). Anatomy of the ICBN is highly variable and it divides the axillary space into lower and upper compartments. The upper compartment includes level III and a large part of level II lymph nodes. ICBN is commonly injured during surgeries of the mammary gland and axilla and recent studies have been mainly focused on preservation of ICBN during breast and axillary surgeries (12). According to the observation by Li J et al, if the axillary lymph nodes lying above the ICBN have micro or macrometastasis then there were metastasis positive nodes under the ICBN and similarly, if no metastasis is seen in lymph nodes under the ICBN, the upper nodes were also metastasis-free. Thus, ICBN forms the good anatomical landmark to define the axillary lymph node dissection procedure (13). Preservation of ICBN is beneficial to the patient because this leads to a significant decrease in pain sensitivity of the arm, without increasing the duration of the operation or the occurrence of relapses (14, 15). Some studies reported that preservation of ICBN consumes much time during mammary gland surgery but in the postoperative period there is the significant decrease in patients sensory deficits and pain (16). In addition, in patients with ICBN Neuralgia, anaesthetists have started using ultrasound guided nerve blocks in the subpectoral plane. Aberrant branching patterns would affect the outcome of these procedures that bring relief to the patient (17).

The embryological basis for the formation of aberrant nerve plexus is not fully understood. Various theories have been proposed including the cell signaling. During the fifth week of development, the axons of nerves grow distally to initiate contact with developing limb bud, improper signaling can lead to the formation of aberrant nerve plexus (18). The factors which guide the nerve growth are chemo-attractants (netrins) and repellents (semaphorins and ephrins) which ultimately direct cell processes for appropriate location (19). Another theory includes the improper balance of calcium, which is required for the guidance molecule to work effectively and also to stabilize the microtubules. Microtubule misalignment initiates the development of nerve in the new direction forming the aberrant nerve plexus of the body (20).

This anomaly that we have reported here, has not been mentioned before in literature, even in the studies dedicated to the anatomy of the ICBN. We believe that knowledge of this anomaly may be important to a surgeon during dissection of the axilla and would decrease post-operative morbidity for the patient.

REFERENCES

1. Rao R, Euhus D, Mayo HG, Balch C. Axillary node interventions in breast cancer: a systematic review. *Journal of American Medical Association* 2013; 310(13): 1385-94.
2. Wildsmith JAW, Armitage EN, McClure JH. *Principles and Practice of Regional Anaesthesia*. 3rd ed. New York, USA: Churchill Livingstone, 2003.
3. McMinn RM. Upper limb. In: McMinn RM, editor. *Last's Anatomy Regional and Applied*. 9th ed. Edinburgh: Churchill Livingstone, 1994: 82.

4. Loukas M, Hullett J, Louis RG, Holdman S, Holdman D. The gross anatomy of the extrathoracic course of the intercostobrachial nerve. *Clinical Anatomy* 2006; 19(2): 106-11.
5. Baker RJ, Fischer JE. Segmental mastectomy and axillary dissection. In: Baker RJ, Fischer JE, eds. *Master of Surgery*. Philadelphia: Lippincott, Williams and Wilkins, 2001; 591-3.
6. Soares EW, Nagai HM, Bredt LC, da Cunha AD, Andrade RJ, Soares GV. Morbidity after conventional dissection of axillary lymph nodes in breast cancer patients. *World Journal of Surgical Oncology* 2014; 12(1): 1.
7. Verbelen H, Gebruers N, Eeckhout FM, Verlinden K, Tjalma W. Shoulder and arm morbidity in sentinel node-negative breast cancer patients: a systematic review. *Breast Cancer Research and Treatment* 2014; 144(1): 21-31.
8. Carpenter JS, Sloan P, Andrykowski MA, McGrath P, Sloan D, Rexford T, Kenady D. Risk factors for pain after mastectomy/lumpectomy. *Cancer Practice* 1999; 7(2): 66-70.
9. Cunnick GH, Upponi S, Wishart GC. Anatomical variants of the intercostobrachial nerve encountered during axillary dissection. *The Breast* 2001; 10(2): 160-2.
10. Kamath R, Mahajan KS, Ashok L, Sanal TS. A study on risk factors of breast cancer among patients attending the tertiary care hospital, in udupi district. *Indian Journal of Community Medicine* 2013; 38(2): 95.
11. Masuda N, Tamaki Y, Noguchi S. Management of axillary and internal mammary lymph nodes in primary breast cancer. *Nihon Geka Gakkai Zasshi* 2001; 102(6): 465-72.
12. Pain SJ, Vowler S, Purushotham AD. Axillary vein abnormalities contribute to development of lymphoedema after surgery for breast cancer. *British Journal of Surgery* 2005; 92(3): 311-5.
13. Li J, Zhang Y, Zhang W, Jia S, Gu X, Ma Y, Li D. Intercostobrachial nerves as a novel anatomic landmark for dividing the axillary space in lymph node dissection. *ISRN Oncology* 2013; 2013.
14. Torresan RZ, Cabello C, Conde DM, Brenelli HB. Impact of the preservation of the intercostobrachial nerve in axillary lymphadenectomy due to breast cancer. *The Breast Journal* 2003; 9(5): 389-92.
15. Seidel R, Gray AT, Wree A, Schulze M. Surgery of the axilla with combined brachial plexus and intercostobrachial nerve block in subpectoral intercostal plane. *British Journal of Anaesthesia* 2017; 118(3):472-4.
16. Freeman SR, Washington SJ, Pritchard T, Barr L, Baildam AD, Bundred NJ. Long term results of a randomised prospective study of preservation of the intercostobrachial nerve. *European Journal of Surgical Oncology* 2003; 29(3): 213-5.
17. Wisotzky EM, Saini V, Kao C. Ultrasound-guided intercostobrachial nerve block for intercostobrachial neuralgia in breast cancer patients: a case series. *Physical Medicine and Rehabilitation* 2016; 8(3):273-7.
18. Tatar I, Brohi R, Sen F, Tonak A, Celik H. Innervation of the coracobrachialis muscle by a branch from the lateral root of the median nerve. *Folia Morphol (Warsz)* 2004; 63(4): 503-6.
19. Budhiraja V, Rastogi R, Asthana AK, Sinha P, Krishna A, Trivedi V. Concurrent variations of median and musculocutaneous nerves and their clinical correlation-a cadaveric study. *Italian Journal of Anatomy and Embryology* 2011; 116(2): 67.
20. Schoenwolf GC, Bleyl SB, Brauer PR, Francis-west PH. Development of the peripheral nervous system. In: Schoenwolf GC, Editor. *Larsen's Human Embryology*. Philadelphia.

Familial Adenomatous Polyposis Registry in Czech Republic – History, Present and Future

Jiří Cyrany*

KEYWORDS

familial adenomatous polyposis; registry

AUTHOR AFFILIATIONS

2nd Department of Internal Medicine – Gastroenterology, Charles University, Medical Faculty and University Hospital Hradec Králové, Czech Republic

* Corresponding author: 2nd Department of Internal Medicine – Gastroenterology, University Hospital Hradec Králové, Sokolská 581, 50005 Hradec Králové; e-mail: jiri.cyrany@fnhk.cz

Received: 21 December 2016

Accepted: 25 April 2017

Published online: 7 June 2017

Acta Medica (Hradec Králové) 2017; 60(1): 55–57

<https://doi.org/10.14712/18059694.2017.51>

© 2017 The Author. This is an open-access article distributed under the terms of the Creative Commons Attribution License (<http://creativecommons.org/licenses/by/4.0>), which permits unrestricted use, distribution, and reproduction in any medium, provided the original author and source are credited.

FAMILIAL ADENOMATOUS POLYPOSIS – INTRODUCTION

Familial adenomatous polyposis (FAP) is a hereditary neoplastic syndrome caused by mutation in genes APC (adenomatous polyposis coli) or MUTYH (mutY DNA glykosylase) – numerous colorectal adenomas are the main phenotypic feature. Although the disease is responsible for less than 1% of colorectal cancer cases in overall population, affected individual is exposed to almost absolute risk of colorectal cancer and various extracolonic neoplasias and other manifestations, frequently in young age. Prophylactic colectomy remains the only way to reduce mortality for colorectal cancer, despite some effect of chemoprophylaxis (e.g. coxibs). The person must undergo lifelong follow-up including endoscopic examinations to control risk of extracolonic malignancies, especially duodenal and desmoid tumours. Disease and/or prophylactic operation have a significant impact on patient's quality of life. Affected individual and his/her families need specialized care based on interdisciplinary cooperation organized within regional, national and international networks.

HISTORY AND SIGNIFICANCE OF FAP REGISTRATION

First FAP register was founded in St. Mark's hospital, London by pathologist Cuthbert Dukes, surgeon J. P. Lockhart-Mummery and assistant H. J. R. Bussey (1). According to systematic review of studies, registration and screening result in reduction of colorectal cancer incidence and mortality in patients with FAP (and Lynch syndrome) (2). FAP registries provide many additional benefits: organisational, patient-focused and research-focused. Majority of western countries runs its own FAP registries. InSiGHT (International Society for Gastrointestinal Hereditary Tumours) currently covers these activities on international bases (3).

HISTORY OF FAP REGISTRATION IN CZECH REPUBLIC

Assoc. prof. Václav Jirásek is the highly recognized nestor of FAP registration in Czech Republic and ran FAP register in General University Hospital in Prague for ages. Formal working group for FAP in Czech Republic was founded in May 2006 by prof. Milan Lukáš and Aleš Novotný, M.D. The working group consisted from predominantly gastroenterologists, but also surgeons, pathologists and geneticists. Network of 11 centres was established. FAP register was prepared by this group and opened at the beginning of 2008 – more than 80 polyposis cases were enrolled altogether, although only one centre was active since 2011 – 45 polyposis cases were registered till the end of 2015 from this centre in Faculty hospital in Hradec Králové. Members of FAP working group regularly presented papers on national congresses: Hereditary colorectal cancer (Beskydy endoscopic workshop, Frýdek-Místek 2007), Extracolonic

manifestations of FAP (National congress of gastroenterology, Brno 2008; Clinical cases in gastroenterology, Praha 2009; Congress of Czech society of gastroenterology, Praha 2009; Brno oncologic days, Brno 2010), FAP registries (Hradec gastroenterology and hepatology days, Hradec Králové 2009), FAP registry – single centre results (Hradec gastroenterology and hepatology days, Hradec Králové 2016). Single centre results from FAP register concerning duodenal involvement were presented at Digestive disease week in USA in 2010(4). FAP working group organized several symposiums dedicated to hereditary gastrointestinal cancers (Hereditary cancer syndromes, Educational and discussion days, Karlovy Vary 2010; FAP – indication for colectomy as an interdisciplinary task, Hradec gastroenterology and hepatology days, Hradec Králové 2014; Hereditary cancers of gastrointestinal tract, National congress of gastroenterology, Praha 2015).

Educational activities towards patients and their families were an additional task of the working group: Instruction leaflet for patients and their families were prepared in 2010 by Assoc. prof. Václav Jirásek and geneticist Jaroslav Kotlas, M.D. (5). Web pages with internet discussion forum for patients ran since 2010 on www.polyposy.cz (6).

PRESENT AND FUTURE OF FAP REGISTRATION IN CZECH REPUBLIC

Presentation of single centre results on abovementioned national gastroenterology meetings in 2015–16 represented the maximum achievable with existing register format with limited participation. Thus when Ministry of Health of Czech Republic announced National action plan for rare diseases, we claimed for this grant on the platform of Czech Society of Gastroenterology as a part of Czech Medical Association of J. E. Purkyně. Priority 3b of the Developing project is dedicated to generation and run of registries of rare diseases. Administration of the database came back under the wings of Institute of Biostatistics and Analysis of Masaryk University (IBA spin-off), which is the major provider of database medical services in Czech Republic. Primary network was formed by 5 centres involved in care of FAP patients (Military University Hospital Prague, General University Hospital Prague, ISCARE centre Prague, Masaryk Memorial Cancer Institute Brno and Faculty hospital Hradec Králové). Resources were definitely allocated in August 2016 and enabled to innovate existing database structure, tune the online interface with active participation of all engaged centres. Simultaneously we applied for the same grant for 2017. Our long-term goal is sustainable cooperation within current platform, which will be able to run register and thus to fulfil all clinical tasks of registration process including generation of adequate long-term results.

ACKNOWLEDGEMENTS

Supported by Ministry of Health of Czech Republic: Database for register of FAP No. OZS/42/4142/2016.

REFERENCES

1. Bulow S, Berk T, Neale K. The history of familial adenomatous polyposis. *Fam Cancer* 2006; 5(3): 213–20.
2. Barrow P, Khan M, Lalloo F, Evans DG, Hill J. Systematic review of the impact of registration and screening on colorectal cancer incidence and mortality in familial adenomatous polyposis and Lynch syndrome. *Br J Surg* 2013 Dec; 100(13): 1719–31.
3. InSiGHT. International society for gastrointestinal hereditary tumours. [cited 2016 Dec 15]; Available from: <https://www.insight-group.org>.
4. Cyrany J, Rejchrt S, Kopacova M, Tycova V, Bures J. W1602: Duodenal adenomatosis in patients with familial adenomatous polyposis – endoscopic diagnosis and therapy. *Gastrointest Endosc* 2010; 71(5): AB369–70.
5. Jirasek V, Kotlas J. Desatero pro pacienty s FAP [cited 2016 Dec 15]: Available from: <http://www.kolonoskopie.cz/odborne/desatero-pro-pacienty-s-fap.aspx>.
6. Cyrany J. Diskuse na téma FAP. [cited 2016 Dec 15]; Available from: <http://www.kolonoskopie.cz/poradna-pro-pacienty/diskuse-na-tema-fap>.

