

Mixed Infections (Mucormycosis, Actinomycosis and Candidiasis) Leading to Maxillary Osteomyelitis in a Diabetic Mellitus Patient in Post COVID Phase: First Case Report

Manveen Kaur Jawanda¹, Ravi Narula², Sonia Gupta^{3,*}, Vineet Sharma⁴,
Supreet Kaur Sidhu⁵, Navneet Kaur⁶

ABSTRACT

Background: The second wave of COVID-19 has emerged with the addition of vivid types of oral manifestations. Immunosuppression caused by COVID-19 results in an exacerbation of pre-existing infections. Recently, in the backdrop of COVID-19 expression, a notable rise in the incidence of secondary infections, both fungal and bacterial, have been reported either during the disease or as a post-COVID manifestation.

Case presentation: A 70-year-old male diabetic COVID-19 patient reported with a chief complaint of pain in the right side maxillary region for 3 months and the passage of content from the oral cavity into the nose. Intraoral examination revealed missing teeth i.r.t. 12 to 17, denuded mucosa with exposed necrotic bone and an oroantral opening. Sequestrectomy was done and the tissue was sent for histopathological examination which revealed necrotic bone interspersed with broad aseptate fungal hyphae branched at right angles along with actinomycotic colonies and Candidal hyphae in few areas. Based on histopathological findings, a final diagnosis of mixed infections leading to Maxillary Osteomyelitis was given. No recurrence was noticed after 3 months of follow up.

Conclusions: The occurrence of oral infections even after the remission period of COVID-19 signifies an alarming sign both for the patient and clinicians monitoring the oral health status during the follow-up period. To our knowledge, this is the first such case (three oral infections as a post covid manifestation in a single diabetic patient) reported in the literature till date.

KEYWORDS

actinomycosis; candidiasis; COVID; diabetes; mucormycosis; osteomyelitis

AUTHOR AFFILIATIONS

¹ Department of Oral Pathology & Microbiology and Forensic Odontology, Luxmi bai institute of dental sciences and hospital, Patiala, Punjab, India

² Department of Oral and Maxillofacial Surgery, Guru Nanak Dev Dental College and Research Institute, Sunam, Punjab, India

³ Department of Oral Pathology and Microbiology & Forensic Odontology, Rayat and Bahra Dental college and hospital, Mohali, Punjab, India

⁴ Department of Conservative Dentistry, Luxmi bai institute of dental sciences and hospital, Patiala, Punjab, India

⁵ Department of Oral Pathology and Microbiology & Forensic Odontology, Luxmi Bai Institute of Dental Sciences and Hospital, Patiala, Punjab, India

⁶ Department of Oral Pathology and Microbiology & Forensic Odontology, Luxmi Bai Institute of Dental Sciences and Hospital, Patiala, Punjab, India

* Corresponding author: Department of Oral Pathology and Microbiology & Forensic Odontology, Rayat and Bahra Dental college and hospital, Mohali, Punjab, India; e-mail: Sonia.4840@gmail.com

Received: 16 August 2021

Accepted: 19 October 2021

Published online: 4 March 2022

Acta Medica (Hradec Králové) 2021; 64(4): 218–223

<https://doi.org/10.14712/18059694.2022.5>

© 2021 The Authors. This is an open-access article distributed under the terms of the Creative Commons Attribution License (<http://creativecommons.org/licenses/by/4.0>), which permits unrestricted use, distribution, and reproduction in any medium, provided the original author and source are credited.

ABBREVIATIONS

ACE: Angiotensin convertase enzyme, AIDS: Acquired immunodeficiency syndrome, CMV: Cytomegalovirus, CNS: Central nervous system, COVID: Coronavirus infectious disease, DM: Diabetes mellitus, H&E: Hematoxylin & eosin, HIV: Human immunodeficiency virus, HT: Hypertension, ICU: intensive care unit, IL: interleukin, PAS: periodic acid Schiff, PNS: paranasal sinus, TNF: Tumour necrosis factor.

INTRODUCTION

The coronavirus infectious disease-19 (COVID-19) caused by Severe acute respiratory syndrome- coronavirus-2 (SARS-CoV2) has emerged to be a lethal viral infection resulting in high morbidity. Although the remarkable presentation of this disease is respiratory symptoms, its clinical features reported are not considered to be highly specific. With the spread of COVID-19, the signs and symptoms of this disease have varied from patient to patient. This is a contagious disease that puts patients with underlying comorbidities such as diabetes mellitus (DM), hypertension (HT), obesity, old age, trauma, organ transplant, hematopoietic malignancies, or any cardiac or renal disorder, at higher risk (2).

Studies on SARS-CoV and SARS-CoV-2 have shown that both viruses belong to the same species and have similar biological and clinical characteristics (3). It has been observed in previous studies that microbial infections were very frequent in SARS patients as a leading cause of death in 25–73.7% cases (4). These results signify an alarming sign for the clinicians to pay attention to the probability of secondary infections accompanying COVID-19 disease. Recently, in the backdrop of COVID-19 expression, a notable rise in the incidence of both fungal and bacterial infections have been reported either during the disease or in post-COVID phase (5–7). Association of uncontrolled DM, SARS-COV2 and secondary infections predominantly mucormycosis has been reported by various researchers in the literature (8). Here we represent a case of a DM patient with mixed infections (mucormycosis, actinomycosis and candidiasis) leading to maxillary osteomyelitis as a post COVID sequelae. To our knowledge, this is the first such case (three infections as a post covid manifestation in a single DM patient) reported in the literature till date.

CASE REPORT

A 70-year-old male patient reported with a chief complaint of pain in the right side maxillary region for 3 months and the passage of content from the oral cavity into the nose. The patient had been a known case of type II DM for last 20 years and was currently taking oral hypoglycaemics (Metformin, 1000 mg BD; before breakfast and dinner). He was non-smoker, non-alcoholic without any allergic history. The patient suffered from fever 4 months ago and was diagnosed with COVID-19 infection. During his treatment for COVID-19, he was administered steroids along with a cocktail of other drugs (Ivermectin, Remdesvir,

and Tocilizumab). After hospital discharge, he presented with the complaint of pain and noticed denuded bone over the right maxillary alveolar ridge region. On general examination, he was moderately built, with normal gait and posture and well-oriented to the time, place and surroundings. His vital signs were normal. An intraoral examination revealed missing teeth i.r.t. 12 to 17, denuded mucosa with exposed necrotic yellow-coloured bone extending from the distal aspect of right maxillary central incisor to the right side of the posterior maxillary tuberosity region (Figure 1A), and an oroantral opening was noticed on the palatal side of the necrotic alveolar bone. On palpation, the affected area was rough in texture with mild tenderness. The paranasal sinus (PNS) view showed haziness in the right maxillary sinus (Figure 1B). Based on history, clinical and radiographic findings, a provisional diagnosis of Osteomyelitis of the maxilla secondary to Mucormycosis was given. Other differential diagnoses included deep fungal infections, malignant neoplasms, etc. Sequestrectomy was planned as further management. Before operating,

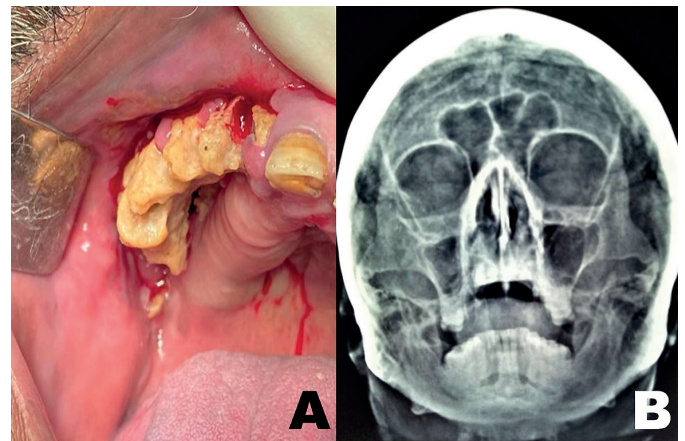


Fig. 1 A) Clinical photograph showing necrotic denuded bone; B) Paranasal sinus radiograph showing haziness of right maxillary sinus.

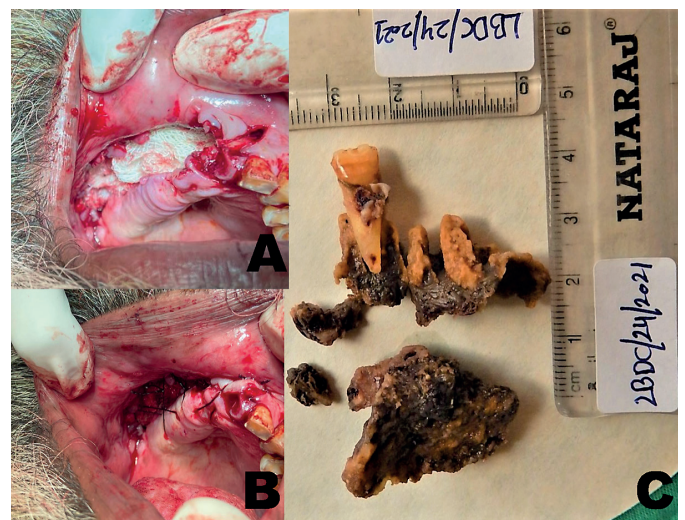

Fig. 2 A) Intraoperative photograph of resection of dead dentoalveolar right maxillary segment; B) Primary closure of incision site after resection; C) Photograph of gross excisional bony sequestrum showing blackish fungal colonies on the necrotic bone.

his blood sugar level was checked. His fasting blood sugar was 90 mg/dl on the day of surgery. His glycaemic index reported was 7.1. Routine blood tests were normal. Sequestrectomy (Figure 2A and 2B) was done for the dead right maxillary dentoalveolar segment along with curettage for the right maxillary antrum and nasal floor (Figure 2C), and the tissue was sent for histopathological examination. The Haematoxylin and eosin (H&E) stained sections revealed necrotic bone interspersed with fungal hyphae. These hyphae were broad aseptate with branching at right angles. Special staining with periodic acid Schiff (PAS) showed numerous magenta pink coloured non-septate fungal hyphae showing branching at 90° (Figure 3A and 3B). Further, necrotic bone showed sclerosis with actinomycotic colonies (Figure 4A and 4B), exhibiting club shaped filaments arranged in a radiating rosette pattern within the necrotic tissue and trabecular surface. On the surface of dead bone, candidal hyphae were also seen in a few areas

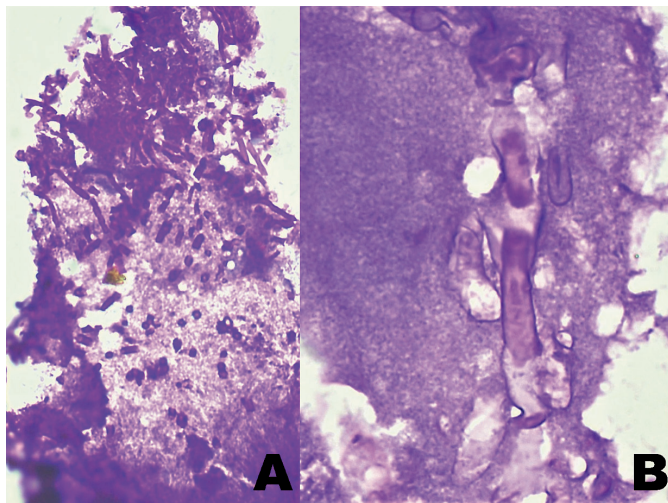


Fig. 3 A) Photomicrograph showing magenta pink colored Aseptate broad fungal hyphae (PAS stain, 100×); B) (PAS, 400×).

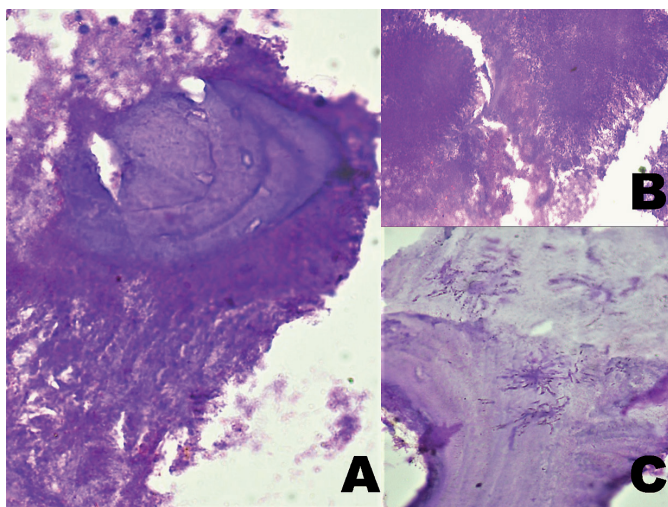


Fig. 4 A) Dead bone with Actinomycotic colonies on trabecular surface of bony spicules (PAS, 400×); B) Actinomycotic colonies exhibiting club shaped filaments arranged in a radiating rosette pattern in the necrotic tissue (H&E stain, 400×); C) Candidal Hyphae on the surface of necrotic bone (PAS, 100×).

(Figure 4C). Based on histopathological findings, a final diagnosis of mixed infections (Mucormycosis (BLACK FUNGUS), Actinomycosis (YELLOW FUNGUS), along with Candidiasis (WHITE FUNGUS) leading to Maxillary Osteomyelitis was given. The patient was asked to keep his sugar under control and was administered Posaconazole (400 mg BD × 3 months) along with oral Clindamycin (300 mg TID × 6 weeks). The patient was referred to the prosthetic department for an obturator, but the patient declined for it. The patient appears to be in remission and no recurrence was noticed after 3 months of follow-up.

DISCUSSION

It has been suggested that COVID-19 infection is associated with a marked reduction in CD4+ T cells, CD8+ T cells, B cells, NK cells along with lymphocytes, monocytes, and eosinophils and increase in neutrophil count, pro-inflammatory markers, such as interleukin (IL)-1, IL-6, and tumour necrosis factor alpha (TNF- α). Also, there is an overactivation of T cells caused due to an increased level of Th17 and over cytotoxicity of CD8+ T cells. Thus, overall leading to immunosuppression and increased susceptibility to infections (9). Meanwhile, the SARS-CoV2, can damage airway tissue and blood vessels, putting people at a higher risk of secondary infections (10). Also, SARS-CoV2 has been found to have an increased affinity for angiotensin convertase enzyme-2 (ACE-2) receptors (11). These receptors have also been reported in the oral mucosa making the oral mucosa as a portal for the virus entry. Existence of ACE-2 receptors in the epithelial cells of the salivary glands leads to dry mouth or xerostomia that might predispose the individual to develop various oral infections (12).

Mucormycosis/Zygomycosis is a rare but lethal fungal infection caused by fungi (Mucor, Rhizopus, Lichtheimia, Cunninghamella) belonging to mucormycetes family. The mould is ubiquitous, growing in soil, plants, manure, and decayed matter. The fungus is non-pathogenic in immunocompetent individuals. However, in immunocompromised individuals like DM, organ transplantation, Human-immunodeficiency virus / Acquired immunodeficiency syndrome (HIV/ AIDS), corticosteroid therapy, malignancy, burns, trauma etc, it becomes pathogenic resulting in an invasive infection. Main route of infection is through spore inhalation that results in germination of spores in the nasal cavity and spreads to PNS further invading the palate, orbits and brain, often leading to death. The fungus exhibits a remarkable affinity for arteries forming thrombi within the blood vessels resulting in reduction of blood supply leading to tissue necrosis. In DM patients with ketoacidosis, the binding of iron to transferrin is inhibited and results in elevated iron levels, which promotes the growth of mucormycosis (13). Six common subtypes of mucormycosis are; rhino cerebral, pulmonary, gastrointestinal, involving Central nervous system (CNS) and disseminated. Oral mucormycosis mainly involves PNS, nose and palate. Symptoms include headache, fever, lethargy, painful eyes, nasal or sinus congestion, ophthalmoplegia, meningoencephalitis, proptosis, facial swelling, partial

loss of vision, coughing, shortening of breath, and altered mental status. In the oral cavity, the infection is manifested as necrotizing ulceration of palate, blackish slough formation and exposure of bone, tenderness over maxillary sinus area, tooth loss etc. Cases with oroantral opening have also been reported same as in our case (14). Diagnosis of mucormycosis includes imaging aids and histopathology. Histologically, mucormycosis is characterized by pathognomonic broad, non-septate hyphae with the branching at right angles. Both medication and surgical management strategies are employed in mucormycosis. Amphotericin B (liposomal) is the most commonly used drug. Combined therapy of amphotericin B and Posaconazole have shown synergistic effects against fungal hyphae formation.

Actinomycosis is a rare anaerobic bacterial infection caused by gram positive, non-motile, non-acid fast filamentous bacterial rod '*actinomyces Israeli*'. Clinically it is of three subtypes; cervicofacial, thoracic, and abdominal. Cervicofacial type is the most common. The infection is characterized by contagious spread, suppurative and granulomatous inflammation leading to multiple abscess formation and sinus tracts that may discharge sulphur granules. With the progression of disease, infection may invade jaws, gums, and internal organs like lung, heart, kidney, liver, appendix etc. When affecting the jaw, the disease is termed as 'lumpy jaw' (15). It manifests as fever, chills, painless/painful soft-tissue swelling in peri mandibular region and sinus formation leading to woody consistency of jaw resembling some malignancy. Infection may spread to adjacent bone and muscles too. In the jaw bone, it can result in osteomyelitis. Main contributory factors for the development of cervicofacial actinomycosis are; trauma to oral cavity, dental treatment undergone, poor oral hygiene, dental caries, periodontal disease, local tissue damage caused by neoplasm or radiation therapy. The infection is more susceptible to the immunocompromised patients same as of mucormycosis. Histopathologically, actinomycosis shows chronic granulomatous inflammation with central abscess formation demonstrating sulphur granules colonies of organisms that appear as round or oval basophilic masses with eosinophilic terminal "clubs" giving rise to ray fungus on H&E staining. But these granules are not always recovered in the cultured sections. And these are not specific to this infection and can be produced by other infections such as botryomycosis, chronomycosis too. Special stains such as Gram stain, Gomori methenamine silver (GMS), and Giemsa are used to demonstrate these granules (16). The management of the lesion includes drainage of pus, sinus tract excision, long term use of antibiotics such as Penicillin, Tetracycline and Erythromycin.

Candidiasis is the most commonly encountered opportunistic fungal infection in the oral cavity caused by yeast like fungi '*Candida albicans*'. The microbe is a common inhabitant of oral mucosa, which becomes pathogenic under certain immunocompromised conditions such as DM, malignancy, ingestion of chemotherapeutic drugs or steroids, HIV infection and Cytomegalovirus (CMV). Salivary gland infections, dentures, increased carbohydrate diet, smoking, old age, obesity, hyposalivation are other risk factors for oral candidiasis. Decreased secretion of antimicrobial

proteins are observed in individuals with hyposalivation which are related to decreased antifungal properties and may predispose the occurrence of oral candidiasis (17). *Candida auris* is found to be another emerging fungus that can have exerted outbreaks of severe infections in health-care facilities and units during COVID-19. Cases of candidiasis in COVID-19 have been reported in large number among the patients admitted to intensive care units (ICU). Researchers suspect that these outbreaks may be related to lack of routine infection control practices due to the health crisis such as insufficiency of gloves and gowns, possibility of faulty cleaning and disinfection (18). The diagnostic methods for oral candidiasis include exfoliative cytology, microbial culture, potassium peroxide staining, salivary assays, and oral mucosal biopsy. H&E stained sections may reveal the presence of candida hyphae. Special staining procedure such as PAS is helpful in definitive diagnosis. Candidiasis is a superficial fungal infection. But in the present case, the candidal hyphae were seen invading the deeper bony tissue, signifying an important finding. The management of candidiasis includes antifungal therapy; Nystatin used topically, Amphotericin B, Clotrimazole, Ketoconazole and Fluconazole used Systemically.

In the present case, clinical and radiographic features provided a provisional diagnosis of Osteomyelitis secondary to Mucormycosis. But when confirmed histologically, a final diagnosis of mixed infections (Mucormycosis, Actinomycosis and Candidiasis) leading to osteomyelitis was concluded. Osteomyelitis very rarely occurs in the maxilla due to its rich vascular supply, but some fungal infections such as mucormycosis can cause maxillary osteomyelitis. Contiguous spread of infection from surrounding soft tissue and bones due to hematogenous seeding or direct inoculation of microbes into bone results in the disease origin (19).

Management of such infections is done by providing antifungal and antibacterial agents. And in DM patients, the main factor of concern is the regulation of blood sugar to prevent the emergence of other secondary infections. Postoperatively, the present patient was instructed to monitor his sugar level and was administered Posaconazole along with oral Clindamycin. And no recurrence was noticed after months of follow up.

COVID-19 DM patients with secondary infections have been reported in the literature, but we could not find any such case documented till date in which three infections manifested in a single DM patient in the post-COVID phase. This makes the present case both interesting and rare.

Cases of secondary infections (especially fungal and bacterial) in COVID-19 patients are being notified to a great extent in India in comparison to other regions of the world. There may be various factors associated with this predominance, and the same can be contemplated for the present case also. However, evidence-based studies are still required.

1. Prolonged use of steroids leading to immunosuppression. It is hypothesized that steroids tend to reduce the inflammatory storm in this infection and also minimize the end organ damage. But, these drugs can cause immunosuppression and rise in blood sugar levels,

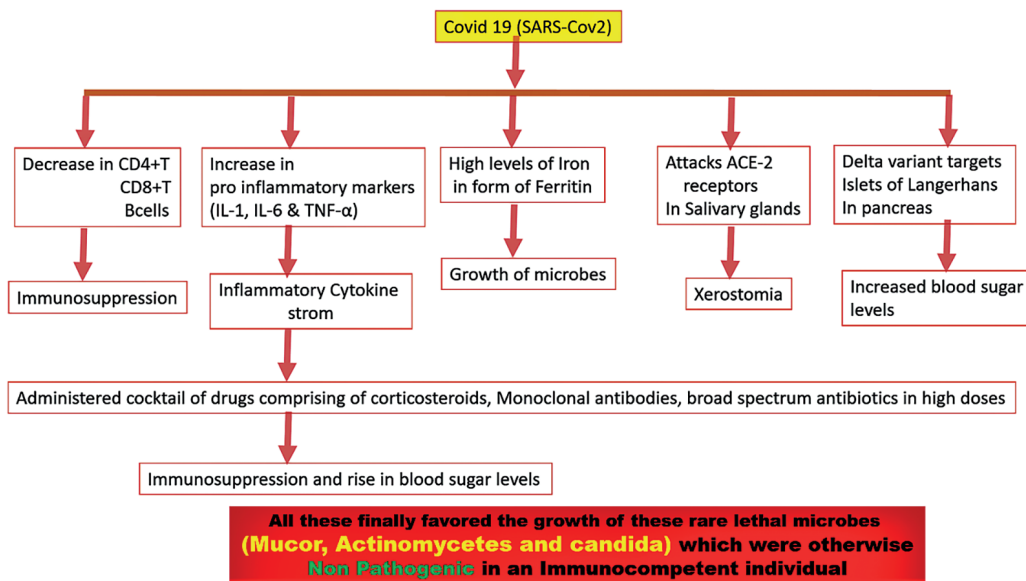


Fig. 5 Possible factors and mechanisms of developing secondary infections in diabetic patients as a post COVID sequelae.

- further resulting in secondary infections as a post COVID sequelae (13).
- SARS-CoV2 has the potential to damage blood vessels and airway tissues, leading to more infections.
 - During the peak of the second wave of COVID-19, there was an acute shortage of medical grade oxygen, hence hospitals had to shift to industrial oxygen. Although no major difference has been noticed in both types, there is a strong possibility of the use of contaminated accessories during inhalation of oxygen by patients.
 - Humidifiers like distilled water or tap water may also be suggested as one of the predisposing factors for associated infections.
 - A high level of iron in the form of ferritin is found in COVID-19 and DM patients, which is also favourable for the growth of secondary infections like mucormycosis.
 - Therapeutic administration of Zinc in India was prescribed on a large scale, which also favoured the growth of such microbial agents.

It is well understood that DM patients are more prone to infections. High blood sugar level act as milieu for the microbial growth dysregulating the glycaemic homeostasis (20). According to a recent data, India stands second amongst the top 10 countries in the world, with 77 million people with diabetes and another 36.5 million with prediabetes which is a high-risk condition for diabetes and cardiovascular disease (8). Diabetic patients are at more risk of developing COVID-19 disease, conversely Covid-19 infection can worsen diabetes control and some treatments used for COVID (e.g. steroids) can exacerbate hyperglycaemia. Figure 5 describes the possible factors and mechanisms resulting in secondary infections in diabetic patients.

In the present case, the patient had a history of DM, COVID-19 infection, hospitalisation along with widespread use of steroids, monoclonal antibodies, broad spectrum antibiotics as a part of the armamentarium against COVID-19. All of these factors might have created the perfect storm in which secondary infections took root and thrived. From the above discussion, it can be hypothesised

that the development of secondary infections in this patient in remission stage could be the result of multiple factors involved.

CONCLUSION

The second wave of COVID-19 has emerged with the addition of vivid types of oral manifestations. Immunosuppression caused by COVID-19 results in an exacerbation of pre-existing infections. While corticosteroids are considered to be life-saving in this pandemic, they have proved to be a double-edged sword and indiscriminate use has led to some deleterious results. Diabetes mellitus patients are already at a risk of developing vivid secondary oral infections. The occurrence of oral infections even after the remission period of COVID-19 signifies an alarming sign both for the patient and clinicians monitoring the oral health status during the follow-up period. Early diagnosis and treatment planning is mandatory to prevent further complications. The present case report of a DM patient with mixed infections (mucormycosis, actinomycosis, and candidiasis) in the post-COVID phase adds further important evidence of the increasing number of such cases during this lethal pandemic.

REFERENCES

- Amorim Dos Santos J, Normando AGC, Carvalho da Silva RL, et al. Oral Manifestations in Patients with COVID-19: A Living Systematic Review. *J Dent Res* 2021; 100(2): 141-54.
- Wolff D, Nee S, Hickey NS, Marscholke M. Risk factors for Covid-19 severity and fatality: a structured literature review. *Infection* 2021; 49(1): 15-28.
- Peeri NC, Shrestha N, Rahman MS, et al. The SARS, MERS and novel coronavirus (COVID-19) epidemics, the newest and biggest global health threats: what lessons have we learned? *Int J Epidemiol* 2020; 49(3): 717-26.
- Li CS, Pan SF. Analysis and causation discussion of 185 severe acute respiratory syndrome dead cases. *Zhongguo Wei Zhong Bing Ji Jiu Yi Xue* 2003; 15(10): 582-4. In Chinese.

5. Pathak K, Karadwal A, Nayak P, Nayak S. Mucormycosis in Post Covid Patient - A Case Report. *Indian J Forens Med Toxicol* 2021; 15(3): 240-4.
6. Setia A, Bhattacharya S. Mucormycosis and its implication in COVID-19. *Indian J Pharm Pharmacol* 2021; 8(2): 97-9.
7. Pauli MA, Pereira LM, Monteiro ML, de Camargo AR, Rabelo GD. Painful palatal lesion in a patient with COVID-19. *Oral Surg Oral Med Oral Pathol Oral Radiol* 2021; 131(6): 620-5.
8. Moorthy A, Gaikwad R, Krishna S, et al. SARS-CoV-2, uncontrolled diabetes and corticosteroids-An unholy trinity in invasive fungal infections of the maxillofacial Region? A Retrospective, Multi-centric Analysis. *J Maxillofac Oral Surg* 2021; 20(3): 1-8.
9. Xu Z, Shi L, Wang Y, Zhang J, et al. Pathological findings of COVID-19 associated with acute respiratory distress syndrome. *Lancet Respir Med* 2020; 8(4): 420-2.
10. Siddiqi HK, Libby P, Ridker PM. COVID-19 - A vascular disease. *Trends Cardiovasc Med* 2021; 31(1): 1-5.
11. Wan Y, Shang J, Graham R, Baric RS, Li F. Receptor recognition by the novel coronavirus from Wuhan: an Analysis based on decade-long structural studies of SARS coronavirus. *J Virol* 2020; 94(7): e00127-e220.
12. Xu H, Zhong L, Deng J, et al. High expression of ACE2 receptor of 2019-nCoV on the epithelial cells of oral mucosa. *Int J Oral Sci* 2020; 12(1): 8.
13. Hingad N, Kumar G, Deshmukh R. Oral mucormycosis causing necrotizing lesion in a diabetic patient: a case report. *Int J Oral Maxillofac Pathol* 2012; 3(3): 8-12.
14. Nilesh K, Malik NA, Belgaumi U. Mucormycosis in a healthy elderly patient presenting as oro-antral fistula: Report of a rare incidence. *J Clin Exp Dent* 2015; 7(2): e333-5.
15. Gupta V, Dwivedi G, Sengupta P, et al. A rare case of sinonasal actinomycosis - enigmatic presentation. *Int J Otorhinolaryngol Head and Neck Surg* 2020; 4(3): 863.
16. Moniruddin ABM, Begum H, Nahar K. Actinomycosis: An Update. *Medicine Today* 2010; 22(1): 43-7.
17. Paradowska-Stolarz AM. Oral manifestations of COVID-19: Brief review. *Dent Med Probl* 2021; 58(1): 123-6.
18. Prestel C, Anderson E, Forsberg K, et al. Candida Auris outbreak in a COVID-19 specialty care unit - Florida, July-August 2020. *Morbidity and Mortality Weekly Report* 2021; 70(2): 56-7.
19. Arani R, Afsar Shareef SNH, Khuthija Khanam HM. Mucormycotic Osteomyelitis Involving the Maxilla: A Rare Case Report and Review of the Literature. *Case Rep Infect Dis* 2019; 2019: 8459296.
20. Unnikrishnan R, Misra A. Infections and diabetes: risks and mitigation with reference to India. *Diab Metabol Syndr Clin Res Rev* 2020; 14: 1889-94.