

Progressive Worsening of Snoring as a Rare Presentation of HPV-Positive Oropharyngeal Squamous Cell Carcinoma

V Sha Kri Eh Dam¹, Azliana Aziz¹, Sarah Zulkarnain², Nur Asyilla Che Jalil², Irfan Mohamad^{1,*}

ABSTRACT

The incidence of oropharyngeal squamous cell carcinoma (OPSCC) especially human papillomavirus (HPV) associated type is increasing in trend despite reducing in other head and neck squamous cell carcinoma. Muffled voice, dysphagia, neck mass and pain over the throat are among the common presentations; however, health care professional should be aware of unusual presentation to avoid delay in management. We present a case of HPV-positive OPSCC with a rare presentation; progressive worsening of snoring for 6 months duration. Patient sought medical attention at the some of private clinics for the past 2 months, however, was told to have a normal tonsillar enlargement. Subsequently, patient was referred to our center with impression of obstructive sleep apnea. We highlight the important of early referral to appropriate center and otorhinolaryngology for assessment in cases presented with worsening snoring.

KEYWORDS

oropharyngeal carcinoma; human papillomavirus; snoring

AUTHOR AFFILIATIONS

¹ Department of Otorhinolaryngology-Head & Neck Surgery, School of Medical Sciences, Universiti Sains Malaysia Health Campus, Kelantan, Malaysia

² Department of Pathology, School of Medical Sciences, Universiti Sains Malaysia Health Campus, Kelantan, Malaysia

* Corresponding author: Department of Otorhinolaryngology-Head & Neck Surgery, School of Medical Sciences, Universiti Sains Malaysia Health Campus, 16150 Kota Bharu, Kelantan, Malaysia; e-mail: irfankb@usm.my

Received: 10 December 2020

Accepted: 14 February 2022

Published online: 29 June 2022

Acta Medica (Hradec Králové) 2022; 65(1): 29–32

<https://doi.org/10.14712/18059694.2022.13>

© 2022 The Authors. This is an open-access article distributed under the terms of the Creative Commons Attribution License (<http://creativecommons.org/licenses/by/4.0>), which permits unrestricted use, distribution, and reproduction in any medium, provided the original author and source are credited.

INTRODUCTION

The incidence of oropharyngeal squamous cell carcinoma (OPSCC) is increasing despite declined in other head and neck squamous cell carcinoma (HNSCC) (1, 2). This is believed due to the gradual decrease in smoking and alcohol intake while increasing in the incidence of human papillomavirus (HPV) infection (1). A 70% of newly diagnosed OPSCCs are HPV positive and HPV was found to be an independent risk factor for OPSCC (3, 4). Interestingly, the majority of HPV-positive head and neck cancers are located in the oropharyngeal region (3).

Patients with oral and oropharyngeal cancer are generally present late at an advanced stage, thus affecting prognosis and survival rate (3, 5). Among the reasons for this are patients considered their conditions as something minor or insignificant and would get better with time (5). The top 3 presenting symptoms are neck mass, sore throat and dysphagia (2, 3). However, these are considered late symptoms as tumour already large enough to cause local pressure to nearby structures, obstructing upper aerodigestive tract and metastasis to the regional lymph node. Patients may have early benign symptoms which not to their concern of the underlying sinister pathology or seek medical attention for other reason and being incidental finding during physical examination. Furthermore, some of the cases may have an atypical presentation which required detail history and examination to reach the diagnosis.

CASE REPORT

A 35-year-old gentleman with no known medical illness, presented with progressive worsening of snoring for the past 6-month duration. He started to seek medical attention 2 months prior because the snoring became louder and disturbed his spouse. It was associated with sleep apnoea, however, no reported daytime somnolence. Besides, his speech also changed as noticed by the friends 2 months

ago, however not to patient concern. He denied history of rhinitis symptoms or tonsillitis episodes. Otherwise, there were no history of dysphagia, odynophagia, shortness of breath, sore throat, referred otalgia, bleeding per-oral, neck swelling, loss of appetite, loss of weight, fever and night sweat.

Socially, he works as a teacher, married and blessed with 4 children, non-smoker, non-alcoholic drinker, no high risk behaviour or sexually active, and no family history of malignancy. He visited some of the private clinics for the past 2 months, however, was told to have a normal tonsillar enlargement. He ended up to an otolaryngologist, with the referral of suspecting obstructive sleep apnoea (OSA).

On examination, he was obese with a body mass index of 38 kg/m², sitting comfortably without respiratory distress. He had muffled speech, otherwise no stridor or stertor. The oral cavity was normal. Oropharyngeal examination revealed a right tonsillar mass, multi-lobulated surface covered with minimal slough and crossing the midline, with no ulcer or bleeding seen (Figure 1). The left tonsil was grade 1 (according to Friedman et al. grading system (6)) and no restriction of tongue mobility. Other oropharyngeal subsites were hardly visualized, as obscured by the mass. No cervical lymph node or neck mass palpable. Flexible nasopharyngolaryngoscopy revealed a right oropharyngeal mass, crossing the midline and obscuring base of tongue, right vallecula and epiglottis. Otherwise, other laryngeal subsites were normal and no mass seen at bilateral fossa of Rosenmuller.

Biopsy was taken from right oropharyngeal mass, which revealed malignant squamous cell carcinoma, arranged in infiltrative cords and nest with desmoplastic stroma (Figure 2A). The malignant cells are positive for p63 (Figure 2B) and p16 immunohistochemistry staining (Figure 2C). Computed tomography of the base of skull until abdomen was performed and showed large ill-defined heterogeneous enhancing mass measuring 3.5 × 4.5 × 6.5 cm at right oropharyngeal region, occupying the right vallecula and infiltrating right pharyngeal mucosa with no clear

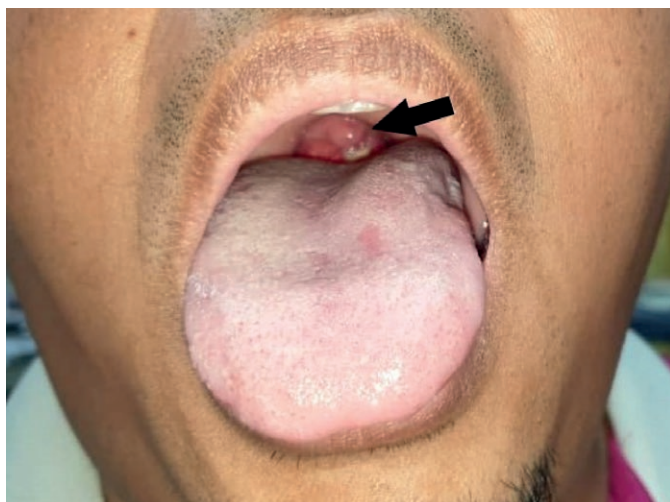

Fig. 1 Oropharyngeal examination shows right oropharyngeal mass (arrow), originated from right tonsil, crossing the midline, multi-lobulated and covered with minimal slough.

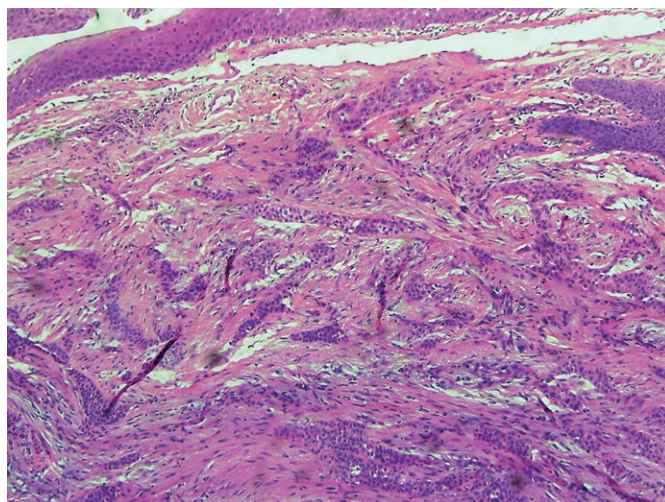


Fig. 2A Haematoxylin & Eosin of Squamous cell carcinoma (100×). Infiltrative tumour arranged in trabeculae and cords with desmoplastic stroma.

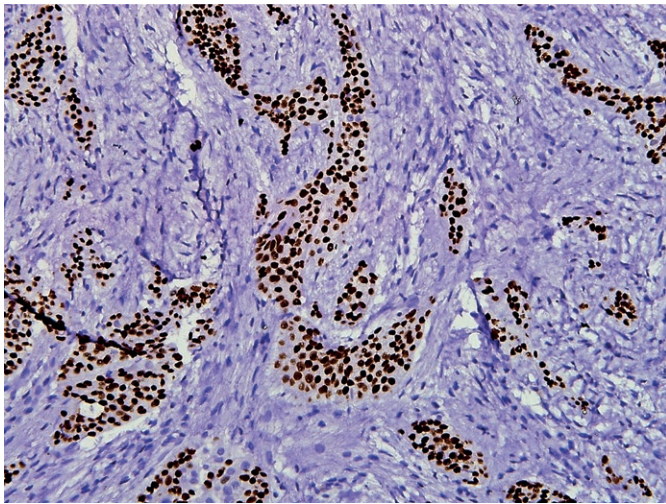


Fig. 2B Immunohistochemical stain (400×). The malignant cells show positive nuclear staining for p63.

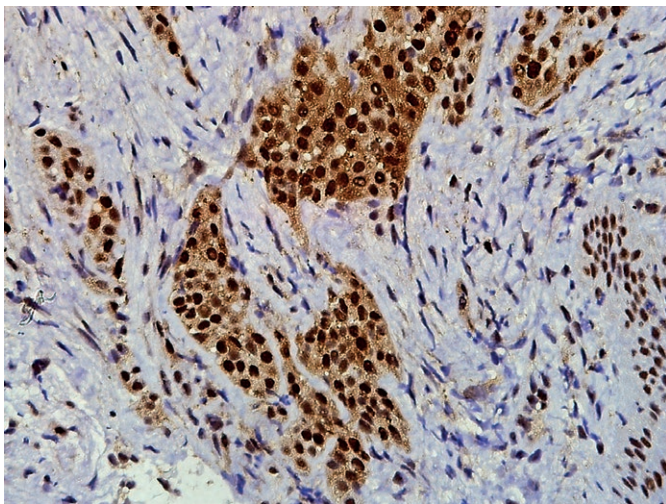


Fig. 2C Immunohistochemical stains (400×). The malignant cells show positive nuclear and cytoplasmic staining for p16.

fat plane with the base of tongue and epiglottis (Figure 3). Also, multiple cervical lymph nodes enlargement was seen including bilateral level Ib and IIa, right level IIb and left level III (largest at left level IIa measuring 0.8 cm × 1.7 cm). No distant metastasis visualised from the scan, thus his staging was T₃N₂M₀ (according to latest TNM staging, 8th edition, by American Joint Committee on Cancer (7)).

A multidiscipline team meeting was conducted with a consensus that the patient would be more beneficial from chemoradiotherapy (CRT). Patient was explained regarding the modality of treatments either surgery or CRT, and he opted for CRT.

DISCUSSION

Demographic profiles, risk factors and tumour characteristics are different between HPV-positive and HPV-negative OPSCCs (2, 3). HPV-related OPSCC is currently considered a distinct disease due to its specific characteristic and oncogenic HPV aetiology (8). High-risk HPV infection of

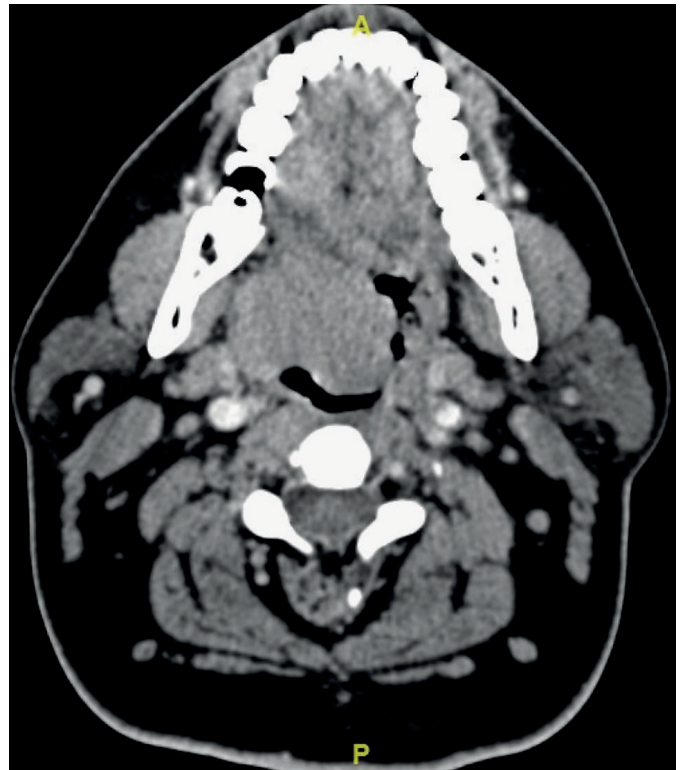

Fig. 3 Computed tomography, contrasted axial view at level of oropharynx shows large ill-defined heterogenous enhancing mass measuring 3.5 × 4.5 × 6.5 cm at oropharynx region, occupying the right vallecula and infiltrating right pharyngeal mucosa with no clear fat plane with base of tongue and epiglottis.

oropharynx will produce two crucial viral oncoproteins; E6 and E7. These oncogenes can inactivate p53 and pRB tumour suppressor gene, which lead to dysregulation of the cell cycle. Inactivation of pRB by viral oncoprotein E7 will result in overproduction of p16. High-level of p16 expression is an excellent marker for high-risk HPV-related cancers. Therefore, p16 immunohistochemistry is used as a surrogate marker for HPV-positive OPSCC (9).

Most of HPV-positive OPSCC patients are found to be younger, white males, non-smoker, generally healthier, sexually active and higher socio-economical group, while patients are generally older with history of heavy smoking and alcohol consumption in HPV-negative OPSCC (2, 3). Furthermore, HPV-positive OPSCC is found more common in a western country and believed due to changing in sexual practices with increasing in oral sexual behaviour (10). The prevalence of HPV-positive OPSCC was found to be dramatically increased for the last two decades, from 40.5% before 2000, to 64.3% between 2000 and 2004, 72.2% between 2005 and 2009 and 81% between 2008 to 2013 (2, 11). These features not only simply explained the disease is increasing in trend, it also implies more people will be diagnosed with malignancy at a younger age.

Although prognosis is relatively better than HPV-negative OPSCC, generally patient presented late which usually require multimodality of treatments (2). Apart from the advanced disease itself, a combination of surgery, radiotherapy and/ or chemotherapy will result in higher morbidity. Thus, early presentation and detection of the

disease are the main key factor for a better outcome in term of prognosis and survival rate. Several studies conducted to identify the initial symptoms OPSCC, and generally concluded that neck mass is the commonest presentation of HPV-positive OPSCC while sore throat or pain is more common in HPV-negative OPSCC (2,3). Other less common presentations are dysphagia, globus sensation, direct visualisation and otalgia (2, 12).

Health care professional especially at primary care should be aware that there is a small percentage of patient who is asymptomatic and only incidental finding during medical check-up (2, 11). Studies have shown that most of the patients remained asymptomatic if tumour smaller than 2cm or still at T1 stage (5, 13). Early detection and referral to the appropriate centre is very important as there is a positive association between delay in referral, the advanced stage during initial presentation, and poor survival (12).

Our patient was initially referred from the primary care centre for suspecting obstructive OSA secondary to tonsillar hypertrophy, as he was considered as a low-risk group for malignancy. Although the patient is obese, progressive worsening of snoring without recent markedly increase in weight, frequent rhinitis symptoms or recurrent tonsillitis warrant thorough examinations or early referral to otorhinolaryngology to look for other pathology apart from OSA. In addition, associated changes of voice should denote something more sinister underlying pathology. Furthermore, malignancy should be suspected in unilateral tonsil enlargement, especially with the present of cervical lymph node enlargement. A 20% of patient with asymmetry tonsillar enlargement were found to have malignancy, either lymphoma or squamous cell carcinoma (14). Characteristic of tonsil on examination is also important to differentiate between benign and malignant. Presence of irregular surface, ulcer or bleeding usually suggested of malignancy. Due to its special characteristics compared to other types of HNSCC, HPV-positive OPSCC should be suspected in traditionally considered low-risk patients like younger age and non-smoker. The unusual presentations in our case are the main reason for the delay in referral.

Some of the head and neck tumors like lymphoma, sarcoma, pleomorphic adenoma, mycosis fungoides, paraganglioma, and rhabdomyoma have been reported to present with OSA symptoms (15). The worsening of upper airway obstruction which is the hallmark of OSA could be contributed by the disruption of the normal anatomy or physiology of upper airway by the tumors (15, 16). Anatomically, progressive enlarging of the tumors result in progressive narrowing of the upper airway or pharyngeal space. On the other hand, head and neck tumor also may result in cranial nerves palsy especially glossopharyngeal and vagus nerves. Loss of these nerves function significantly resulting in weakness of pharyngeal dilator muscles and further narrow the upper airway. OPSCC as seen in the present case is a good example of anatomical factor, while in the more advance cases of OPSCC, neural factor also may involved.

Management of HPV-positive OPSCC is depend on the stage of the disease. Due to its distinct entity, the

latest American Joint Committee on Cancer, 8th edition has revised on TNM staging of OPSCC by dividing it into HPV-associated and non-HPV-associated (7). Early-stage usually require single-modality treatment either surgery or radiation, whereas late-stage carcinomas normally require multimodality treatment with combinations of surgery, radiation, and/or chemotherapy (2).

CONCLUSION

Worsening of snoring could be the only symptom of HPV-positive OPSCC as the result of progressive enlargement of the tumor and narrowing of the upper airway. The health care professional should be aware of this unusual presentation and early referral to otorhinolaryngology is vital.

REFERENCES

1. Elrefaey S, Massaro MA, Chiocca S, Chiesa F, Ansarin M. HPV in oropharyngeal cancer: the basics to know in clinical practice. *Acta Otorhinolaryngol Ital* 2014; 34(5): 299-309.
2. McIlwain WR, Sood AJ, Nguyen SA, Day TA. Initial symptoms in patients with HPV-positive and HPV-negative oropharyngeal cancer. *JAMA Otolaryngol Head Neck Surg* 2014; 140(5): 441-7.
3. Carpén T, Sjöblom A, Lundberg M, et al. Presenting symptoms and clinical findings in HPV-positive and HPV-negative oropharyngeal cancer patients [published correction appears in *Acta Otolaryngol* 2018 Jul; 138(7): 675]. *Acta Otolaryngol* 2018; 138(5): 513-8.
4. You EL, Henry M, Zeitouni AG. Human papillomavirus-associated oropharyngeal cancer: review of current evidence and management. *Curr Oncol* 2019; 26(2): 119-23.
5. Rogers SN, Vedpathak SV, Lowe D. Reasons for delayed presentation in oral and oropharyngeal cancer: the patients' perspective. *Br J Oral Maxillofac Surg* 2011; 49(5): 349-53.
6. Friedman M, Salapatias AM, Bonzelaar LB. Updated Friedman staging system for obstructive sleep apnea. *Adv Otorhinolaryngol* 2017; 80: 41-8.
7. Kato MG, Baek CH, Chaturvedi P, et al. Update on oral and oropharyngeal cancer staging - International perspectives. *World J Otorhinolaryngol Head Neck Surg* 2020; 6(1): 66-75.
8. De Felice F, Tombolini V, Valentini V, et al. Advances in the Management of HPV-Related Oropharyngeal Cancer. *J Oncol* 2019; 2019: 9173729. Published 2019 Apr 14.
9. Sedghizadeh PP, Billington WD, Paxton D, Ebeed R, Mahabady S, Clark GT, Enciso R. Is p16-positive oropharyngeal squamous cell carcinoma associated with favorable prognosis? A systematic review and meta-analysis. *Oral Oncology* 2016 Mar 1; 54: 15-27.
10. Stein AP, Saha S, Kraninger JL, et al. Prevalence of Human Papillomavirus in Oropharyngeal Cancer: A Systematic Review. *Cancer J* 2015; 21(3): 138-46.
11. Mehanna H, Beech T, Nicholson T, et al. Prevalence of human papillomavirus in oropharyngeal and nonoropharyngeal head and neck cancer - systematic review and meta-analysis of trends by time and region. *Head Neck* 2013; 35(5): 747-55.
12. Pitchers M, Martin C. Delay in referral of oropharyngeal squamous cell carcinoma to secondary care correlates with a more advanced stage at presentation, and is associated with poorer survival. *Br J Cancer* 2006; 94(7): 955-8.
13. Mashberg A, Meyers H. Anatomical site and size of 222 early asymptomatic oral squamous cell carcinomas: a continuing prospective study of oral cancer. II. *Cancer* 1976; 37(5): 2149-57.
14. Tobias Gómez S, Palomar Asenjo V, Borrás Perera M, Pérez Hernández I, Ruiz Giner A, Palomar García V. Significación clínica de la asimetría amigdalina [Clinical significance of unilateral tonsillar enlargement]. *Acta Otorrinolaringol Esp* 2009; 60(3): 194-8.
15. Faiz SA, Balachandran D, Hessel AC, et al. Sleep-related breathing disorders in patients with tumors in the head and neck region. *Oncologist* 2014; 19(11): 1200-6.
16. Friedman M, Landsberg R, Pryor S, Syed Z, Ibrahim H, Caldarelli DD. The occurrence of sleep-disordered breathing among patients with head and neck cancer. *Laryngoscope* 2001; 111(11 Pt 1): 1917-9.