

# Bilateral Mature Ovarian Teratoma with Torsion in a Premenarchal Girl

---

Jana Lešková<sup>1,\*</sup>, Jaroslav Thierry Kříž<sup>2</sup>, Radek Štichhauer<sup>1</sup>

## ABSTRACT

Mature cystic teratoma is the most common type of ovarian tumor in children. Adnexal torsion is the main complication of mature ovarian teratoma. The synchronous bilateral incidence of mature cystic teratoma in premenarchal girls is known to be rare. However, the incidence of adnexal torsion is higher in young girls. A 10-year-old girl presenting with acute abdomen was managed by emergency laparotomy. Bilateral mature ovarian teratoma with adnexal torsion of the right ovary was found. The right ovarian tissue was not viable due to torsion and an oophorectomy was necessary. Cystectomy with preservation of the ovarian tissue of the left ovary was performed. Histopathological diagnosis was bilateral synchronous mature teratoma with necrosis of the right adnexa. Although the risk of malignancy of torsed ovaries and mature teratomas in premenarchal girls is low, their removal is recommended to prevent adnexal torsion. Decision between ovarian tissue sparing surgery or oophorectomy depends on the risk of malignancy, fertility preservation and the avoidance of early menopause.

## KEYWORDS

premenarchal girl; adnexal torsion; ovarian teratoma; surgery

## AUTHOR AFFILIATIONS

<sup>1</sup> Department of Pediatric Surgery and Traumatology, Charles University, Faculty of Medicine and University Hospital, Hradec Králové, Czech Republic

<sup>2</sup> Department of Obstetrics and Gynecology, Charles University, Faculty of Medicine and University Hospital, Hradec Králové, Czech Republic

\* Corresponding author: Department of Pediatric Surgery and Traumatology, Charles University, Faculty of Medicine and University Hospital, Hradec Králové, Czech Republic; e-mail: jana.leskova@fnhk.cz

Received: 27 January 2021

Accepted: 5 April 2022

Published online: 29 June 2022

---

Acta Medica (Hradec Králové) 2022; 65(1): 33–36

<https://doi.org/10.14712/18059694.2022.14>

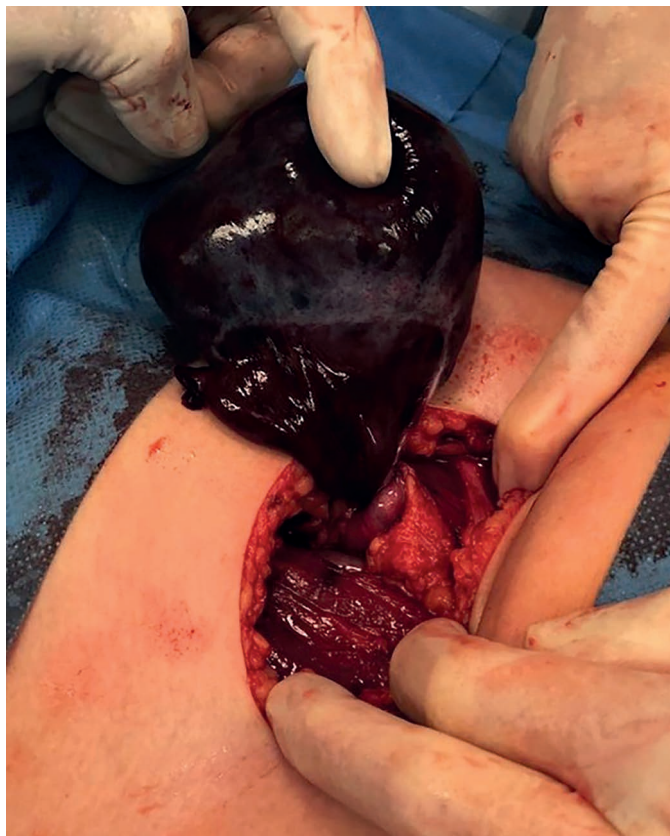© 2022 The Authors. This is an open-access article distributed under the terms of the Creative Commons Attribution License (<http://creativecommons.org/licenses/by/4.0>), which permits unrestricted use, distribution, and reproduction in any medium, provided the original author and source are credited.

## INTRODUCTION

Ovarian tumors are rare, comprising only 1.5% of all childhood tumors (1). Within the group of ovarian tumors, ovarian teratomas are the most common type of ovarian germ cell tumors in children and account for 27% of all teratomas in large series. Teratomas are classified as mature, immature and malignant (2). The most common ovarian tumors in children are mature cystic teratomas, consisting up to 20% of all the ovarian tumors (1). The bilateral presence is in 12% of all cases and risk of malignancy is approximately 2% (3). Adnexal torsion is a rare pediatric surgery emergency, but is the main complication of mature ovarian teratomas (4). In the case report is presented a case of bilateral synchronous mature ovarian teratomas with torsion in a premenarchal girl, which was managed in our department.

## CASE REPORT

A 10-year-old previously healthy girl was admitted to the hospital, as emergency due to abdominal pain, nausea and repeated vomiting. The patient presented with a complaint of intermittent lower abdominal pain for two days that worsened over last 12 hours. On physical examination a palpable firm mass was identified and distension of the abdomen was observed. The ultrasound scan revealed mass of cystic-solid composition without calcification and other three cystic masses in the pelvic region. The size of

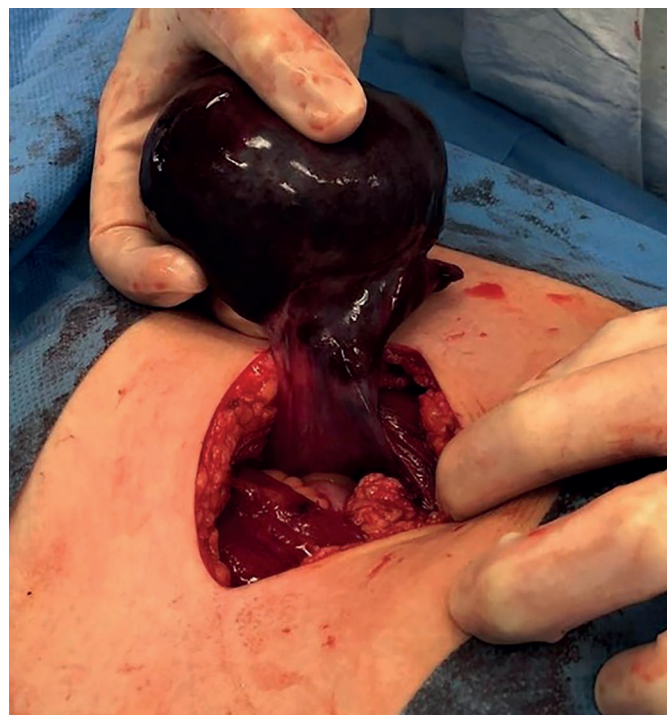

**Fig. 1** The torsion of the right ovary. The right ovary size was 9 cm in diameter and ovarian tissue was completely twisted 720 degrees.

the largest structure was found to be 10 cm in diameter. The chest X-ray was performed with normal findings. CT or MRI scan was not done because of emergency. Serum tumor and inflammatory markers were within the normal range. Under a diagnosis of acute abdomen with lower abdominal tumor, the patient was indicated to the laparotomy. The patient was operated on 3 hours after admission to the hospital. Preoperative diagnosis was suspected as an ovarian tumor with adnexal torsion. The initial operative finding revealed a torsion of the right ovary. The average right ovary size was found to be 9 cm in diameter. Right ovarian tissue was completely twisted 720 degrees (Fig. 1). The ovary was not salvaged with detorsion because of its necrosis. Due to irreversible ischemic damage of the ovary, right oophorectomy was necessary (Fig. 2). Under next observation the other cystic mass on the left ovary was noted with an average size of 6 cm in diameter (Fig. 3). Cystectomy with preservation of the ovarian tissue of the left ovary was performed (Fig. 4). Histopathological examination showed bilateral synchronous mature teratoma with necrosis of the right adnexa. The postoperative course was uneventful and the patient was discharged on the 5th day after surgery.

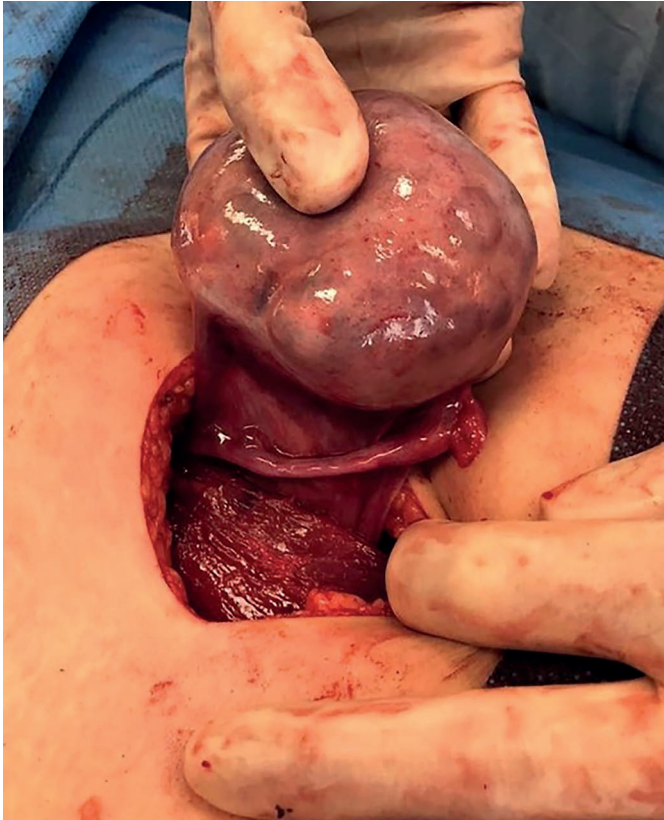
## DISCUSSION

Teratomas are the most common histologic subtype of childhood ovarian germ cell tumors (2). Their optimal operative management in this age group still remains unclear because of the rarity of such tumors and depends on retrospective studies (1, 5). In scoping review from Poland authors have revealed a number of knowledge gaps in the



**Fig. 2** The right ovary after detorsion. Due to irreversible ischemic damage to the ovary, right oophorectomy was necessary.



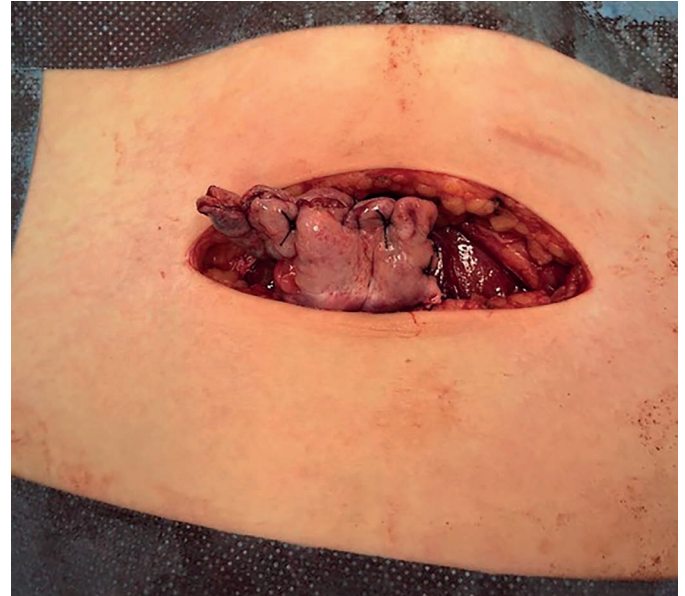


**Fig. 3** The cystic mature teratoma of the left ovary. The average size was 6 cm in diameter. Cystectomy with preservation of the ovarian tissue of the left ovary was performed.

evidence based medicine for pediatric ovarian teratomas (6). The other systematic review reported by Renaud et al. also has revealed lack of prospective and randomized trials (1).

We present rare case of bilateral synchronous mature ovarian teratomas with torsion in a premenarchal girl, which was managed in our department. The first case was reported by authors from Japan in 2006 (7). Although mature cystic teratomas are the most common ovarian tumors in children (2), their unilateral incidence is known to be rare in premenarchal girls and synchronous bilateral incidence is even more unusual. Mature teratomas are bilateral in only 12% of cases and become malignant in approximately 2% (3). Although the overall rate of malignancy in torsed ovaries is low and mature teratomas in premenarchal girls are rarely malignant, their removal may be performed to prevent adnexal torsion (1, 4). Adnexal torsion is the main complication of mature ovarian teratomas (4, 8) and the incidence of adnexal torsion is associated with younger age (4, 9). Decision between ovarian tissue sparing surgery or oophorectomy depends on the risk of malignancy, fertility preservation and the avoidance of early menopause.

In a nationwide population-based cohort study from the Netherlands there was an exponential increase of the adnexal masses in relation with age. The proportion of malignancy in this study was highest in the premenarchal girls. Oophorectomies were more often performed in the premenarchal age group, while ovarian sparing surgeries were more common in postmenarchal patients both in



**Fig. 4** Finished suture of the rest of the left ovarian tissue after cystectomy.

benign mass (10). Presumption of malignancy and necrosis caused by torsion may necessitate oophorectomy (9). The treatment of the torsion is an emergency and must be as conservative as possible in order to preserve the ovarian function. Oophorectomy is reserved for necrotic ovaries. The tolerable duration for functional preservation of ovarian tissue after adnexal torsion in premenarchal girls has not been established yet. Report from Takeda et al. suggested that preservation of ovarian tissue was possible if surgery was performed within 8 hours after symptom onset (7). In our report it was more than 12 hours after symptom onset and oophorectomy was necessary because of irreversible ischemic damage of ovarian tissue. This ischemic damage was dependant on the degree of torsion too. The current literature suggests that it is safe to perform only detorsion, regardless of the level of ischemia or volume of the torsed ovary (11). In our case right ovary could not be salvaged with detorsion as the tissue was completely necrotic and did not recover despite detorsion. As in other reports (4, 12), cystectomy was performed in our patient on the left ovary. Ovarian tissue sparing technique with preservation of the ovarian tissue of the affected gonad in children should be successfully applied as much as possible, considering normal puberty, future fertility and the lower incidence of malignancy in this age group (4, 9). However, inadequate resection or staging in the setting of a malignancy may place the patient at risk for unnecessary adjuvant therapy or recurrent disease. The premenarchal girl in our case had bilateral synchronous mature ovarian teratomas with torsion of the right ovary. Elective oophorectomy was not performed because of the fear that residue of the left ovarian tissue may be negatively influenced by pexy sutures in the future. Oophoropexy should decrease the risk of subsequent contralateral torsion but there is no evidence showing its efficacy in pediatric age group. The role of oophoropexy in treating ovarian torsion is still not clear (2, 9, 11).

An other important aspect of the management of ovarian teratomas is their recurrence rate and the incidence of bilateral lesions. In the UK nationwide study recurrence occurred in 4.8%, 2.9% children had synchronous tumors and 3.2% were diagnosed with metachronous tumors (13). The authors demonstrated that ovarian tumor recurrence and metachronous disease occur, even in tumors that were previously deemed as benign lesions (13). All pediatric patients should undergo follow-up surveillance after resection of an ovarian tumor including benign lesions to ensure the early detection of metachronous contralateral lesions or ipsilateral recurrence. The unilateral oophorectomy for ovarian tumors reduces the risk of tumor recurrence, but it may have negative effects on later oocyte production and may result in earlier menopause (1). Chabaud-Williamson et al. evaluated in their retrospective study endocrine function and fertility after unilateral oophorectomy that was performed for the first tumor in patients who were initially treated for unilateral ovarian teratoma but were subsequently diagnosed with a contralateral lesion. The patients had regular normal menstruations and the eldest had a spontaneous and normal pregnancy at last follow-up (14). Thus, patients who are managed by unilateral oophorectomy for ovarian teratoma may have regular menstruations and spontaneous pregnancies.

## CONCLUSION

Mature teratomas are generally diagnosed in reproductive age group. Unilateral incidence is known to be rare in premenarchal girls, synchronous bilateral is even more unusual. However, the incidence of adnexal torsion is higher in young girls. Although the overall rate of malignancy in torsed ovaries is low and mature teratomas in premenarchal girls are rarely malignant, their removal may be performed to prevent adnexal torsion. Decision between ovarian tissue sparing surgery and oophorectomy depends on the risk of malignancy, fertility preservation and the avoidance of early menopause. All pediatric patients should undergo follow-up surveillance after resection of

an ovarian tumor including benign lesions to ensure the early detection of metachronous contralateral lesions or ipsilateral recurrence.

## REFERENCES

1. Renaud EJ, Sømme S, Islam S, et al. Ovarian masses in the child and adolescent: An American Pediatric Surgical Association Outcomes and Evidence-Based Practise Committee systematic review. *J Pediatr Surg* 2019;54:369-377.
2. Holcomb GW, Murphy JP, Ostlie DJ. *Ashcrafts pediatric surgery*. 6th ed. Elsevier Saunders, 2014: 935-8, 1051-5.
3. Symonds EM, Symonds IM. *Essential Obstetrics and Gynaecology*. 4th ed. Elsevier Science, 2004: 324-34.
4. Rabinovich I, Pekar-Zlotin M, Bliman-Tal Y, Melcer Y, Vaknin Z, Smorgick N. Dermoid cysts causing adnexal torsion: What are the risk factors? *Eur J Obstet Gynecol Reprod Biol* 2020; 251: 20-2.
5. Takayasu H, Masumoto K, Tanaka N, et al. A clinical review of ovarian tumors in children and adolescents. *Pediatr Surg Inter* 2020; 36: 701-9.
6. Łuczak J, Bağlaj M, and Dryjański P. What recent primary studies tell us about ovarian teratomas in children: a scoping review. *Cancer Metastasis Rev* 2020; 39(1): 321-9.
7. Takeda A, Manabe S, Mitsui T and Nakamura H. Laparoscopic Management of Mature Cystic Teratoma of Bilateral Ovaries with Adnexal Torsion Occurring in a 9-Year-Old Premenarchal Girl. *J Pediatr Adolesc Gynecol* 2006; 19: 403-6.
8. Fayed I, Khreisat B, Athamneh T, Omoosh R, and Daibes MA. Multiple Bilateral Ovarian Mature Cystic Teratomas with Ovarian Torsion: A Case Report. *Oman Med J* 2018; 33 (No. 2): 163-66.
9. User IR, Karakuş SC, Özokutan BH, Akçaer V, Burulday B, Ceylan H. Can preoperative findings help to interpret neoplastic and non-neoplastic lesions of ovary and affect surgical decisions in children and adolescents? *Arch Argent Pediatr* 2019; 117(5): 294-300.
10. Hermans AJ, Kluijvers KB, Janssen LM, et al. Adnexal masses in children, adolescents and women of reproductive age in the Netherlands: A nationwide population-based cohort study. *Gynecologic Oncology* 2016; 143: 93-7.
11. Geimanaite L, Trainavicius K. Pediatric ovarian torsion: Follow-up after preservation of ovarian tissue. *J Pediatr Surg* 2019; 54: 1453-6.
12. Cribb B, Vishwanath N, Upadhyay V. Paediatric ovarian lesions - the experience at Starship Children's Hospital, New Zealand. *NZMJ* 2014; 127(No 1395).
13. Braungart S, CCLG Surgeons Collaborators, Craigie RJ, Farrelly P, Losty PD. Ovarian tumors in children: how common are lesions recurrence and metachronous disease? A UK CCLG Surgeons Cancer Group nationwide study. *J Pediatr Surg* 2020; 55: 2026-9.
14. Chabaud-Williamson M, Netchine I, Fasola S, et al. Ovarian-Sparing Surgery for Ovarian Teratoma in Children. *Pediatr Blood Cancer* 2011; 57: 429-34.