

Transient Hyperphosphatasemia in a Child with Autism Spectrum Disorder

Štěpán Kutílek^{1,*}, Eva Rondzиковá-Mlynarčíková¹, Kamila Pečenková¹, Richard Píkner², Tomáš Šmída³, Eva Sládková⁴, Tomáš Honzík⁵, Hana Kolářová⁵, Martin Magner⁵

ABSTRACT

Introduction: Autism spectrum disorder (ASD) is a neurodevelopmental disorder characterized by deficits in social communication and the presence of restricted interests and repetitive behaviors. Transient hyperphosphatasemia of infancy and early childhood (THI) is a benign laboratory disorder characterized by transiently extremely elevated activity of serum alkaline phosphatase (S-ALP).

Case Report: We present a 21-month-old girl with a right leg limp, most probably due to reactive arthritis after febrile viral infection, and deterioration of psychomotor development with concomitant transient elevation of S-ALP (61.74 $\mu\text{kat/L}$; normal 2.36–7.68 $\mu\text{kat/L}$). Normal values of serum creatinine, aspartate-aminotransferase, alanin-aminotransferase, calcium, phosphate, together with normal wrist X-ray ruled out rickets or other bone or hepatic cause of high S-ALP. The S-ALP gradually decreased within 3 months, thus fulfilling the THI criteria. Screening for inborn errors of metabolism was negative and meticulous neurologic, psychologic and psychiatric assessment pointed to the diagnosis of autism spectrum disorder (ASD). There was no causal relationship between THI and ASD, as high S-ALP was an accidental and transient finding within the routine laboratory assessment. However, when THI occurs in a child with an onset of a new disorder, or with a pre-existing bone or liver disease, it might seriously concern the physician.

Conclusion: Children with THI should be spared from extensive evaluations and unnecessary blood draws.

KEYWORDS

autism spectrum disorder; alkaline phosphatase; transient hyperphosphatasemia

AUTHOR AFFILIATIONS

¹ Department of Pediatrics, Klatovy Hospital, Klatovy, Czech Republic

² Department of Clinical Biochemistry, Klatovy Hospital, Klatovy, Czech Republic

³ General Pediatric Practitioner, Klatovy, Czech Republic

⁴ Department of Pediatrics, Faculty Hospital in Pilsen and Faculty of Medicine in Pilsen, Charles University, Czech Republic

⁵ Department of Pediatrics and Inherited Metabolic Disorders, Faculty Hospital in Prague and 1st Faculty of Medicine in Prague, Charles University, Czech Republic

* Corresponding author: Klatovy Hospital, Klatovy, Czech Republic;
e-mail: kutilek@nemkt.cz; stepan.kutilek@klatovy.nemocnicepk.cz

Received: 28 February 2022

Accepted: 28 April 2022

Published online: 29 June 2022

Acta Medica (Hradec Králové) 2022; 65(1): 41–43

<https://doi.org/10.14712/18059694.2022.16>

© 2022 The Authors. This is an open-access article distributed under the terms of the Creative Commons Attribution License (<http://creativecommons.org/licenses/by/4.0>), which permits unrestricted use, distribution, and reproduction in any medium, provided the original author and source are credited.

INTRODUCTION

Autism spectrum disorder (ASD) is a neurodevelopmental disorder characterized by deficits in social communication and the presence of restricted interests and repetitive behaviors (1). Prospective studies of children with ASD show that abnormalities in social communication and repetitive behaviors emerge during the second year and motor and sensory abnormalities might emerge in the first year of life (1–3). Transient hyperphosphatasemia of infancy and early childhood (THI) is a benign laboratory disorder characterized by transiently extremely elevated activity of serum alkaline phosphatase (S-ALP) in infants and toddlers without any signs of bone or liver disease. The detection of THI is mostly accidental (4–7). We present a girl with ASD and THI.

CASE REPORT

A 21-month-old girl with uneventful perinatal history and rather rapid developmental milestones (according to parents, she stood up before 8 months of age, started walking unsupported at 10 months, but had a speech delay) was intermittently feverish for one week and was also noticed with a right leg limp without any evidence of trauma, nor swelling or redness of the joints. Her parents brought her to a General Pediatric Practitioner, who ordered X-ray of the painful extremity and basic laboratory evaluation. X-ray of the right lower extremity was normal. C-reactive protein was low (<1 mg/L), thus ruling out severe inflammation. Blood count and basic biochemical parameters were within normal pediatric age-related reference values (Table 1), with the exception of S-ALP (45 μ kat/L) (Figure 1). Simultaneously, the parents noticed significant changes in the girl's behavior, such as mutism, anxiety, clumsiness, irritability, hypomimia, and no communication skills. Therefore the child was referred to a hospital, where even higher S-ALP was confirmed (Figure 1), with otherwise normal blood biochemistry, normal wrist and knees X-ray, normal abdominal ultrasound thus completely ruling out rickets and/or other bone or hepatic disease, known to be associated with high S-ALP. Both fever and limping resolved immediately upon hospital admission, and these were attributed to viral infection and, most probably, to reactive arthritis. The diagnosis of THI was established. She was dismissed after three days. Furthermore, at home, the change in child's habits were more profoundly apparent and after two weeks she was hospitalized for two days with normal laboratory results, including a decline in originally high S-ALP. However, due to the change in child's behavior and a deterioration in her psychomotor development, an inborn error of metabolism was suspected. Therefore, she was then referred to a specialised center for inborn errors of metabolism. The detailed screening for inborn metabolic disorders was negative, magnetic resonance imaging of the brain was normal and a detailed psychologic and psychiatric assessment (Modified Checklist for Autism in Toddlers, Revised, M-CHAT-R, screening 9 points out of 20) was highly indicative of autism spectrum disorder (ASD). In the meantime, the S-ALP dropped to 4.15 μ kat/L after

Tab. 1 Initial basic biochemical results in our patient.

Parameter	Units	Patient	Reference value
S-ALP	μ kat/L	45	2.36–7.68
S-AST	μ kat/L	0.55	\leq 0.83
S-ALT	μ kat/L	0.33	\leq 0.50
S-CK	μ kat/L	1.67	0.4–3.82
S-creatinine	μ mol/L	28	35–62
S-Ca	mmol/L	2.54	2.2–2.6
S-P	mmol/L	1.62	1.0–1.95
S-Mg	mmol/L	0.92	0.86–1.17
S-Na	mmol/L	140	134–143
S-K	mmol/L	4.4	3.3–4.6
S-Cl	mmol/L	107	96–109

Abbreviations: S-ALP – serum activity of alkaline phosphatase; S-AST – serum activity of aspartate-aminotransferase; S-ALT – serum activity of alanine-aminotransferase; S-CK – serum activity of creatinase; S-Ca – serum level of total calcium; S-P – serum level of phosphate; S-Mg – serum level of total magnesium; S-Na – serum level of sodium; S-K – serum level of potassium; S-Cl – serum level of chloride

14 weeks (Figure 1). There were no other indices of bone or liver disease. Currently, the girl is five years old and is being followed-up by a specialised pediatric psychiatrist, psychologist and neurologist as the diagnosis of ASD has been confirmed.

DISCUSSION

THI is diagnosed incidentally in both healthy and sick children, rather a laboratory, than a clinical disorder, which is benign and self-limiting (4–7). So far, there are literature reports of THI in about 900 children, both sick and healthy. However, its incidence, based on secondary data analysis of 316 healthy infants and toddlers was estimated at 2.8% (7). The criteria for THI were first defined by Kraut et al. (8) (Table 2). THI has been also described even in adults, and in some children the S-ALP returned to normal values after more than four months (5–7). Previously

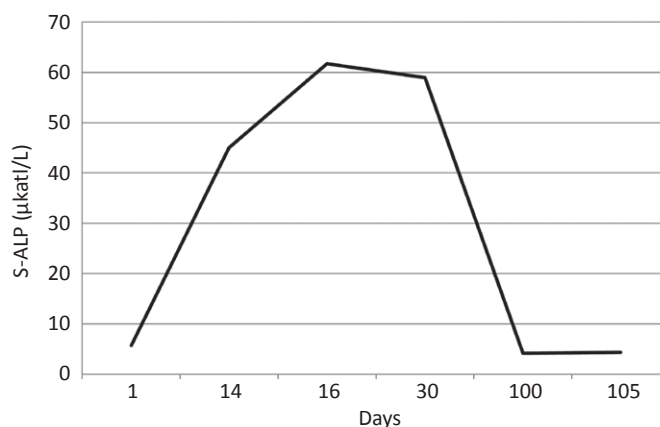


Fig. 1 Course of S-ALP in our patient. Age-related reference values 2.36–7.68 μ kat/L.

Tab. 2 THI criteria devised by Kraut et al. in 1985 (8).

■ an age of less than 5 years
■ variable, unrelated symptoms
■ no bone or liver disease on physical examination or from laboratory investigations;
■ isoenzyme and isoform analysis showing elevations in both bone and liver activity
■ return to normal S-ALP values within four months

published observations ruled out either bone or hepatic disease related to THI, as parathyroid hormone levels, bone turnover markers and liver enzymes were within normal reference ranges (4–7, 9–11). THI might raise concern when encountered in children with skeletal disorders, chronic renal failure, malignancies or hepatopathy, wrongly suggesting the flare-up of the underlying disease (5, 6, 11, 12). The electrophoretic evaluation of the ALP isoenzymes and isoforms in blood samples from patients with THI revealed an atypical transient pattern of cathodal and anodal migrating fractions, similar to the isoforms of bone and liver origin (4, 5, 8, 13). THI is most probably caused by a viral infection as THI frequently occurs in children with a history of viral disease 2–3 weeks prior to the S-ALP elevation and was also observed and reported in siblings or in patients who were hospitalised together (5, 14–16). This also occurred in our patient, as febrile, most probably viral, infection preceded the detection of high S-ALP. The limping in our patient was most probably a manifestation of reactive arthritis due to a febrile viral infection. The impaired clearance of ALP from circulation is believed as the most likely cause of THI (5, 7, 11). In our patient with transiently deteriorated gait and first signs of ASD, the high value of S-ALP initially concerned the pediatrician, however the routine work-up ruled out bone or liver affection, metabolic disease, clearly pointing to the diagnosis of THI. There was no relationship between ASD and THI, as high S-ALP was an accidental and transient finding within the routine laboratory assessment. However, once THI occurs in a child with an onset of a new disorder, or with a pre-existing malignancy, bone or liver disease, it might seriously concern the pediatrician (5, 6, 11, 12, 17). Similarly, THI can alert the physician when encountered in a post-transplant patient (11, 18). It is recommended that S-Ca, P, creatinine, ALT, AST should be assessed, together with wrist X-ray to

rule out rickets, renal failure or hepatopathy. Once THI is confirmed with the use of these assessments and Kraut's criteria, control S-ALP can be assessed after three months. Children with THI should be spared from extensive evaluations and unnecessary blood draws.

REFERENCES

- Hodges H, Fealko C, Soares N. Autism spectrum disorder: definition, epidemiology, causes, and clinical evaluation. *Transl Pediatr* 2020; 9(Suppl 1): S55–S65.
- Sacrey LAR, Bennett JA, Zwaigenbaum L. Early Infant Development and Intervention for Autism Spectrum Disorder. *J Child Neurol* 2015; 30: 1921–9.
- Brian JA, Zwaigenbaum L, Ip A. Standards of diagnostic assessment for autism spectrum disorder. *Paediatr Child Health* 2019; 24: 444–60.
- Stein P, Rosalki SB, Foo AY, Hjelm M. Transient hyperphosphatasemia of infancy and early childhood: clinical and biochemical features of 21 cases and literature review. *Clin Chem* 1987; 33: 313–8.
- Kutilek S, Bayer M. Transient hyperphosphatasemia – where do we stand? *Turk J Pediatr* 1999; 41: 151–60.
- Gualco G, Lava SA, Garzoni L, Simonetti GD, Bettinelli A, Milani GP, et al. Transient benign hyperphosphatasemia. *J Pediatr Gastroenterol Nutr* 2013; 57: 167–71.
- Huh SY, Feldman HA, Cox JE, Gordon CM. Prevalence of transient hyperphosphatasemia among healthy infants and toddlers. *Pediatrics* 2009; 124: 703–9.
- Kraut JR, Metrick M, Maxwell NR, Kaplan MM. Isoenzyme studies in transient hyperphosphatasemia of infancy. Ten new cases and a review of the literature. *Am J Dis Child* 1985; 139: 736–40.
- Kruse K. Normal bone turnover in isolated hyperphosphatasemia. *J Pediatr* 1985; 106: 946–8.
- Kutilek S, Cervickova B, Bebova P, Kmonickova M, Nemeč V. Normal bone turnover in transient hyperphosphatasemia. *J Clin Res Pediatr Endocrinol* 2012; 4: 154–6.
- Kutilek S, Skálová S, Vethamuthu J, Geier P, Feber J. Transient hyperphosphatasemia in pediatric renal transplant patients—is there a need for concern and when? *Pediatr Transplant* 2012; 16: E5–9.
- Kutilek S, Stepan J, Bayer M. A case of transient hyperphosphatasemia following vitamin D-deficient rickets. *Turk J Pediatr* 1993; 35: 205–7.
- Weiber H, Fex G, Lindberg T, Skude G. Atypical, anodally migrating alkaline phosphatase isoenzyme in children and its relation to abdominal symptoms. *Clin Chem* 1983; 29: 593–5.
- Kruse K, Kurz N. Further evidence for infectious origin of isolated transient hyperphosphatasemia. *Eur J Pediatr* 1989; 148: 453–4.
- Sánchez Jacob M, Escudero Gutiérrez R, Bernardo Fernández T. Transient hyperphosphatasemia in infancy. Two simultaneous cases in twins. *An Esp Pediatr* 1991; 35: 365–6.
- Sakurai Y, Higashiguchi T. Transient hyperphosphatasemia: Possible association with pediatric acute respiratory infection. *Pediatr Investig* 2021; 5: 94–8.
- Eymann A, Cachiarelli N, Alonso G, Llera J. Benign transient hyperphosphatasemia of infancy. A common benign scenario, a big concern for a pediatrician. *J Pediatr Endocrinol Metab* 2010; 23: 927–30.
- Cole EB, Anslow M, Fadakar P, Miyashita Y, Ganoza A, Moritz ML. Transient hyperphosphatasemia following pediatric kidney transplant. *Cureus* 2021; 13: e17697.