

# Necrotizing Fasciitis in the Immediate Post-Operative Period Following Resection and Free Flap Reconstruction for Oral Cancer

---

Alice Rigby<sup>1</sup>, Paul Sexton<sup>1</sup>, Preetha Chengot<sup>1</sup>, Anastasios Kanatas<sup>1,\*</sup>

## ABSTRACT

Necrotising fasciitis (NF) is a rapidly spreading bacterial infection of the fascial planes and can be fatal if is not treated urgently. Here, we present the case of a 65-year-old female, with oral squamous cell carcinoma, treated surgically with curative intent. On the second post-operative day from a mandibulectomy, selective neck dissection and reconstruction with a fibula free flap, she developed rapidly progressing NF, at the surgical site.

## KEYWORDS

necrotizing fasciitis; oral cancer; reconstruction; complications

## AUTHOR AFFILIATION

<sup>1</sup> Leeds Teaching Hospitals and St James Institute of Oncology, Leeds Dental Institute and Leeds General Infirmary, Leeds, United Kingdom

\* Corresponding author: Leeds Teaching Hospitals and St James Institute of Oncology, Leeds Dental Institute and Leeds General Infirmary, LS1 3EX, Leeds, United Kingdom; e-mail: anastasios.kanatas@nhs.net

Received: 16 March 2022

Accepted: 29 September 2022

Published online: 2 December 2022

---

Acta Medica (Hradec Králové) 2022; 65(2): 71–73

<https://doi.org/10.14712/18059694.2022.21>

© 2022 The Authors. This is an open-access article distributed under the terms of the Creative Commons Attribution License (<http://creativecommons.org/licenses/by/4.0>), which permits unrestricted use, distribution, and reproduction in any medium, provided the original author and source are credited.

## INTRODUCTION/BACKGROUND

NF is a bacterial infection, often polymicrobial, that can be destructive, rapidly progressing and potentially fatal. The overall reported mortality rate can be as high as 29.7% (1, 2). It is an infection of the soft tissues and moves along the fascial planes. The term was first used by Wilson (1952) and mainstays of treatment include urgent surgical debridement and antimicrobial therapy. Early intervention is essential when treating this condition to prevent serious morbidity or mortality (3).

Many different microorganisms, both aerobic and anaerobic, have been implicated in the different classifications of NF and can commonly include group A streptococcus, Methicillin-resistant staphylococcus aureus (MRSA), *Streptococcus pyogenes* as well as gram-negative organisms, as seen in this case. However, due to the variation, many bacteria cannot be ruled out with rare cases of *Pseudomonas aeruginosa* demonstrating this (3, 4). NF is rare in the head and neck region with most cases linked to cervicofacial infections (1). And even fewer cases have been linked to patients with head and neck cancer (5). Here we present the case of a patient with oral squamous cell carcinoma who developed NF following resection and reconstruction with a fibula free flap.

## CASE DESCRIPTION

A 65-year-old woman presented to the extraction clinic at Leeds Teaching Hospitals in June 2020 for dental extractions following a referral from their dentist. Abnormal gingival hyperplasia was noticed around the lower left first molar socket and a biopsy was taken that confirmed moderate differentiated squamous cell carcinoma (SCC). The staging scans included a head and neck MRI and a high-resolution CT thorax. The MRI detected ipsilateral abnormal level IB and II lymph nodes with a staging of T4 N2b M0. The treatment plan, as verified by the tumour board, included resection with reconstruction followed by adjuvant radiotherapy.

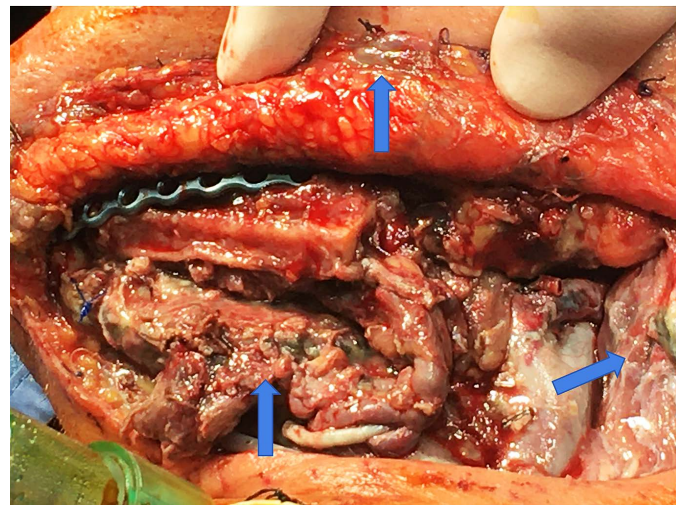
The patient's medical history included longstanding insulin-treated type 2 diabetes, coronary artery disease treated with a coronary artery bypass in May 2019, hypertension, hypercholesterolaemia and acid reflux. She was a former smoker having quit around 7 years previously and did not drink alcohol. The patient's allergies included amoxicillin and metronidazole. Their initial operation was completed in August 2020. A mandibulectomy, selective neck dissection and reconstruction with fibula free flap were completed and three vacuum drains were used as per current practice. One intraoperative and two post-operative doses of gentamicin were given for prophylaxis.

There were no surgical complications, and they were discharged from the intensive care unit 24 hours later needing no cardiovascular support and self-ventilating through the tracheostomy placed in the operating theatre.

As is normal practice within this unit, hourly flap observations were completed during the first 48 hours post operation. These were documented as normal until the patient was 2 days post-operative when suddenly there was

no capillary refill detected from the flap, no clear sounds were detected on the doppler, no bleeding occurred when the flap was scratched with a needle and an oral odour was noted.

The patient returned to theatre immediately for surgical exploration. Findings during theatre included (Figure 1) necrotic skin edges, necrotic muscles including the platysma, strap muscles, sternocleidomastoid and anterior belly of digastric. There was necrosis of the free flap pedicle and the muscle component of the free flap, with on evidence of mechanical obstruction at the anastomosis. Suppuration, foul smell and green colouration were all noted. A potential diagnosis of NF was first raised at this point. She received extensive debridement and a pedicle flap (*Pectoralis major*) was used to cover the major vessels of the neck. The initial drains were replaced with new ones.



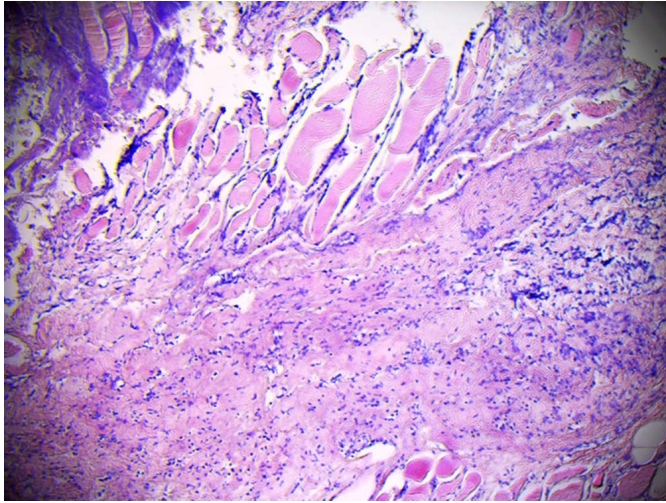
**Fig. 1** Arrows indicating green appearance with necrosis of the platysma, sternomastoid and digastric muscles.

Samples were sent for histopathology, and microbiology and the patient was admitted to the intensive care unit with empirical IV teicoplanin, clindamycin, aztreonam and gentamicin antibiotics. After a microbiology review the same day, the gentamicin and aztreonam were stopped and ciprofloxacin added, following the trust's NF guidelines.

Cultures were positive for gram negative anaerobes, including *veillonella parvula*, susceptible to clindamycin. There was some *pseudomonas aeruginosa* growth as well along with respiratory flora. Teicoplanin was stopped after a 5-day course, but clindamycin and ciprofloxacin were continued for 20 days.

Histology results were received 7 days after the return to surgery. Results showed a chronic inflammatory infiltrate in both the platysma and left parotid lymph node samples. The platysma showed necrosis of fibrocollagenous tissue, and the lymph node also had evidence of necrosis (Figure 2). Both samples were consistent with a diagnosis of necrotising fasciitis.

No further evidence of necrotising fasciitis was identified after the initial return to theatre despite complications with flap healing. A small neck dehiscence noted 24 hours later. A fistula also formed in the submental region causing a saliva leak, that was persistent. The skin layer of



**Fig. 2** Necrotic fibrocollagenous tissue, mixed inflammation spreading across fibrocollagenous tissue and skeletal muscle.

the pedicle flap became non-viable despite muscle granulation and needed debriding twice more prior to discharge. Dressings were changed frequently and included intraoral iodine-based packs.

This patient was discharged 28 days after their initial admission for the primary cancer resection. Despite clear margins at her initial operation two weeks after her discharge she developed a rapidly growing retromolar mass. The biopsy showed a new area of moderately differentiated squamous cell carcinoma. New CT imaging showed spread to the right mandible and pulmonary metastases that developed two months after the initial staging scans. She went to end of life care and passed away 9 weeks after the initial surgery, from widespread metastatic disease.

## CONCLUSION

This is a unique case of a patient developing NF following the resection and reconstruction with a free flap. Early diagnosis of NF is mandatory, and any delay could prove fatal, given its association with more extensive surgery

and higher mortality rates. In specific patient groups (e.g., elderly patients with diabetics) knowing that this is a potential risk factor, may allow early intervention. Diabetes has been established as the most frequent risk factor for NF (2). This patient had moderately controlled type 2 diabetes (pre-operative HbA1c 68 mmol/mol) which was being treated with insulin and metformin. This could have increased this patient's susceptibility to developing this infection. Other common co-morbidities include liver cirrhosis, chronic heart failure, obesity, alcohol abuse, immunodeficiency, hypertension, and peripheral vascular disease (2). Risk assessment before major head and neck operations is essential combine with close post-operative monitoring. Some high-risk patients may benefit from pre-operative antibiotics followed by a longer postoperative course, rather than the 3 doses in total, of our current protocol. Such an approach, in this case presented, allowed for the changes to patient status and the free flap, caused by NF, to be quickly identified, escalated and managed with the patient rapidly returning to theatre. Surgical intervention is lifesaving and must be performed as early as possible, since a delay in treatment beyond 12h can prove fatal.

## CONFLICT OF INTEREST

The authors have no conflict of interest to report

## REFERENCES

1. Bayetto K, Cheng A, Sambrook P. Necrotizing fasciitis as a complication of odontogenic infection: a review of management and case series. *Aust Dent J* 2017; 62, 317–22.
2. Cheng NC, Tai HC, Chang SC, Chang CH, Lai HS. Necrotizing fasciitis in patients with diabetes mellitus: clinical characteristics and risk factors for mortality. *BMC Infect Dis* 2015; 15(1), e9.
3. Dennis S, Bryant AE. Necrotising Soft-Tissue Infections. *N Engl J Med* 2017; 377(23), 2253–65.
4. Lota AS, Altaf F, Shetty R, Courtney S, Mckenna P, Iyer S. A case of necrotising fasciitis caused by *Pseudomonas aeruginosa*. *J Bone Joint Surg* 2010; 92(2), 284–5.
5. Malik A, Chakrabarty S, Nair S, Nair D, Chaturvedi P. Necrotizing fasciitis in patients with head and neck cancer. *Am J Infect Control* 2015; 43, 404–5.
6. Wilson B. Necrotising fasciitis. *Am Surg* 1952; 18(4), 416–31.