

# Duodenal Pressure Necrosis in a Child Caused by a Migrated Percutaneous Endoscopic Gastrostomy

Jan Melek<sup>1,\*</sup>, Markéta Štanclová<sup>1</sup>, Radek Štichhauer<sup>2</sup>, Pavel Rozsival<sup>1</sup>, Jan Kopřiva<sup>3</sup>, Jana Dědková<sup>3</sup>, Eva Terifajova<sup>1</sup>, Eva Šedivá<sup>1</sup>, Petr Dědek<sup>1</sup>, Sylva Skálová<sup>1</sup>, Jan Bureš<sup>4</sup>

## ABSTRACT

A two-year-old girl with two weeks of abdominal pain, vomiting, and food refusal, ten months after percutaneous endoscopic gastrostomy insertion because of inadequate peroral intake, was admitted to a tertiary centre hospital. On admission, the extracorporeal part of the gastrostomy was much shortened. X-ray examination revealed migration of the end of the gastrostomy tube with a left-shifted course of the tube through the duodenum. Gastroscopy and subsequently laparotomy were performed. A longitudinal pressure necrosis was identified under the tube, with two perforations in the duodenojejunal region. Ten centimeters of that duodenojejunal region were resected, and end-to-end anastomosis was made. The migration of the gastrostomy was probably caused by insufficient care by the parents. Pathophysiologically, the tube caused the pressure necrosis in the duodenojejunal area; this was supported by histology. This is a hitherto undescribed complication of a percutaneous endoscopic gastrostomy, showing that migration of the gastrostomy to the deeper part of the small bowel can lead to pressure necrosis, a potentially life-threatening condition in children which cannot be treated without invasive procedures.

## KEYWORDS

children; migration; percutaneous endoscopic gastrostomy; perforation; pressure necrosis

## AUTHOR AFFILIATIONS

<sup>1</sup> Department of Pediatrics, Charles University, Faculty of Medicine in Hradec Králové; University Hospital Hradec Králové, Czech Republic

<sup>2</sup> Department of Pediatric Surgery and Traumatology, Charles University, Faculty of Medicine in Hradec Králové; University Hospital Hradec Králové, Czech Republic

<sup>3</sup> Department of Radiology, Charles University, Faculty of Medicine in Hradec Králové; University Hospital Hradec Králové, Czech Republic

<sup>4</sup> 2nd Department of Internal Medicine – Gastroenterology, Charles University, Faculty of Medicine in Hradec Králové; University Hospital Hradec Králové, Czech Republic

\* Corresponding author: Department of Pediatrics, University Hospital Hradec Králové, Sokolská 581, Hradec Králové, 500 05, Czech Republic; e-mail: jan.melek@fnhk.cz

Received: 24 January 2020

Accepted: 7 May 2020

Published online: 10 August 2020

Acta Medica (Hradec Králové) 2020; 63(2): 79–81

<https://doi.org/10.14712/18059694.2020.21>

© 2020 The Authors. This is an open-access article distributed under the terms of the Creative Commons Attribution License (<http://creativecommons.org/licenses/by/4.0>), which permits unrestricted use, distribution, and reproduction in any medium, provided the original author and source are credited.

## CASE REPORT

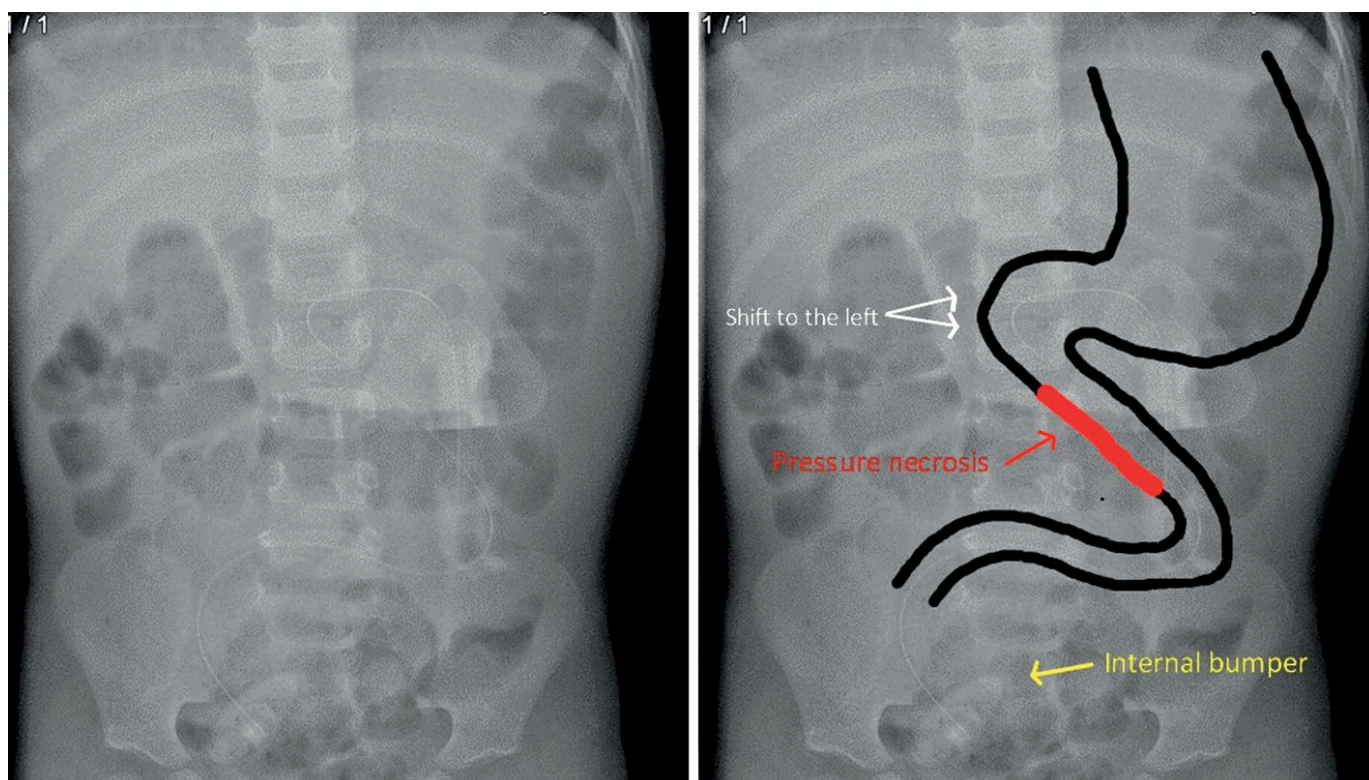
A two-year-old female patient with possible genetic abnormality with percutaneous endoscopic gastrostomy (PEG, Freka® 9 French = 3 mm, Fresenius Kabi) was admitted to a tertiary care center ten months after the tube insertion with a two-week history of intermittent abdominal pain, vomiting, and food refusal. She had no surgical history and was being treated with levothyroxine for mild hypothyroidism. The abdominal ultrasound did not reveal any pathology. Laboratory tests were overall unremarkable, except for mildly elevated C-reactive protein – 23 mg/l (normal: 0–5 mg/l). Stool testing for viruses (adenovirus, rotavirus, and norovirus) and bacteria did not identify any pathogenic agent. Anthropometric measurements were notable for underweight (weight 6.5 kg, –5.0 SD – standard deviation) and short stature (height 78 cm, –2.2 SD) with weight-for-height ratio –4.7 SD. The patient was afebrile, with a soft abdomen and small umbilical hernia. There were no clinical signs of peritoneal irritation. Atypically, the extracorporeal part of the gastric tube was much shortened to 6.5 cm (the regular length from internal bumper to the end of the tube is 31.5 cm).

An abdominal radiograph in standing position (Figure 1) revealed migration of the end of the gastrostomy tube with a left-shifted course of the tube through the duodenum without any other signs of pathology. The tube displacement to the small bowel was verified by the contrast study. Gentle pulling on the tube under radiologic control failed to reposition it. The same day a gastroscopy confirmed migration of the tube from the stomach through the antrum to the duodenum. The first duodenal section appeared normal, the middle was slightly distorted, and

in the distal part was revealed a suspicious ulcer under the tube. The tube seemed to disappear into the bowel wall in the distal duodenum (Figure 2). During the same anesthesia, the surgeon was called and performed a laparotomy. On opening the peritoneal cavity, the pneumoperitoneum was observed. Approximately 40 cm of the duodenum and mainly the jejunum was looped around the tube. Further, there was a longitudinal pressure ulcer with two perforations in the duodenojejunal region under where the tube lay (Figure 3). We did not notice any pathology around the internal bumper. A 10 cm resection of the affected duodenojejunal area was performed. The gastrostomy was removed without any complications, and a duodenojejunal end-to-end anastomosis was performed. The pressure origin of the lesion in the mentioned area was confirmed histologically. For postoperative feeding, a jejunal tube was inserted via the gastrostomy track. The postoperative course was without complications. The jejunal tube was replaced by a Foley catheter 14 days after the operation until a gastrostomy button will be placed. The patient was discharged from the hospital 21 days after the procedure. Five months after the surgery, the girl was without any problems connected to the operation.

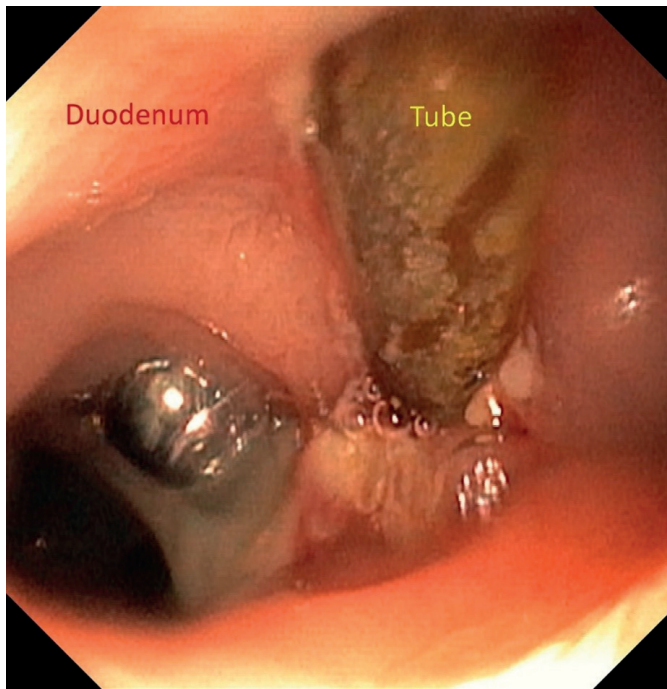
## DISCUSSION

In this case report, we present a two-year-old girl with a hitherto undescribed complication of a percutaneous endoscopic gastrostomy. No genetic background has yet been elucidated in our patient, but we do not expect it would influence the development of this complication. The indication for the PEG placement was failure to thrive. A poly-



**Fig. 1** A – Native x-ray, B – Illustration. The white arrows are showing a left-shifted course of the tube through the duodenum. The red arrow is pointing to the affected area by the pressure necrosis. The yellow arrow is showing internal bumper position.

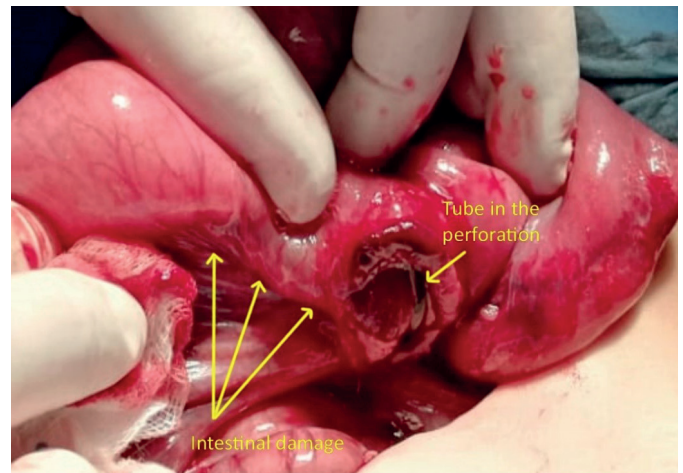




**Fig. 2** Distal duodenum with the dislocated PEG tube. Fibrine plaques around the tube. The tube seems to disappear into the bowel wall.

meric formula (Nutrini®, Nutricia) was administered through the gastrostomy. We do not expect that the tube migration was affected by the PEG placement technique (pull method; insertion at the body and antrum junction), applied according to the ESPGHAN recommendations (1).

We presume that the inadequate care of the PEG tube by the parents played a critical role in the PEG migration, even though the parents were adequately instructed by a doctor and a nurse and the gastrostomy was checked two and six months after the placement. This notion was supported one month after the hospitalization when the girl was readmitted with obstructive ileus caused by migration of the Foley catheter with obstruction of the first part of the duodenum by the balloon. However, it can be accepted that a Foley catheter can be more challenging to take care of because there is no external fixation plate. We predict the child may benefit from a gastrostomy button or a balloon gastrostomy. Apart from that, we did not notice any other signs of deficient care or signals indicating child abuse and neglect syndrome. The mentioned clinical signs (abdominal pain, vomiting) could be consistent with the duodenal damage (2), but they could also be evoked by the unintentional “bolus” feeding to the small bowel. Pathophysiologically, we assume the injury in the duodenojejunal area was caused by pressure necrosis induced by the tube (3). We suspect that this damage, as well as the left shift of the course of the tube through the duodenum, were exaggerated by pull on the tube by the peristalsis. Although we did not notice any perforation during the endoscopy, we suspect the artificial inflation in combination with the severely affected area could cause definitive rupture of the bowel wall. Nevertheless, based on the peripor-



**Fig. 3** Longitudinal bowel injury with the perforation and the tube in the duodenojejunal region.

erative finding supported by histology, it was proven that the major duodenal damage was caused by the migrated tube.

In conclusion, we showed that migration of the gastrostomy to the deeper part of the small bowel could not be treated without invasive procedures, and moreover can lead to a very severe or even life-threatening condition. In the case of “inappropriate” external shortening of the tube in a young child, we suggest providing an x-ray imaging study with the perspective that other more invasive examination methods may be needed. If this type of complication is proven, the patient will probably require an acute surgical procedure.

#### ACKNOWLEDGEMENTS

The authors are grateful to Ian McColl, MD, PhD for assistance with the case report manuscript.

#### CONFLICT OF INTEREST

None declared.

#### FUNDING

The study was not funded.

#### REFERENCES

1. Heuschkel RB, Gottrand F, Devarajan K, et al. ESPGHAN position paper on management of percutaneous endoscopic gastrostomy in children and adolescents. *J Pediatr Gastroenterol Nutr* 2015; 60(1): 131–41.
2. Saranga Bharathi R, Rao P, Ghosh K. Iatrogenic duodenal perforations caused by endoscopic biliary stenting and stent migration: an update. *Endoscopy* 2006; 38(12): 1271–4.
3. Kim HS, Moon HJ, Lee NY, et al. Endoscopic management of duodenal perforations caused by migrated biliary plastic stents. *Endosc Int Open* 2019; 7(6): E792–E5.