

Hydrocele in Pediatric Population

Ioannis Patoulas¹, Efstathios Koutsogiannis², Ioannis Panopoulos², Panagiota Michou²,
Thomas Feidantsis¹, Dimitrios Patoulas^{3,*}

ABSTRACT

Hydrocele is a collection of fluid within the tunica vaginalis. Based upon the etiology and the pathophysiology, it is divided into, the primary and secondary. The primary hydrocele includes the neonatal or the congenital, the communicating and the non-communicating or the closed or the adult type. The secondary hydrocele can develop in the substrate of a pre-existing disease. After systematic and thorough systematic and thorough research of the relevant literature, we aim at describing all the aspects of this entity, with specific emphasis on the issues that remain unanswered from the scientific community.

KEYWORDS

congenital hydrocele; communicating hydrocele; closed or adult type hydrocele; secondary hydrocele; processus vaginalis; Nuck canal

AUTHOR AFFILIATIONS

¹ First Department of Pediatric Surgery, Aristotle University of Thessaloniki, General Hospital "G. Gennimatas", Thessaloniki, Greece

² Department of Pediatrics, General Hospital "G. Gennimatas", Thessaloniki, Greece

³ First Department of Internal Medicine, General Hospital "Hippokration", Thessaloniki, Greece

* Corresponding author: M. Alexandrou 3B, Pefka, Thessaloniki, Postal code 57010, Greece; e-mail: dipatoulas@gmail.com

Received: 26 September 2019

Accepted: 10 March 2020

Published online: 10 August 2020

Acta Medica (Hradec Králové) 2020; 63(2): 57–62

<https://doi.org/10.14712/18059694.2020.17>

© 2020 The Authors. This is an open-access article distributed under the terms of the Creative Commons Attribution License (<http://creativecommons.org/licenses/by/4.0>), which permits unrestricted use, distribution, and reproduction in any medium, provided the original author and source are credited.

ETIOLOGIC CLASSIFICATION

Hydrocele is the collection of fluid within the tunica vaginalis of the testis. Based on the pathophysiological substrate, it is divided into primary and secondary. The primary hydrocele includes the neonatal or the congenital, the communicating and the non-communicating or closed type (1).

The secondary hydrocele can develop on the grounds of a pre-existing disease such as inflammation (epididymitis, epididymo-orchitis), testicular torsion or its embryonic appendages (appendiceal torsion), previous surgical intervention in the inguinal region or scrotum (e.g. varicocelectomy), hypoproteinemia due to a systemic disease and trauma or tumor of the intrascrotal structures. In third-world countries parasitic diseases (lymphatic filariasis, *Wuchereria bancrofti* etc.) are common causes of secondary hydrocele (2).

In the context of patent processus vaginalis pathology, the following disorders may occur: the processus vaginalis is almost obliterated from the level of the internal inguinal orifice. The rest of it fills with fluid which descends from the peritoneal cavity, so we have the neonatal or congenital hydrocele.

When the processus vaginalis remains obliterated on either side of a complete with fluid cavity, it is referred as a cystic hydrocele or a cyst of the spermatic cord. When the processus vaginalis is patent in its entire length, the result is the communicating hydrocele.

A particular entity is the abdomino-inguino-scrotal hydrocele. It is believed that the cause is the presence of a valve type obstruction of the processus vaginalis above the internal inguinal orifice. The fluid is collected up to the level of the internal inguinal orifice. In contrast to the large compliance of the scrotum, the inguinal canal is relatively small, due to its fibromuscular nature. The accumulated fluid within the processus vaginalis causes the development of high pressure at the internal inguinal orifice. However, this pressure overcomes the intra-abdominal one, then the hydrocele spreads intra-abdominally and so the abdominal part of the abdomino-inguino-scrotal hydrocele is formed. The collected fluid can be spread both intraperitoneally and retroperitoneally (3).

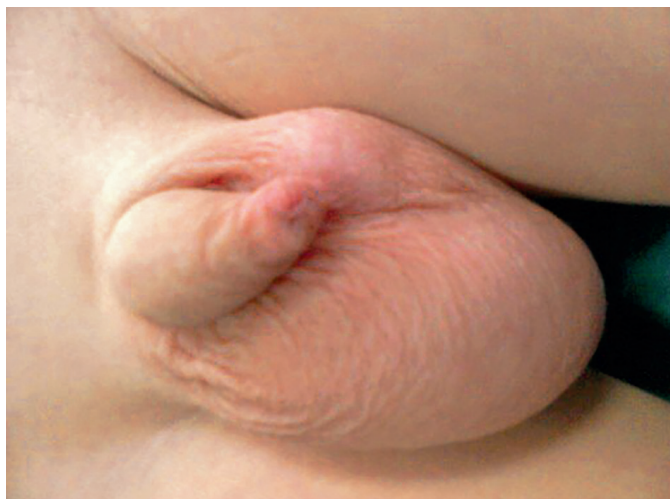

Fig. 1 Congenital hydrocele.

The non-communicating or closed type hydrocele most often manifests in prepubertal age. The mechanism of development remains unknown. It has been suspected that the cause could be a small communication between the processus vaginalis and the peritoneum that remains asymptomatic during early childhood and manifests later. However, with the surgical confirmation of an absence of a patent processus vaginalis, this hypothesis is disputed. Koutsoumis et al conducted a biochemical analysis of the fluid in 13 patients with a closed type hydrocele and found that it was serous fluid in all cases (4).

According to the latest postulation, the primary non-communicating hydrocele is caused by a disorder in the balance between the rate of production and reabsorption of the fluid from the tunica vaginalis epithelial cells. Therefore, it concerns either an increased rate of production, or a reduced rate or reabsorption of the collected fluid within the tunica vaginalis (4, 5).

EMBRYOLOGY

The processus vaginalis develops as a peritoneal protrusion during the 12th embryonic week. Gradually it exits from the internal inguinal orifice, it traverses the inguinal canal and in girls, it is inserted in the pubic tuberculum. In boys, it reaches the scrotum with its last part forming the two layers of the tunica vaginalis which surrounds in part the homolateral testis. The processus vaginalis takes part catalytically in the testicular descent from the lumbar region to the scrotum, like a "hydraulic" force.

After birth, the progressive obliteration of the processus vaginalis continues. Because the descent of the left testis is completed earlier, the obliteration of the right processus vaginalis is delayed (6). This fact explains the prevalence of right-side manifestation of the entities in the context of patent processus vaginalis (7). The processus is patent in 80–94% of newborn boys. Sachs proved that in ages ranging from 4 to 12 months, it remains patent in 57% of infants (8). Autopsy studies of adults showed that the processus vaginalis is patent in 5% (5–37%) of cases (9). In 80–88% of adult males the processus vaginalis is turned into a fiber chord after its obliteration. In females

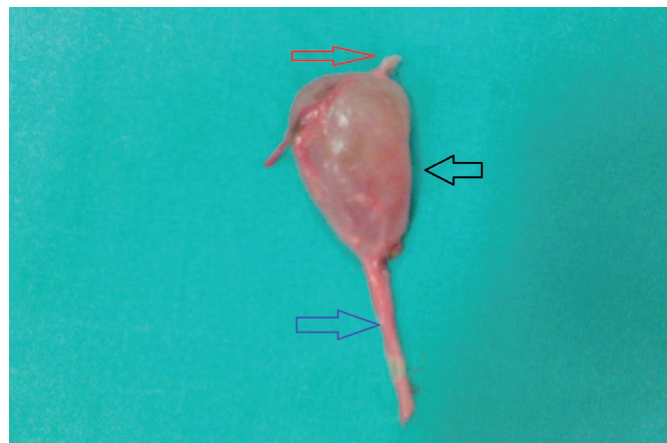


Fig. 2 Spermatic cord hydrocele. Notice the distal part of processus vaginalis (red arrow), the cyst (black arrow) and the proximal part of processus vaginalis (blue arrow).

the corresponding structure is called the Nuck canal and it reaches the ipsilateral major labium.

The existence of a patent processus vaginalis is an essential but not catalytic factor for the development of an indirect inguinal hernia, because only 8–12% of adults develop indirect inguinal hernia (10).

Hutson et al. claim that the androgen-dependent action of the genitofemoral nerve through the secretion of a neuropeptide (calcitonin gene-related peptide, CGRP) is responsible for the physiologic obliteration of the processus vaginalis (11). Reduced secretion of CGRP prenatally causes disorders in the descent of the testis, while the reduced secretion antenatally leads to inguinal hernia or hydrocele. CGRP causes in vitro obliteration of the processus vaginalis in infants with inguinal hernia. Initially the peptide acts on the fibroblasts of the wall of the processus vaginalis, in which the presence of CGRP receptors have been documented. The mechanism however by which these changes occur in the mesothelium of the processus vaginalis that have been observed in vitro studies and the following obliteration have not been clarified yet (11, 12).

Tanye et al. believe that the failure of obliteration of the processus vaginalis is caused by the presence of smooth muscle fibers in its wall. This hypothesis is based on studies in which increased expression of different markers, such as actin and desmin in the processus vaginalis wall of patients with inguinal hernia or communicating hydrocele, were recorded (12). Based on these observations, the existence of smooth muscle fibers was proven in the wall of a patent processus vaginalis, in contrast to their absence from a normally obliterated one. However, the exact mechanism by which the smooth muscle fibers keep the processus patent is not completely understood.

The degeneration of myofibroblasts induces the apoptosis of the smooth muscle fibers and the mesothelium of the processus vaginalis, which leads to its obliteration. Therefore, disorders in this procedure cause disturbance in the normal obliteration of the processus vaginalis (12, 13).

It has been estimated that the quantity of smooth muscle fibers that remain on the wall of the processus vaginalis, correlates with the manifestation of either hydrocele-less), or inguinal hernia(more). In the above mechanism, the autonomic nervous system and activity of androgen disorders are involved, since these two factors are considered to affect the smooth muscle fibers. The androgens affect the fibers both directly and indirectly through the sympathetic nervous system, which has an androgen dependent activity. The sympathetic innervation plays an important trophic role for the smooth muscle fibers, increasing the intracellular cAMP through β -adrenergic receptors. Consequently, with the reduction of the activity of the sympathetic nervous system and the reactive increase in the parasympathetic activity, the smooth muscle cell apoptosis is induced (13).

Especially in females, due to a smaller number of sympathetic nerve fibers, the sympatholytic activity causes apoptosis of the smooth muscle fibers on the walls of the Nuck canal. Based on this analysis, the rarer manifestation of inguinal hernia in females might be explained (13, 14).

CLINICAL MANIFESTATION AND EVOLUTION

Due to a progressive obliteration of the processus vaginalis, the neonatal or congenital hydrocele is reversed on its own in 63–89% of cases until the age of 12–24 months (15, 16). Indeed, this obliteration is completed within the first six months of life in 75% of cases (1).

If the processus vaginalis remains patent, however, then the communicating hernia develops. The communicating hydrocele usually presents during infancy and is bilateral. The increase and decrease of swelling are pathognomonic findings.

Hydrocele must be differentiated from the inguinal hernia especially when it expands to the scrotum. The cervix of the hydrocele is narrow at the level of the external inguinal orifice, in contrast to the inguinal hernia which expands into the inguinal canal. The content of the inguinal hernia can be repositioned, while the hydrocele one cannot be repositioned. The latter is difficult to assess in neonates and infants, especially if it concerns a hydrocele under pressure. In this case, a digital rectal examination is necessary to exclude an incarcerated inguinal hernia. During the effort of repositioning a hydrocele under pressure, the fluid can be directed internally through the external inguinal orifice, giving the impression of repositioning an incarcerated inguinal hernia. The hydrocele, however, is mobile and painless, while the inguinal hernia is fixed to the wall of the inguinal canal and is painful during palpation. Transillumination can contribute diagnostically, however an incarcerated air-filled intestinal helix can appear similarly to a hydrocele.

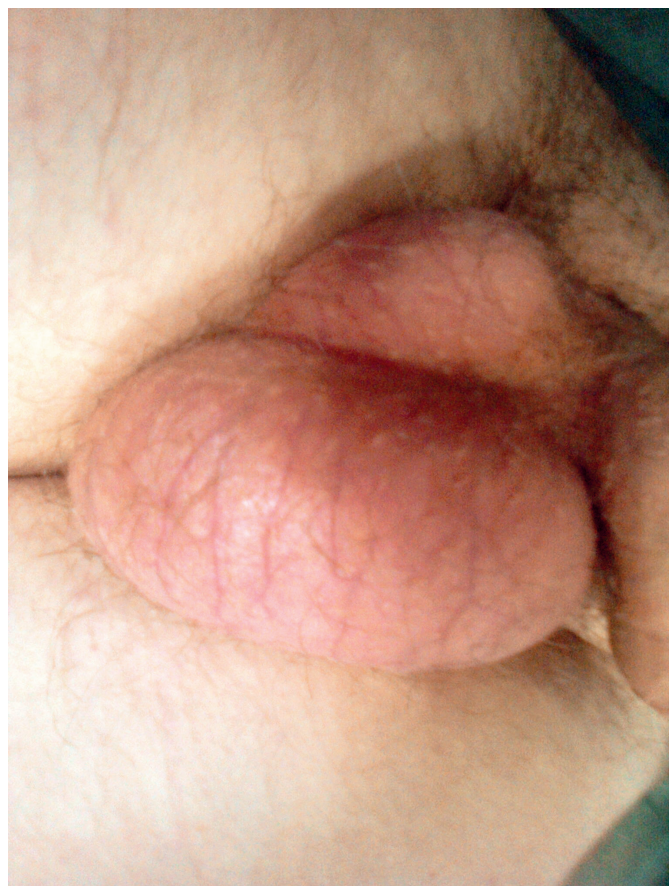

Fig. 3 Adult type hydrocele.

The congenital or neonatal hydrocele should not worry the parents as in most cases it subsides within the first year of life. A periodic follow-up is required every 3–6 months during this period. Urgent evaluation may be required if it suddenly increases in size or pressure develops. If the hydrocele persists beyond first 1–2 years of life, then it possibly concerns a communicating one. Before the last 15 years, most pediatric surgeons were aggressive concerning the time of treatment, assuming it was potentially an inguinal hernia. Today a more conservative approach is followed (17). Besides that, the probability of inguinal hernia is less than 5% and without a reported episode of incarceration (16). A longer follow-up, however, is usually required.

In cases of delayed manifestation of hydrocele, Christensen et al. believe that the indication for surgical intervention is better to be set after a monitoring period of 6–9 months, during which there is a 75% chance of reversion (18). In spermatic cord hydrocele, surgical intervention is recommended, if it persists beyond the age of 18 months (16, 18).

In conclusion, the advised strategy is to avoid surgical procedure during the first 2 years of life, except for the following cases: a) the existence of inguinal hernia cannot be excluded, b) it concerns a large, symptomatic and under pressure hydrocele and c) it concerns a communicating hydrocele with frequent increase and decrease of its size, a fact that means that a great volume of fluid is being transferred between the peritoneal cavity and the processus vaginalis, so its width is large, suggesting a potential inguinal hernia. After the first two years of life the hydrocele must be surgically corrected if it does not tend to subside or if it manifests acutely, as at this age its reversion is extremely rare.

PRINCIPLES OF MANAGEMENT

The basis of the communicating hydrocele operative management is the high ligation of the processus vaginalis

at the level of the internal inguinal orifice with creation of a fenestration in the homolateral tunica vaginalis. Reversion of the tunica vaginalis is not required (Bottle procedure) (6, 19). Reversion of the tunicae is indicated in a hydrocele under pressure as well, as in cases, where the tunica vaginalis is thickened, by fibrotic and with elements of inflammation (6, 19).

In tense neonatal hydrocele, in abdomino-scrotal hydrocele and in closed type hydrocele the procedure can be performed via scrotal approach with trans-scrotal incision. Tunica albuginea reversion, with or without tunica vaginalis excision, along with joining the tunicae with sutures in the posterior surface of the testis, without spermatic cord compression (Lord method), is recommended (2–5).

The advantages of the scrotal approach include a better aesthetic result, reduction in operative time and no danger of damaging the ilioinguinal nerve (2–5).

POSTOPERATIVE HYDROCELE

The most characteristic example includes the hydrocele that is formed in the ipsilateral hemi-scrotum – usually the left – after varicocelectomy. Usually they develop within 2–22 months after surgery, although cases observed more than 6 years after surgery have been reported (20, 21). Possibly, in most cases, the post-surgical follow-up period is short, thus cases of hydrocele that develop late can be missed. It is not considered a relapse, since pre-surgically hydrocele does not exist. This entity affects 1–40% of males that have undergone varicocelectomy (22, 23). Etiologically it is believed that the cause is destruction or blockage of the lymphatic vessels, whose course is parallel to the internal spermatic vessels. It has been established that the hydrocele improves and reverses in 14–60% of cases, either due to development of collateral lymph circulation or re-growth of the blocked lymphatic vessels (20, 21).

In cases when the postoperative hydrocele persists beyond the first year after varicocelectomy, its surgi-

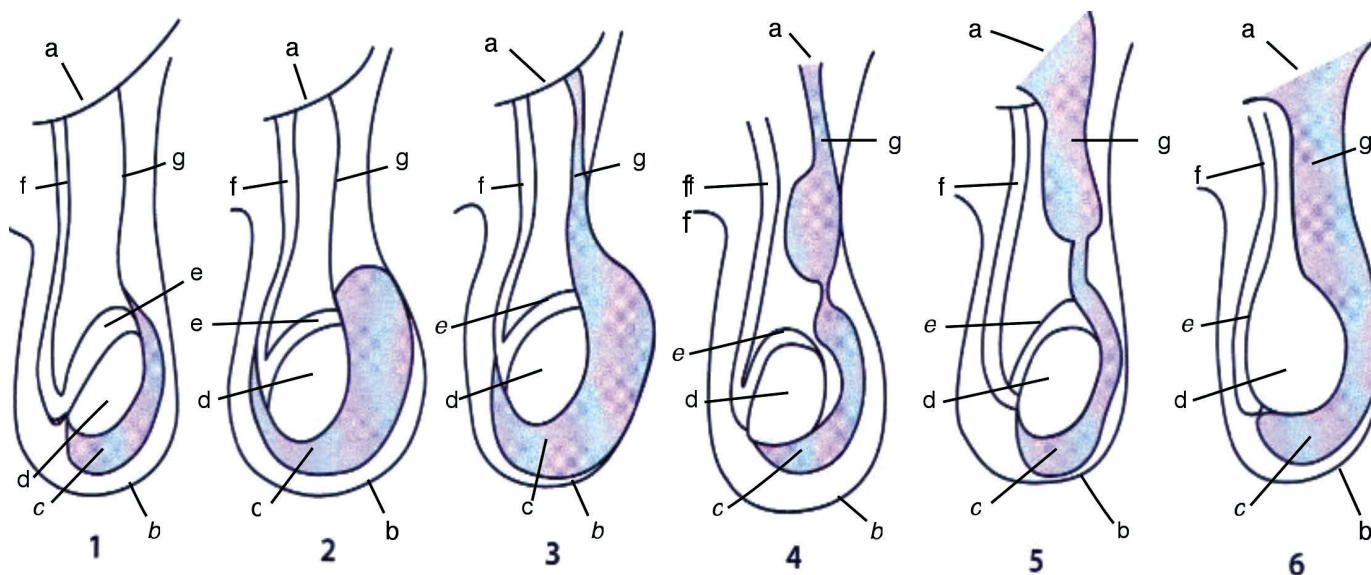


Fig. 4 1. Normal anatomy, 2. Adult type hydrocele, 3. Communicating hydrocele, 4. Spermatic cord hydrocele, 5. Inguinal hernia, 6. Inguinoscrotal hernia; a. peritoneal cavity, b. scrotum, c. tunica vaginalis, d. testis, e. epididymis, f. spermatic duct, g. processus vaginalis.

cal management is indicated. Initially, aspiration under aseptic conditions is recommended and, if it relapses, hydrocelectomy by scrotal approach is required. It should be noted that the possibility of relapse is much greater than the documented in other cases of hydrocele. Esposito et al. in their small series observed that 2 out of 6 cases with postoperative hydrocele in the context of varicocelectomy finally relapsed (22).

HYDROCELE RECURRENCE

Recurrence usually develops after the treatment of inguinal hernia or hydrocele of the homolateral inguinal region. Commonly, this occurs several months postoperatively. Morecroft et al. treated 556 males with hydrocele or inguinal hernia and observed that 8 out of 556 (1.4%) developed hydrocele postoperatively (23). Ein et al. treated 5,343 males with hydrocele or inguinal hernia and postoperative hydrocele developed only in 2 patients (0.038%) (24). Davies et al. found that the hydrocele recurrence was greater (11%) when the male patients that had undergone surgery for hydrocele or inguinal hernia weighted less than 3 kilograms (25). In the contrary, Moss et al. demonstrated that only 2 out of 328 neonates (0.6%) experienced hydrocele recurrence (26).

There is no algorithm concerning the surgical strategy that should be followed for this complication (21, 27). The first step is the observational approach for at least 6 months. The next step is the trans-scrotal paracentesis and the absorption of the fluid with the use of a needle under aseptic conditions and local anesthesia, in cases when the hydrocele persists, or the volume of the collected fluid increases, or local discomfort appears. A contraindication for this procedure is the existence of homolateral inguinal hernia or communicating hydrocele.

Surgical management is advised if the fluid aspiration – which can be repeated up to 5 times – does not solve the problem. Surgical intervention can be performed either via scrotal or inguinal incision. The majority of pediatric surgeons prefer the inguinal approach, as this allows the exploration and correction of a potential inguinal hernia or a communicating hydrocele.

The inguinal approach is also advised in those cases, in which the first operation was performed trans-scrotally, because the anatomy and the potential presence of inguinal pathology were not thoroughly assessed.

NUCK'S HYDROCELE

Nuck's hydrocele concerns a communicating hydrocele in females resulting from the persistence of a patent Nuck's canal, the equivalent of the processus vaginalis in males. Nuck's canal was named after the Dutch Anton Nuck, who first described this anatomic entity (28). This peritoneal protrusion accompanies the round ovarian ligament in its extra-abdominal course. It passes through the inguinal canal and attaches to the ipsilateral pubic tuberculum. The wall of this peritoneal protrusion is comprised of mesothelial cells with single or multi-layered cuboidal

or cylindrical epithelium internally, which are surrounded by a thick fibrotic connective tissue, which is in turn traversed by bundles of smooth muscle fibers.

It is possible for the Nuck's canal to obliterate, resulting in fluid accumulation within the canal due to an imbalance between the production rate from the mesothelial cells and the rate of its absorption.

Nuck's hydrocele can be classified into 4 types (29):

- the equivalent to the spermatic cord cyst in males,
- the equivalent to communicating hydrocele in males,
- the “hour glass” type or the type of two-space hydrocele. In this type, two cavities are observed, one peripheral, closed type and one central that communicates with the peritoneal cavity through the patent Nuck's canal,
- the equivalent to the non-communicating or closed type hydrocele in males.

It is a rare entity, as relevant literature mainly consists of case reports or small case studies. In general, Nuck's hydrocele is 8 times rarer than the communicating hydrocele in males (28, 29). It is characterized by painless and non-reversible swelling, usually mobile, with well-defined boundaries, located in the right inguinal region that can expand to the ipsilateral major labium of the vagina. Swelling can range from 2.3 to 5.6 cm (28). The physician must differentiate it from an incarcerated inguinal hernia or an incarcerated femoral hernia, especially from one which contains ovary or part of the small intestine or omentum or a lipoma, the soft tissue tumors of the inguinal area and the inguinal region lymphadenopathy.

It is worth highlighting that 98.7% of cases of swelling of the inguinal region in females correspond to an inguinal hernia and only 0.76% to Nuck's hydrocele (28).

Diagnosis is confirmed by ultrasonography. Major findings are the hypo-echoic or anechoic content, the single cavity or multiple cavities with thin septa and the depiction of the “comma sign” (29). Rarely, magnetic resonance imaging may be required.

Treatment of choice is the ligation of the Nuck's canal at the level of internal inguinal orifice – as long as it is patent – and its removal down to its peripheral attachment to the homolateral pubic tuberculum (29).

CONFLICT OF INTEREST

None declared.

REFERENCES

1. Dave J. Cause and management of hydrocele: a review article. *Indian J of Applied Research* 2015; 5: 117–8.
2. DeVries C. The role of urologist in the treatment and elimination of lymphatic filariasis worldwide *BJU Int* 2002; 89: 37–43.
3. Belman AB. Abdominoscrotal hydrocele in infancy: a review and presentation of the scrotal approach for correction. *J Urol* 2001; 165: 225–7.
4. Koutsoumis G, Patoulas I, Kaselas C. Primary new-onset hydroceles presenting in late childhood and pre-adolescent patients resemble the adult type hydrocele pathology. *J Pediatr Surg* 2014; 49: 1656–8.
5. Wilson JM, Aaronson DS, Schrader R, Baskin LS. Hydrocele in the pediatric patient: inguinal or scrotal approach? *J Urol* 2008; 180: 1724–8.
6. Holcomb GW, Murhy JP, Ostlie DJ: *Ashcraft's Pediatric Surgery*. 6th edition. Elsevier, Saunders Co: New York 2014, Chapter 50, pp 679–88.

7. Harper RG, Garcia A, Sia C. Inguinal hernia: A common problem of premature infants weighing 1,000 grams or less at birth. *Pediatrics* 1975; 56: 112–5.
8. Chevrel IP. *Surgery of the abdominal wall*. Springer Verlag: Berlin 1987.
9. Gray SW, Skandalakis JE. *Embryology for surgeons*. 2nd ed. Baltimore: Williams & Wilkins 1994, pp 540–93.
10. Celik A, Ergón O, Arda MS, et al. The incidence of inguinal complications after ventriculoperitoneal shunt for hydrocephalus. *Childs Nerv Syst* 2005; 21: 44–7.
11. Hutson JM, Hasthorpe S, Heyns CF. Anatomical and functional aspects of testicular descent and cryptorchidism. *Endocr Rev* 1997; 18: 259–80.
12. Hutson JM, Albano FR, Paxton G, et al. In vitro fusion of human inguinal hernia with associated epithelial transformation. *Cells Tissues Organs* 2000; 166: 249–58.
13. Tanyel FC, Okur HD. Autonomic nervous system appears to play a role in obliteration of processus vaginalis. *Hernia* 2004; 8: 149–54.
14. Hosgor M, Karaca I, Ozer E, et al. The role of smooth muscle cell differentiation in the mechanism of obliteration of processus vaginalis. *J Pediatr Surg* 2004; 39: 1018–23.
15. Naji H, Ingolfsson I, Isacson D, et al. Decision making in the management of hydroceles in infants and children. *Eur J Pediatr* 2012; 171: 807–10.
16. Koski M, Makari J, Adams M. Infant communicating hydroceles—do they need immediate repair or might some clinically resolve? *J Pediatr Surg* 2010; 45: 590–3.
17. Antonoff MB, Kreykes NS, Saltzman DA et al. American Academy of Pediatrics Section on surgery hernia survey revisited. *J Pediatr Surg* 2005; 40: 1009–14.
18. Christensen T, Cartwright PC, Devries C, Snow BW. New onset of hydroceles in boys over 1 year of age. *Int J Urol* 2006; 13: 1425–7.
19. Andrews EW. The “Bottle Operation” method for the radical cure of hydrocele. *Ann Surg* 1907; 46: 915–8.
20. Chang Y-T, Lee J-Y, Wang J-Y, et al. Hydrocele of the spermatic cord in infants and children: Its particular characteristics. *Urology* 2010; 76: 82–6.
21. Glick PL, Boulanger SC. Inguinal hernias and hydroceles. In: Grosfeld JL, O’Neill JA Jr, Fonkalsrud EW, Coran AG, (eds.), *Pediatric surgery*. 6th edition. Vol. 2. Philadelphia: Mosby 2006: 1172–92, Chapter 30 / Recurrent Hernia, Hydrocele, and Varicocele, p 485.
22. Esposito C, Montupet P. Laparoscopic treatment of recurrent inguinal hernia in children. *Pediatr Surg Int* 1998; 14: 182–4.
23. Morecroft JA, Stringer MD, Homes SJK, et al. Follow-up after inguinal herniotomy or surgery for hydrocele in boys. *Br J Surg* 1993; 80: 1613–4.
24. Ein SH, Njere I, Ein A. Six thousand three hundred sixty-one pediatric inguinal hernias: a 35-year review. *J Ped Surg* 2006; 41: 980–6.
25. Davies BW, Fraser N, Najmaldin AS, et al. A prospective study of neonatal inguinal herniotomy: the problem of the postoperative hydrocele. *Pediatr Surg Int* 2003; 19: 68–70.
26. Moss RL, Hatch EI. Inguinal hernia repair in early infancy. *Am J Surg* 1991; 161: 596–9.
27. Lloyd DA. Inguinal and femoral hernia. In: Ziegler MM, Azizkhan RG, Weber TR, (eds.), *Operative pediatric surgery*. New York: McGraw-Hill 2003, p 543.
28. Akkoyun I, Kucukosmanoglu I, Yalinkilinc E. Cyst of the canal of Nuck in pediatric patients. *N Am J Med Sci* 2013; 5: 353–6.
29. Stickel WH, Manner M: Female hydrocele (cyst of the canal of Nuck): sonographic appearance of a rare and little-known disorder. *J Ultrasound Med* 2004; 23: 429–32.

Robotic Management of Fibroids: Discussion of Use, Criteria and Advantages

Ioannis D. Gkegkes^{1,*}, George Iatrakis², Paraskevi-Evangelia Iavazzo³, Konstadia Bakalianou⁴, Christos Iavazzo³

ABSTRACT

Fibroids are the most common benign tumors affecting fertility and quality of life. Different methods either definitive or fertility sparing are used for their management by using open, laparoscopic and robotic techniques. This is a narrative review presenting the role and the advantages of robotic surgery in fibroids (myomectomies or hysterectomies). Such a management is effective, safe and feasible in hands of well-trained teams even for multiple, large or deep located fibroids.

KEYWORDS

leiomyoma; fibroid; myomectomy; da Vinci®; robot; treatment

AUTHOR AFFILIATIONS

¹ Department of Surgery, Royal Devon and Exeter NHS Foundation Trust, Exeter, UK

² Department of Obstetrics and Gynaecology, Technological Educational Institution of Athens, Athens, Greece

³ Gynaecological Oncology Department, Metaxa Cancer Hospital, Piraeus, Greece

⁴ Department of Obstetrics and Gynecology, General Hospital "Agia Olga", Athens, Greece

* Corresponding author: 11 Tuckfield House, Residential Village, EX2 5DS, Bovemoors Lane, Exeter, UK; e-mail: ioannisgkegkes@gmail.com

Received: 19 May 2019

Accepted: 21 April 2020

Published online: 10 August 2020

Acta Medica (Hradec Králové) 2020; 63(2): 63–66

<https://doi.org/10.14712/18059694.2020.18>

© 2020 The Authors. This is an open-access article distributed under the terms of the Creative Commons Attribution License (<http://creativecommons.org/licenses/by/4.0>), which permits unrestricted use, distribution, and reproduction in any medium, provided the original author and source are credited.

INTRODUCTION

Fibroids are the most common benign uterine tumors deriving from the smooth muscle cells of the myometrium. They can cause uterine bleeding, pain, pressure symptoms and infertility (1). Depending on their anatomic location they are characterised as subserosal, intramural, submucosal and pedunculated fibroids. Ultrasound is the most widely used modality for fibroids diagnosis due to its availability and cost-effectiveness. Magnetic resonance imaging (MRI) is the best modality for visualizing the size and location of all uterine myomas and rule out adenomyosis. However, due to the expense of MRI, its use is best reserved for surgical planning for complicated procedures (2). Initially, expectant management could be a reasonable option for some women with fibroids or, “empirically”, fibroids are treated conservatively either with progestin-only treatments or combined hormonal contraceptives or GnRH analogues (3). However, they are the primary indication of hysterectomies in order to have a definitive treatment. Their management could also be fertility sparing if that is possible by performing myomectomy or uterine embolization (1). Laparoscopic or open techniques, depending on each surgeon’s preference and experience, are offered as treatment options while recently robotic procedures are also suggested.

The da Vinci® surgical system (Intuitive Surgical, Sunnyvale, California) received FDA approval in 2005. Robotic procedures have been introduced in order to improve surgical performance. Increased dexterity, greater range of motion and better depth perception are the main advantages of robotic-assisted techniques. Its limitations include lack of tactile feedback and increased cost. Robotic procedures combine the advantages of open and laparoscopic procedures and are another alternative in the management of fibroids either with myomectomy or with hysterectomy (4).

The aim of this narrative review is to present the use, the criteria and the advantages of robotic surgery in the treatment of fibroids.

DISCUSSION

Different techniques including open, laparoscopic or robotic procedures are “concurrently” used in the management of fibroids and robotic-assisted procedures are becoming more common (4). The patient is preoperatively assessed with imaging scans including ultrasound and MRI and she signs the informed consent when she is informed about the type of planned procedure and possible risks of it including infection, bleeding and injury of adjacent organs. “A little arbitrarily”, candidates for robotic myomectomy are all the patients with any single myoma <15 cm or with <15 myomas in total while palpation of the uterine fundus above the umbilicus, with diffuse adenomyosis or a uterine cavity which cannot be clearly visualized by imaging techniques are contraindications of robotic myomectomy (5). In these cases, a total or subtotal hysterectomy could be performed.

Patient is operated in dorsal lithotomy position in Allen stirrups with the arms padded and tucked. After trocar

placement, the patient would lie in Trendelenburg position. The assistant’s laparoscopic port is used for suction/irrigation, passage of needles, tissue retraction, and morcellation. The most commonly used robotic instruments are Cadiere or Maryland bipolar forceps, harmonic shears, and mega or large needle driver. Initially, the fibroid location is exactly determined and then vasopressin is injected into the myometrium surrounding the fibroid. An incision is performed over the fibroid in a longitudinal or horizontal axis followed by enucleation of it by using a robotic tenaculum and/or a bipolar coagulator in addition to the harmonic shears. The assistant could also help by additional traction with a laparoscopic tenaculum. Multilayer closure employing barbed sutures is usually performed. The specimen is morcelated by taking care of the adjacent tissues especially the bowel and the specimen is retrieved through the assistant’s port.

Regarding the surgical steps of a robotic hysterectomy, two Vicryl® sutures are put on the cervix and then the uterus is instrumented with manipulator and a cervical cap is tied with the sutures. An indwelling foley catheter is also used at outset. Then, uncomplicated Veress needle is fitted and pneumoperitoneum and trocars insertion are performed followed by side docking and instrumentation. Usually, the bipolar diathermy (DT) is set at 40 and the scissors are put through the right main port with monopolar DT at 40 cut and coagulation. Cadiere or Maryland forceps are placed in the third arm. Then, after incising with monopolar DT, the broad ligaments are entered and the ureters are identified bilaterally. The infundibulopelvic pedicles and round ligaments are “taken” with bipolar and/or monopolar DT. The uterovesical fold is taken with monopolar DT and reflection of the bladder follows. The uterine vessels are then skeletalised and taken with bipolar and monopolar DT. The vagina is entered anteriorly on top of the manipulator’s cervical cap and the dissection is continued circumferentially using monopolar DT. The uterine specimen could be extracted through the vagina, through a mini-laparotomy or morcellated depending on its dimensions and suspicion for malignancy. The vaginal vault is then closed with continuous barbed suture. Regarding the postoperative care, the patients are early mobilised and usually are discharged the first postoperative day. In future pregnancies, the risk of uterine rupture is very low when the myometrium is appropriately repaired (6).

Robotic system preserves the advantages of conventional laparoscopy while it offers the possibility to the gynaecologist to operate with more dexterity on the uterus, especially when performing a myomectomy. The articulated instruments permit a wide range of motions while they increase the ability of the surgeon to work efficiently. The 3-dimension stereoscopic vision by the use of binocular optics, the filtration of the tremor and the less operator fatigue are some of the obvious advantages of such operations. It is suggested that a diagnostic laparoscopy should be used in order to clarify the exact positions of the trocars in order to have uncomplicated access to the pelvis. Robotic procedures can be safely performed after taking into account the physiological changes of pneumoperitoneum and steep Trendelenburg position during a preoperative anaesthetic review (7). The CO₂ pressure required

for exposure is often lower in correlation with traditional laparoscopy as result of the mechanical lift of the robot (8). All the above mentioned advantages can lead to more anatomical procedures.

A recent meta-analysis revealed that robotic procedures have significant short term benefits compared to open surgery but the results were found to be similar to laparoscopic procedures (9). It was shown that there is no significant difference in number and weight of fibroids or operating times when comparing robotic with laparoscopic or open myomectomy (10, 11). However, blood loss is less in the robotic group (10). When comparing robotic with open myomectomies, although the operative time is double (261 versus 125 minutes), the hospital stay was half the days in the robotic cases (1.5 versus 2.7 days) (12). In all those studies, the rates of conversion to open surgery and blood transfusion are minimal. The most common reason of conversion is the location or the volume of the fibroid and/or the lack of experience of the surgeon. Regarding the pregnancy outcomes after robotic myomectomies, a cohort study revealed that the mean time to conception was 12.9 ± 11.5 months, spontaneous abortions occurred in 18.9%, while preterm delivery in 17.4% of the achieved pregnancies. The uterine rupture rates were 1.1% (13). Another study showed that the pregnancy rate is 69% and the natural conception rate 55% after robotic myomectomies (14). Additionally, preoperative obesity is not a contraindication or risk factor of poor outcome for women undergoing robotic myomectomy (15). So, the robotic assisted surgery also permits the realization of a key hole operation (at most 10 to 12 mm) (8) which can be interpreted into significantly less blood loss, less pain, shorter recovery time as well as shorter hospital stay, quicker return to normal activity and better aesthetic result. Moreover, the learning curve of such operations is rapid compared to laparoscopy, while at the same time the good clinical outcomes are equally effective as conventional laparoscopy and within similar operating times.

On the other hand, the most significant disadvantages include the high costs of use, the bulky machinery and the need for staff training. Regarding the cost, it was shown that open myomectomy costs \$4,937 compared to laparoscopy which costs \$6,219 and robotic procedures \$7,299 (16). Of course, entry of new robotic systems in the market as well as use of the robot by different surgical teams and in a high volume of patients could decrease the cost disadvantage. Moreover, some authors argue that robotic are longer operations and the loss of tactile sensation makes difficult the sensation of an intramural fibroid (17).

We present a state of the art narrative review dealing with management of uterine fibroids, especially the surgical treatment using the da Vinci® robotic system. We briefly describe the fertility sparing procedure – myomectomy – and the definitive procedure – hysterectomy – pointing out the advantages of the robotic surgery (increased dexterity, maneuverability of the system, greater range of motion and better depth perception) and compare the robotic, laparoscopic and open surgery in terms of complication rate, operative time, hospital stay, blood loss, learning curve and cost.

The review mentioned both approaches conservative and definitive with bigger focus on conservative approach.

We include a comparison of the laparotomic versus laparoscopic versus robotic assisted surgery. Recent meta-analyses and prospective studies are favouring the later two for shorter hospital stay and less blood loss (18–20). We would also like to note that morcellation of the tissue of fibroid after myomectomy – especially use of power morcellation – could rise a controversy according to FDA advise (21, 22). For this reason, we suggest that any type of morcellation should be performed inside a laparoscopic bag to avoid tissue contamination (22).

Robotic system in conservative management is a very interesting modality, though it struggles in comparison with laparoscopic management because it brings hardly any advantage for its higher cost. There are still lot of countries where the myomectomy with robotic system is still not covered by insurance companies and the spending power of patients is still very low and this modality is therefore unavailable. But this is the controversy worth to mention. When the cost issue is going to get overcome that could be the time when robotic modality in conservative management of fibroids would become more common in the future.

CONCLUSION

In conclusion, robotic myomectomy or hysterectomy is an equally effective, feasible and safe alternative in well-trained hands compared to the traditional methods of open or laparoscopic surgery. The till now evidence shows that robotic myomectomy has comparable results to open and laparoscopic techniques. More randomized prospective studies are necessary to clarify the role of robotic management especially in the long term outcomes such as pregnancy, miscarriage, caesarean section and live birth rates.

CONFLICT OF INTEREST

No conflict of interest was declared by the authors.

FINANCIAL DISCLOSURE

The authors declared that this study has received no financial support.

REFERENCES

1. Falcone T, Parker WH. Surgical management of leiomyomas for fertility or uterine preservation. *Obstet Gynecol* 2013; 121: 856–68.
2. Kim M, Kim MK, Kim ML, et al. Robotic single-site myomectomy: A single-center experience of 101 consecutive cases. *Int J Med Robot* 2019 Sep 19: e1959.
3. Stewart EA, Lytle BL, Thomas L, et al. The Comparing Options for Management: Patient-centered REsults for Uterine Fibroids (COMPARE-UF) registry: rationale and design. *Am J Obstet Gynecol* 2018; 219: e1–95.
4. Iavazzo C, Gkegkes ID. Application of da Vinci® Robot in simple or radical hysterectomy: Tips and tricks. *J Turk Ger Gynecol Assoc* 2016; 17: 106–9.
5. Quaas AM, Einarsson JI, Srouji S, Gargiulo AR. Robotic myomectomy: a review of indications and techniques. *Rev Obstet Gynecol* 2010; 3: 185–91.

6. Mahajan N, Moretti ML, Lakhi NA. Spontaneous early first and second trimester uterine rupture following robotic-assisted myomectomy. *J Obstet Gynaecol* 2019; 39: 278–80.
7. Pathirana S, Kam P. Anaesthetic issues in robotic-assisted minimally invasive surgery. *Anaesth Intensive Care* 2018; 46: 25–35.
8. Iavazzo C, Gkegkes ID. Port site metastases after robot-assisted surgery: a systematic review. *Int J Med Robot* 2013; 9: 423–7.
9. Wang T, Tang H, Xie Z, Deng S. Robotic-assisted vs. laparoscopic and abdominal myomectomy for treatment of uterine fibroids: a meta-analysis. *Minim Invasive Ther Allied Technol* 2018; 27: 249–64.
10. Pluchino N, Litta P, Freschi L, et al. Comparison of the initial surgical experience with robotic and laparoscopic myomectomy. *Int J Med Robot* 2014; 10: 208–12.
11. Govern JM, Rosemeyer CJ, Barter JF, Steren AJ. Comparison of robotic, laparoscopic and abdominal myomectomy in a community hospital. *JLS* 2013; 17: 116–20.
12. Griffin L, Feinglass J, Garrett A, et al. Postoperative outcomes after robotic versus abdominal myomectomy. *JLS* 2013; 17: 407–13.
13. Pitter MC, Gargiulo AR, Bonaventura LM, Lehman JS, Srouji SS. Pregnancy outcomes following robot assisted myomectomy. *Hum Reprod* 2013; 28: 99–108.
14. Lonnerfors C, Persson J. Pregnancy following robot-assisted laparoscopic myomectomy in women with deep intramural myomas. *Acta Obstet Gynecol Scand* 2011; 90(9): 972–7.
15. George A, Eisenstein D, Wegienka G. Analysis of the impact of body mass index on the surgical outcomes after robot-assisted laparoscopic myomectomy. *J Minim Invasive Gynecol* 2009; 16: 730–3.
16. Behera MA, Likes CE, Judd JP, Barnett JC, Havrilesky LJ, Wu JM. Cost analysis of abdominal, laparoscopic and robotic assisted myomectomies. *J Minim Invasive Gynecol* 2012; 19: 52–7.
17. Alkatout I, Mettler L, Günther V, et al. Safety and economical innovations regarding surgical treatment of fibroids. *Minim Invasive Ther Allied Technol* 2016; 25: 301–13.
18. Iavazzo C, Mamais I, Gkegkes ID. Robotic assisted vs laparoscopic and/or open myomectomy: systematic review and meta-analysis of the clinical evidence. *Arch Gynecol Obstet* 2016; 294: 5–17.
19. Wang T, Tang H, Xie Z, Deng S. Robotic-assisted vs. laparoscopic and abdominal myomectomy for treatment of uterine fibroids: a meta-analysis. *Minim Invasive Ther Allied Technol* 2018; 27: 249–64.
20. Pundir J, Pundir V, Walavalkar R, Omanwa K, Lancaster G, Kayani S. Robotic-assisted laparoscopic vs abdominal and laparoscopic myomectomy: systematic review and meta-analysis. *J Minim Invasive Gynecol* 2013; 20: 335–45.
21. Wallis L. FDA warns against power morcellation for hysterectomy and fibroids. *Am J Nurs* 2014; 114: 16.
22. Glaser LM, Friedman J, Tsai S, Chaudhari A, Milad M. Laparoscopic myomectomy and morcellation: A review of techniques, outcomes, and practice guidelines. *Best Pract Res Clin Obstet Gynaecol* 2018; 46: 99–112.

Perception of Undergraduate Students at the Faculty of Medicine in Hradec Králové Regarding Their Endodontic Education and Suggested Improvements

Martin Kapitán*, Lenka Vavříčková, Jakub Suchánek

ABSTRACT

Aim: The aim of this study was to assess the perception of undergraduate dentistry students at Charles University, Faculty of Medicine in Hradec Králové, the Czech Republic regarding their endodontic education within the context of the Undergraduate Curriculum Guidelines for Endodontology by the European Society of Endodontology (ESE). The secondary aim was to compare this perception among students in the Czech and English groups.

Methodology: A questionnaire survey was conducted among fifth year students at the very end of their studies.

Results: The students returned 60 filled questionnaires, making the response rate of 75.9%. More than two thirds of the respondents declared that they were competent at or had knowledge of most of the major competencies defined by the ESE. Eighty seven percent of respondents felt competent to perform a root canal treatment on anterior teeth; 86.7% on premolars; and 48.3% on molars. Nearly all respondents (98.3%) recommended more opportunities to practice on patients.

Conclusions: The overall perception of the students was that their endodontic education was sufficient and largely conformed to the guidelines. Insufficient exposure to endodontic practice on patients was identified as a deficiency. There were no significant differences in perceptions between the two study groups.

KEYWORDS

dental education; dentistry students; endodontic curriculum; endodontic education; questionnaire survey

AUTHOR AFFILIATIONS

Department of Dentistry, Charles University, Faculty of Medicine in Hradec Králové, and University Hospital Hradec Králové, Czech Republic

* Corresponding author: Department of Dentistry, Sokolská 581, 500 05, Hradec Králové, Czech Republic; e-mail: kapitnm@lfhk.cuni.cz

Received: 22 January 2020

Accepted: 3 April 2020

Published online: 10 August 2020

Acta Medica (Hradec Králové) 2020; 63(2): 67–72

<https://doi.org/10.14712/18059694.2020.19>

© 2020 The Authors. This is an open-access article distributed under the terms of the Creative Commons Attribution License (<http://creativecommons.org/licenses/by/4.0>), which permits unrestricted use, distribution, and reproduction in any medium, provided the original author and source are credited.

INTRODUCTION

Root canal treatment (RCT) is the treatment of teeth with irreversibly damaged or necrotic dental pulps with the goal of preserving the non-vital but functional tooth in the mouth (1). As there is no official state-guaranteed specialization in endodontics in the Czech Republic, RCT falls into the basic spectrum of treatment modalities provided by general dental practitioners. Thus, during undergraduate dentistry studies, students need to be familiarized with endodontology and achieve sufficient skills to be able to perform RCT independently.

The European Society of Endodontology (ESE) published recommendations about undergraduate endodontic curriculum in 2013 (2). There are 3 domains of endodontic competencies defined: scientific foundations of endodontic practice, nonsurgical endodontic treatment and surgical endodontic treatment. Each domain has several corresponding major competencies with specified required level of skills. The different levels of skills are defined and approved by the Association of Dental Education in Europe (3) (Table 1).

Within the curriculum of the dentistry programme at Charles University, Faculty of Medicine in Hradec Králové, endodontic education is divided into three subjects (Table 2). Apart from these dedicated endodontic subjects, students learn other topics related to endodontics in other subjects, such as tooth morphology including the root system in the Preclinical Dentistry I in the winter term of the first year and X-ray imaging in Dental Radiology in the winter term of the third year.

There are two parallel study groups – one in the Czech language and the other one in English. Both groups have the same curriculum, the same lectures, the same teachers and the same assessments. The only difference between the 2 groups is the language used. For practical lessons the students of these two groups are mixed, meaning each working pair consists of one student from each group.

In the literature there are only few studies dealing with the evaluation of endodontic education by students. There are no published studies on this topic from the Czech Republic or the Central European region.

Tab. 1 Definitions of the levels of applied to competences (3).

To be competent at	A dentist should on graduation demonstrate a sound theoretical knowledge and understanding of the subject together with an adequate clinical experience to be able to resolve clinical problems encountered independently or without assistance.
To have knowledge of	A dentist should on graduation demonstrate a sound theoretical knowledge and understanding of the subject but may have only limited clinical/practical experience.
To be familiar with	A dentist should on graduation demonstrate a basic understanding of the subject but need not have clinical experience or be expected to carry out procedures independently.

The primary aims of this study were (i) to assess the perception of the undergraduate students at Charles University, Faculty of Medicine in Hradec Králové, the Czech Republic regarding the endodontic curriculum within the context of the Undergraduate Curriculum Guidelines for Endodontology published by ESE in 2013; (ii) to evaluate endodontic education from the point of view of the students at the time of graduation in terms of other factors, i.e. quality and range of the lectures, extent of practical training, and suitability of the included topics; (iii) to document students' perceptions about their own endodontic experience, e.g. number of treated canals/teeth in patients and in vitro, the confidence in root canal treatment of different teeth; and (iv) to gather suggestions for improving endodontic education. The secondary aim was to compare these perceptions among the students in the Czech and English language groups.

Tab. 2 Description of dedicated endodontic subjects.

Subject		Endodontics I	Endodontics II	Endodontics III
Timing	Year	3rd	4th	5th
	Semester	summer	summer	winter
Teaching hours	Theory	25	6	15
	Preclin. practice	12	9*	0*
Description	Theory	Basic endodontic topics, e.g. diseases of dental pulp, vital pulp treatment, procedure of RCT including the instruments and materials used, complications, postendodontic treatment.	Machine shaping of the root canals, usage of ultrasound and operation microscope in endodontics.	Advanced endodontics procedures such as root canal retreatment, retrograde endodontic treatment, internal bleaching etc.
	Practice	Training of root canal treatment using hand instruments and lateral compaction.	Training of rotary shaping of the root canals. RCT in patients.	RCT in patients including postendo.
Requirements		Hand RCT of 2 canals in plastic blocks and 3 canals in extracted teeth	Rotary RCT of 2 canals in plastic blocks and 3 canals in extracted teeth.	RCT of 1 tooth in patient.

* Clinical practical lessons are incorporated in the practical lessons of the subject Clinical dentistry.

Tab. 3 A comparison of Czech and English groups and the years of graduation in terms of age and gender.

		Total	Gender		Age [years] - quantitative	Age [years] - qualitative			
			Men	Women	Median	23	24	25	26-38
			% (n)	% (n)	(Q1; Q3)	% (n)	% (n)	% (n)	% (n)
Language	Czech	71.7 (43)	30.2 (13) *	69.8 (30) *	24 (24; 25)	2.3 (1) **	51.2 (22) **	32.6 (14) **	14.0 (6) **
	English	28.3 (17)	64.7 (11) *	35.3 (6) *	24 (23; 24)	35.3 (6) **	41.2 (7) **	0.0 (0) **	23.5 (4) **
Year	2017	55.0 (33)	30.3 (10)	69.7 (23)	24 (24; 25)	6.1 (2)	45.5 (15)	33.3 (11)	15.2 (5)
	2018	45.0 (27)	51.9 (14)	48.1 (13)	24 (24; 25)	18.5 (5)	51.9 (14)	11.1 (3)	18.5 (5)

* p < 0.05; Pearson's Chi-Square test

** p < 0.001; Pearson's Chi-Square test or Fisher's exact test

MATERIAL AND METHODS

The study was approved by the Ethics committee of the University Hospital Hradec Králové (ref. no. 201708 S12P) and by the dean of Charles University, Faculty of Medicine in Hradec Králové.

A questionnaire survey was conducted. The authors created the questionnaire based on the ESE recommendations about the undergraduate endodontic curriculum (2) and on questionnaires used in other published studies on similar topics (4, 5). In the first part of the survey, respondents were asked about their gender and age. The second part included the major endodontic competencies according to the ESE recommendations. Each competency was asked two different ways: subjective self-evaluation of the student, if he or she is competent at or has knowledge of the specific area; and the student's assessment of the education, whether it was sufficient in this particular field. The third part contained of questions about the students' endodontic experience, their evaluation of the education and suggestions.

After piloting the survey with 10 students, no changes were made and the questionnaires were distributed to all students of the fifth year at the very end of their studies, studying in both Czech and English language, in two subsequent academic years (2016/2017 and 2017/2018). The inclusion criterion was graduation in one of the involved academic years. No exclusion criteria were applied. A total of 79 questionnaires were distributed. Participation in the study was voluntary, each participant signed an informed consent. Data from the questionnaires were analyzed anonymously in the NCSS 10 using methods of descriptive statistics, nonparametric Mann-Whitney test and Pearson's χ^2 test of independence in contingency tables or Fisher's exact test. The level of statistical significance was set to $\alpha = 0.05$.

RESULTS

A total of 60 students filled and returned the questionnaires, making the response rate 75.9%.

Figures 1 and 2 show the information about the age and gender distribution of the participating students. The me-

dian age was 24 years (Q1 = 24; Q3 = 25). The comparison of age and gender distribution between the study groups (Czech/English) and between the years of graduation (2017/2018) are presented in Table 3. For the statistical analysis of the differences between the groups the students in the age of 26 to 38 years were joined.

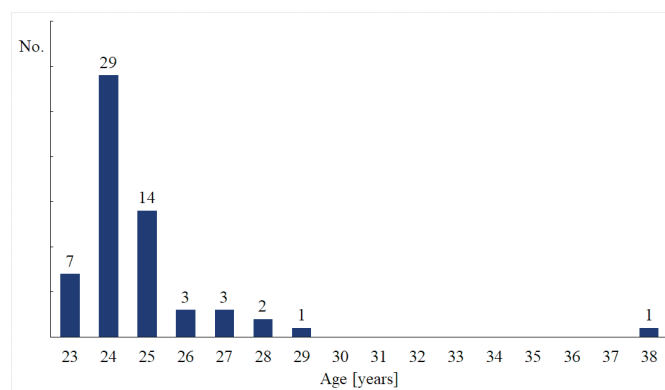


Fig. 1 Age distribution of the respondents.

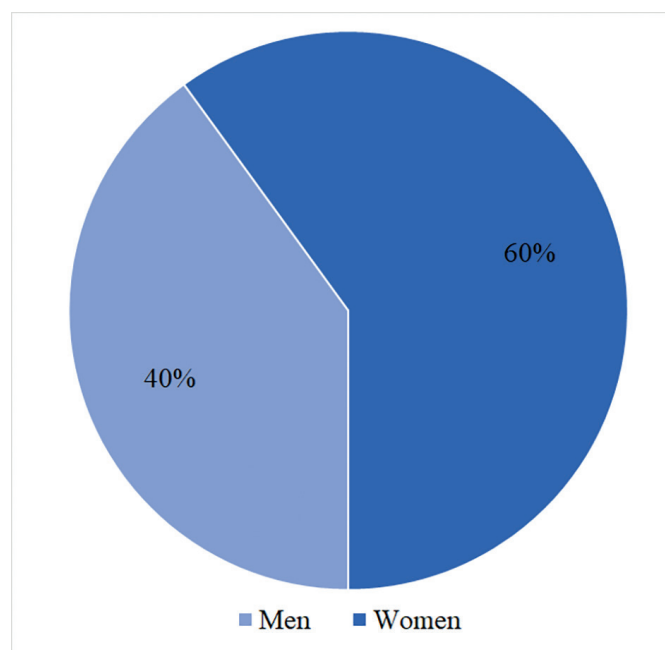


Fig. 2 Gender distribution of the respondents.

Tab. 4 Respondents' answers to the questions dealing with the major endodontic competencies.

	Yes % (n)	No % (n)		Yes % (n)	No % (n)
Domain 1: Scientific foundations of endodontic practice.					
I have knowledge of development, structure, function and ageing of oral and dental tissues.	100.0 (60)	0.0 (0)	I am competent at performing procedures to retain all or part of the dental pulp in health.	93.3 (56)	6.7 (4)
– Was the education in this field sufficient?	100.0 (60)	0.0 (0)	– Was the education in this field sufficient?	91.7 (55)	8.3 (5)
I have knowledge of anatomy of the head and neck region.	95.0 (57)	5.0 (3)	I am competent at performing good quality root canal treatment.	70.0 (42)	30.0 (18)
– Was the education in this field sufficient?	96.7 (58)	3.3 (2)	– Was the education in this field sufficient?	68.3 (41)	31.7 (19)
I have knowledge of dental anatomy.	100.0 (60)	0.0 (0)	I am competent at restoring root canal-treated teeth.	70.0 (42)	30.0 (18)
– Was the education in this field sufficient?	100.0 (60)	0.0 (0)	– Was the education in this field sufficient?	66.7 (40)	33.3 (20)
I have knowledge of pathology of oral and dental diseases.	100.0 (59)	0.0 (0)	I am competent at monitoring and evaluating the outcome of endodontic treatment.	93.3 (56)	6.7 (4)
– Was the education in this field sufficient?	93.2 (55)	6.8 (4)	– Was the education in this field sufficient?	91.7 (55)	8.3 (5)
I have knowledge of microbiology and immunology.	73.3 (44)	26.7 (16)	I am competent at communicating verbally and in writing with dental and medical colleagues.	83.3 (50)	16.7 (10)
– Was the education in this field sufficient?	71.7 (43)	28.3 (17)	– Was the education in this field sufficient?	56.7 (34)	43.3 (26)
I have knowledge of general medicine and surgery as applied to the management of dental (including endodontic) patients.	81.7 (49)	18.3 (11)	I have knowledge of the management of dentoalveolar trauma.	88.3 (53)	11.7 (7)
– Was the education in this field sufficient?	76.7 (46)	23.3 (14)	– Was the education in this field sufficient?	81.7 (49)	18.3 (11)
I have knowledge of pharmacology and therapeutics as applied to the management of dental (including endodontic) patients.	76.7 (46)	23.3 (14)	Domain 3: Surgical endodontic treatment.		
– Was the education in this field sufficient?	66.7 (40)	33.3 (20)	I am competent at conducting a detailed general and dental history for a patient with post-treatment endodontic disease.	100.0 (60)	0.0 (0)
I have knowledge of biomaterials science as applied to endodontics.	65.0 (39)	35.0 (21)	– Was the education in this field sufficient?	90.0 (54)	10.0 (6)
– Was the education in this field sufficient?	56.7 (34)	43.3 (26)	I am competent at conducting a comprehensive clinical examination of a patient with post-treatment endodontic disease.	95.0 (57)	5.0 (3)
I have knowledge of diagnostic imaging.	91.7 (55)	8.3 (5)	– Was the education in this field sufficient?	91.7 (55)	8.3 (5)
– Was the education in this field sufficient?	85.0 (51)	15.0 (9)	I am competent at reaching a diagnosis and possible differential diagnosis, and presenting treatment options for the management of post-treatment endodontic disease.	91.7 (55)	8.3 (5)
I have knowledge of epidemiology, public health measures and biostatistics.	43.3 (26)	56.7 (34)	– Was the education in this field sufficient?	88.3 (53)	11.7 (7)
– Was the education in this field sufficient?	46.7 (28)	53.3 (32)	I have knowledge of recognizing conditions that may best be managed by surgical endodontic treatment.	63.3 (38)	36.7 (22)
Domain 2: Nonsurgical endodontic treatment.			– Was the education in this field sufficient?	65.0 (39)	35.0 (21)
I am competent at conducting a detailed general and dental history.	100.0 (60)	0.0 (0)	I have knowledge of assessing the benefits, risks and likely outcome of endodontic surgery.	65.0 (39)	35.0 (21)
– Was the education in this field sufficient?	95.0 (57)	5.0 (3)	– Was the education in this field sufficient?	65.0 (39)	35.0 (21)
I am competent at conducting a comprehensive clinical examination of a patient with an endodontic-related problem.	98.3 (59)	1.7 (1)	I have knowledge of postoperative monitoring of surgical endodontic patients.	46.7 (28)	53.3 (32)
– Was the education in this field sufficient?	98.3 (59)	1.7 (1)	– Was the education in this field sufficient?	45.0 (27)	55.0 (33)
I am competent at reaching a diagnosis and possible differential diagnosis.	98.3 (59)	1.7 (1)			
– Was the education in this field sufficient?	98.3 (59)	1.7 (1)			
I am competent at establishing a treatment plan and communicating this to the patient.	86.7 (52)	13.3 (8)			
– Was the education in this field sufficient?	80.0 (48)	20.0 (12)			

The five highest numbers of answers "No" are in bold.

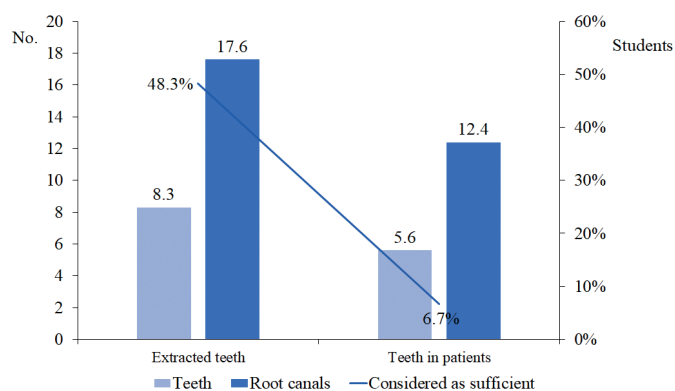


Fig. 3 Summary of endodontic experience of the respondents. Bars show the numbers of treated root canals/teeth on extracted teeth and in patients; axis on the left side. Line shows the percentage of the respondents considering these numbers as sufficient; axis on the right side.

Table 4 presents the answers of the respondents to the questions dealing with the major endodontic competencies according to the ESE recommendations.

Figure 3 shows the numbers of root canal treatments on extracted teeth/root canals and on real patients, along with the students' assessment of whether the experience was sufficient for independent practice. Four of the students declared they had not performed any root canal treatment on real patients. The teeth which were endodontically treated as the first RCT by the student on a patient were most often teeth 15 and 16 (maxillary right second premolar and maxillary right permanent first molar respectively; 7 cases each). Next in order were tooth 25 (maxillary left second premolar), tooth 36 (mandibular left permanent first molar) and tooth 46 (mandibular right permanent first molar); 4 cases each.

Forty-nine respondents (87.1%) felt that they were competent to perform RCT on anterior teeth, 52 (86.7%) on premolars, and 29 (48.3%) on molars.

The number of teaching hours, the range of education and the quality of education were considered sufficient by 81.7%, 86.7%, and 83.3% of respondents respectively.

As a proposed improvement, 98.3% of the respondents (n = 59) stated more practice on patients; 51.7% (n = 31) stated more practice on extracted teeth; 13.3% (n = 8) stated higher quality of lectures; and 8.3% (n = 5) stated more lectures.

Table 5 shows the frequently mentioned topics suggested for modification.

No statistically significant differences were found in the responses of students from the Czech and English study groups.

DISCUSSION

A questionnaire survey was chosen as a study design to reach the goals of the study. It is an inexpensive and fast method to gather required information. Although it has a limitation in the subjectivity of the answers, the questionnaire survey is often used in similar kinds of studies (4, 5).

Tab. 5 Most frequent respondents' suggestions.

Topics suggested to be added or addressed more	n
More practice on the patients	13
Postendodontic treatment	7
Endodontic radiology	6
Complications during and after treatment	6
Root canal retreatment	6
Improve preclinical training	5
More rotary endodontics	5
Topics suggested to be removed or shortened	n
Too much rotary endodontics	5

The study groups differed in terms of gender distribution and age. There were more women than men in the Czech group, which corresponds with the traditional gender distribution among dentists in the Czech Republic, where 61.9% are female dentists and 38.1% are male dentists (6). In the English study group, where there are students from many other countries, the gender distribution was opposite. The median age was the same in both groups; however, there were different distributions of students according to their age.

The second part of the questionnaire was based on the major competencies listed in the ESE recommendations on the undergraduate endodontic curriculum (2). The first parts of the questions presented a self-evaluation related to the students, whereas in the second parts the students evaluated the education itself. Overall, the evaluation in both parts of the questions was rather positive in the majority of the competencies. More than 80% of the respondents answered "yes" in the first parts of 17 questions and in the second parts of 15 questions out of 26. More than one half of the students declared they didn't have knowledge of "epidemiology, public health measures and biostatistics" and of "postoperative monitoring of surgical endodontic patients"; correspondingly, more than one half of the respondents considered the education in these two fields as insufficient. Between one third and one half of the students declared they didn't have knowledge of "biomaterials science as applied to endodontics", of "recognizing conditions that may best be managed by surgical endodontic treatment" and of "assessing the benefits, risks and likely outcome of endodontic surgery"; more than one third of the students also considered education insufficient in these three fields and additionally in "communicating verbally and in writing with dental and medical colleagues". These subjects need to be addressed.

The average number of root canal treatments performed on both extracted and real teeth in this study was higher than in the study from the Cardiff University (4), where the average number of root fillings among the fifth year students was 7.4 on extracted teeth and 2.81 on real teeth. One third of involved students completed zero or one root filling. The number of root fillings performed on extracted and real teeth had an influence on the perception of competence. Such a correlation was not seen in our

study, i.e. no number of root canals was found as a minimum to be considered sufficient, neither for extracted nor real teeth. An alarming finding was that four students had never done root canal treatment on a patient during their undergraduate studies. Thus, it is essential to implement performing a root canal treatment on a real patient as a strict credit condition. In the current syllabus the formulation of this requirement is vague. The mean number of root canals treated by the fifth-year students at the University of Otago, New Zealand, was 10.4 canals (5).

There are different demands on students during their undergraduate endodontic education at schools in the European Union (7, 8), in the USA and in Canada (9). Out of the dental schools in the United Kingdom 87% had minimum requirements for the number of RCTs during the preclinical training, and 67% for the clinical training (7). A total of 81% of European schools required a minimum number of RCTs performed by their students. This minimum varied between 3 and 80 canals with an average of 17 canals (8). Among the schools in the USA and Canada the students were required to do RCT of at least 3–9 teeth (average 4.9 teeth) or of 4–18 root canals (average 8.8 canals) (9). At Cardiff University students are expected to treat 6 extracted teeth, two of them being molars (4). Our respondents would roughly meet these requirements.

Around 80% of the third, fourth and fifth year students ranked education in endodontics at the Cardiff University as ≤ 5 on the Likert scale (1 = inadequate to 10 = good), stating a lack of clinical experience. Out of the fifth year's students 90.5% felt competent when performing uncomplicated non-surgical RCT on a single-rooted tooth, but only 42.9% on a multirouted tooth (4). Our results showed similar findings. Most of our students felt competent to perform RCT on anterior teeth and premolars, however, less than half of them felt competent to perform RCT on molars. The students mostly expressed a satisfaction with the amount, range and quality of endodontic lectures, but they recommended increasing experience with both extracted teeth and on the patients. Correspondingly, the most frequent suggestion in the open-ended questions was to provide more practice on real patients. In recent years the number of the patients demanding primary RCT has decreased. The reasons are improvements of dental health status in the general population and the introduction of more reliable treatments for preserving the vital dental pulp.

The student's suggestions in other fields summarized in Table 5 should be addressed. Targeted actions must be taken to make the students feel more confident in these particular areas. There was a controversy in the opinions of the respondents about the rotary shaping of root canals. Five students suggested extending the rotary preparation training, whereas five opined there was too much time spent on it. They stated that it was not worth learning about a particular system because later in practice each will use something different. The authors consider rotary shaping of root canals as a routine method of preparation and that it should be implemented in the undergraduate endodontic education both theoretically and practically.

The limitation of this study was quite small number of the participating students (around 40 graduates every year). To increase the number of respondents the study

was performed in two subsequent academic years in two study groups with different language of the lessons. No exclusion criteria were applied for the same reason.

CONCLUSIONS

The students mostly considered that endodontic education was sufficient at the Charles University, Faculty of Medicine in Hradec Králové and that it largely conformed to the recommendations published by the ESE.

Several topics need to be emphasized and taught in more depth, notably surgical endodontic treatment.

The dominant problem of the endodontic education found by this study was lack of practice on patients. To be considered sufficient it must be extended.

The perception of the endodontic education in the different language groups was similar.

The results of this study will be used as a valuable feedback to enhance endodontic education. The respondents recommended several improvements.

ACKNOWLEDGEMENTS

The authors would like to thank all the participants for filling out the questionnaires; Dr. Eva Čermáková from Computer Technology Center, Charles University in Prague, Faculty of Medicine in Hradec Králové, Czech Republic, for help with the statistical analysis; prof. Zelalem Temesgen, M.D. from Mayo Clinic, Rochester, Mi, USA, and MDDr. Eliska Charlotte Wurfel for a language revision of the manuscript.

The study was financially supported by the Charles University's programme PROGRES Q40/13.

The authors declare no conflict of interest.

REFERENCES

1. European Society of Endodontology. Quality guidelines for endodontic treatment: consensus report of the European Society of Endodontology. *International Endodontic Journal* 2006; 39: 921–30.
2. De Moor R, Hülsmann M, Kirkevang LL, Tanalp J, Whitworth J. Undergraduate curriculum guidelines for endodontology. *International Endodontic Journal* 2013; 46: 1105–14.
3. Cowpe J, Plasschaert A, Harzer W, Vinkka-Puhakka H, Walmsley AD. Profile and competences for the graduating European dentist – update 2009. *European Journal of Dental Education* 2010; 14: 193–202.
4. Davey J, Bryant ST, Dummer PMH. The confidence of undergraduate dental students when performing root canal treatment and their perception of the quality of endodontic education. *European Journal of Dental Education* 2015; 19: 229–34.
5. Murray CM, Chandler NP. Undergraduate endodontic teaching in New Zealand: Students' experience, perceptions and self-confidence levels. *Australian Endodontic Journal* 2014; 40: 116–22.
6. Czech dental chamber (2018) Yearbook 2017 [WWW document]. https://img.dent.cz/a/e/e/a69/a69/1516415/Rocenka_2017.pdf [accessed on 16 January 2019].
7. Al Raisi H, Dummer PMH, Vianna ME. How is Endodontics taught? A survey to evaluate undergraduate endodontic teaching in dental schools within the United Kingdom. *International Endodontic Journal* 2019; 52: 1077–85.
8. Gatley S, Hayes J, Davies C. Requirements, in terms of root canal treatment, of undergraduates in the European Union: an audit of teaching practice. *British Dental Journal* 2009; 207: 165–70.
9. Woodmansey K, Beck LG, Rodriguez TE. The Landscape of Predoctoral Endodontic Education in the United States and Canada: Results of a Survey. *Journal of Dental Education* 2015; 79: 922–27.

Fluoroscopic Epidural Steroid Injection: Pain Relief in Discogenic Sciatica Versus Lumbar Spinal Stenosis. A Study on Middle Eastern Patients

Todor Shamov^{1,2}, Jasem Y. Al-Hashel³, Rossen T. Rousseff^{3,*}

ABSTRACT

Objective: To compare the effect of epidural steroid injections (ESI) in patients with discogenic sciatica (Sci) versus patients with lumbar canal stenosis (LSS), not controlled by conservative treatment.

Materials and methods: In our study, 80 patients with Sci and 66 with LSS were included. A single ESI (10 mg dexamethasone in 3 cc 0.25% bupivacaine) was applied under fluoroscopic control: one level above the highest stenotic level, in the posterior epidural space, via interlaminar approach in LSS and at the prolapse level, in the anterior epidural space, via transforaminal route in Sci. Pain intensity was assessed by VAS at baseline and on days 1, 15 and 30 after intervention.

Results: The procedure was successful in 78 Sci and 63 LSS patients. Patients with Sci responded significantly better. At one month, pain reduction over 50% was achieved in 63% (52.3–73.7% at $p = 0.95$) of Sci but only in 35% (23.2–46.8%) of LSS ($p = 0.03$). Return to pre-intervention level happened in 47% (34.7–59.3%) of LSS versus 14% (6.3–21.7%) of Sci patients ($p = 0.01$). In 5 patients the procedure failed, without resulting morbidity.

Conclusion: ESI are more effective in patients with Sci than in single level LSS. In multiple level LSS, results are disappointing

KEYWORDS

epidural steroid injections; intervertebral disc disease; lumbar spinal stenosis; low back pain; sciatica; chronic pain; neuropathic pain.

AUTHOR AFFILIATIONS

¹ Armed Forces Hospital "Jaber Al-Ahmad Al-Sabah", Subhan, 46012, Kuwait

² Department of Neurosurgery, Military Medical Academy, St Georgi Sofijski Str 3, 1606, Sofia, Bulgaria

³ Department of Neurology, Ibn-Sina Hospital, Sabah Health Area, Safat 13115, Kuwait

* Corresponding author: Department of Neurology, Ibn Sin Hospital, post box 25427, Sabah Health Area, Safat 13115, Kuwait; e-mail: emg.doctor@hotmail.com

Received: 27 February 2020

Accepted: 2 June 2020

Published online: 10 August 2020

Acta Medica (Hradec Králové) 2020; 63(2): 73–78

<https://doi.org/10.14712/18059694.2020.20>

© 2020 The Authors. This is an open-access article distributed under the terms of the Creative Commons Attribution License (<http://creativecommons.org/licenses/by/4.0>), which permits unrestricted use, distribution, and reproduction in any medium, provided the original author and source are credited.

INTRODUCTION

Vertebrogenic low back pain (LBP) and lower extremity pain is very common and a high socioeconomic burden (1). About 15% of patients develop chronic LBP that persists throughout life (2). Surgically treated patients develop chronic LBP and/or neuropathic pain (“failed back surgery syndrome”) in at least 10% of cases with discogenic sciatica and in up to 40% of LSS cases (3).

Early control of vertebrogenic pain may prevent the development of chronic pain and the associated negative outcomes (analgesic abuse/dependence, loss of employment, psychosocial problems etc.) (2, 4). It enables early physiotherapy/rehabilitation that improves non-surgical treatment results (5). However, pain control is not always possible with non-invasive means only (6).

Epidural steroid injection (ESI) is a minimally invasive procedure that introduces the medication (often combined with local anesthetic) close to the pathology site, presumably enhancing its local action while minimizing the systemic effects (7). Numerous studies recommend ESI in low back and radicular pain, but others dispute their utility (8–10).

We compare the short-term efficacy of epidural steroid and anesthetic injection for pain relief in Sci and LSS patients, not controlled by conservative therapy alone. We involved Middle Eastern patients only as there are observations of reduced pain tolerance in this population compared with other groups (11, 12).

MATERIALS AND METHODS

STUDY POPULATION

This prospective case-control study involves 80 patients with discogenic sciatica (Sci) and 66 patients with lumbar spinal stenosis (LSS), recruited at a tertiary Spinal Clinic. The study was approved by the institutional ethics committee and required informed consent from the partic-

ipants, in accordance with the Helsinki Declaration. The diagnosis was established by clinical examination and MRI obtained within the 3 months before intervention. Included were patients with low back pain and radicular pain who did not achieve satisfactory pain control and functional improvement after 6 weeks of medical treatment and physiotherapy, as this length of time is considered a transition point from acute to subacute pain stages (13).

Excluded were: 1. Cases of disc prolapse with extruded disc sequester within the spinal canal (who were offered surgical treatment). 2. Patients who had already undergone operative treatment or epidural injection. 3. Patients with motor deficit (they were offered surgical treatment). 4. Patients with absolute contraindications for corticosteroid treatment (peptic ulcer, uncontrolled hypertension, uncontrolled diabetes, etc.), hypersensitivity to local anesthetics or contrast.

The demographic and clinical features of the two groups are summarized in Table 1.

The clinical assessment and the invasive procedures in this study were personally performed by the authors.

PAIN INTENSITY ASSESSMENT

Pain was quantified using the visual analogue scale (VAS) (14) at baseline (the day of the procedure) and one, 15 and 30 days thereafter. Non-steroid analgesics were withheld 3 days before ESI and during the observation period.

EPIDURAL INJECTION

The procedure was performed in the operating theatre. The patient was positioned prone on a radiolucent table, with intravenous catheter inserted and monitoring of the ECG and the blood pressure. The level of the injection and the approach was determined according to nosology (see below). We first infiltrated the subcutaneous tissues at the injection site with 1 ml 1% lidocaine solution. The epidural space was reached using an 80 mm, 18G spinal cannula (Spinocan, Braun™). Epidurography was first performed by injecting 1 ml iohexol 300 mg/ml into the epidural space. After fluorographic verification of the needle position, 3 ml 0.25% bupivacaine and 10 mg dexamethasone was applied.

Injection in the posterior epidural space via the interlaminar approach was done 1) one level above the highest level of stenosis in all LSS patients and 2) at the level of the disc lesion in 10 Sci patients, who had root symptoms in 2 contralateral dermatomes. We applied the following technique. The level of injection is determined under X-ray guidance. The point of skin penetration is 1–1.5 cm away from the midline, with the needle directed about 30 degrees towards the midline in the axial plane and 15 degrees rostral in the sagittal plane. The tip of the needle is directed towards the interlaminar space under X-ray control. When reaching the ligamentum flavum we used the “loss of resistance” technique, instilling about 5 cc of air. After entering the epidural space, we always performed aspiration to ensure the needle is not situated intrathecally or within a vessel. Then epidurography was carried out (Fig. 1). Finally, the anesthetic/steroid preparation was applied.

Tab. 1 Demographic and clinical patient characteristics.

Patient characteristics	Lumbar spinal stenosis (n = 66)	Discogenic sciatica (n = 80)
Age (median)	58 (38–76)	52 (29–73)
Sex*	Male 45, female 18	Male 48, female 30
Median duration of the present complaints (days)*	65 (42–90)	48 (42–60)
Level of involvement	Single – 25 (18 L4/5, 7 L5/S1) Two levels – 19 Three levels – 19	Monoradicular L5 – 22 Monoradicular S1 – 25 Biradicular ipsilateral (L5 and S1) – 18 Biradicular contralateral – 10 Polyradicular – 5
Sensory deficit	23	33

Notes: significant differences are marked with asterisk (chi-square test for categorical values, Mann-Whitney test for parametric values with non-standard distribution).

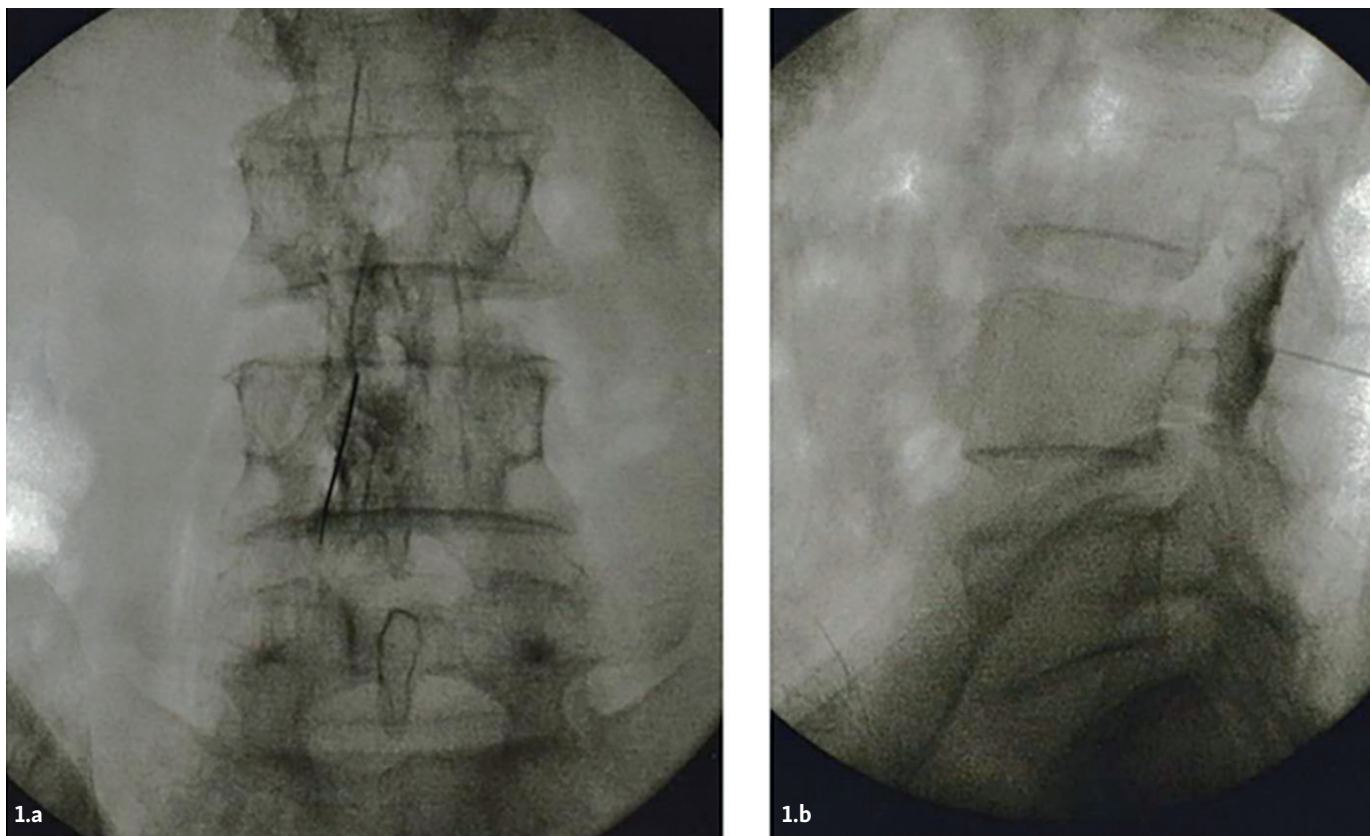


Fig. 1 Epidurography in a patient with LSS at L4–L5 level. 1a) Frontal view, 1b) lateral view. The contrast has spread within the posterior epidural space over at least 2 levels on both sides. A “stop” of the contrast at L4–L5 level is evident.

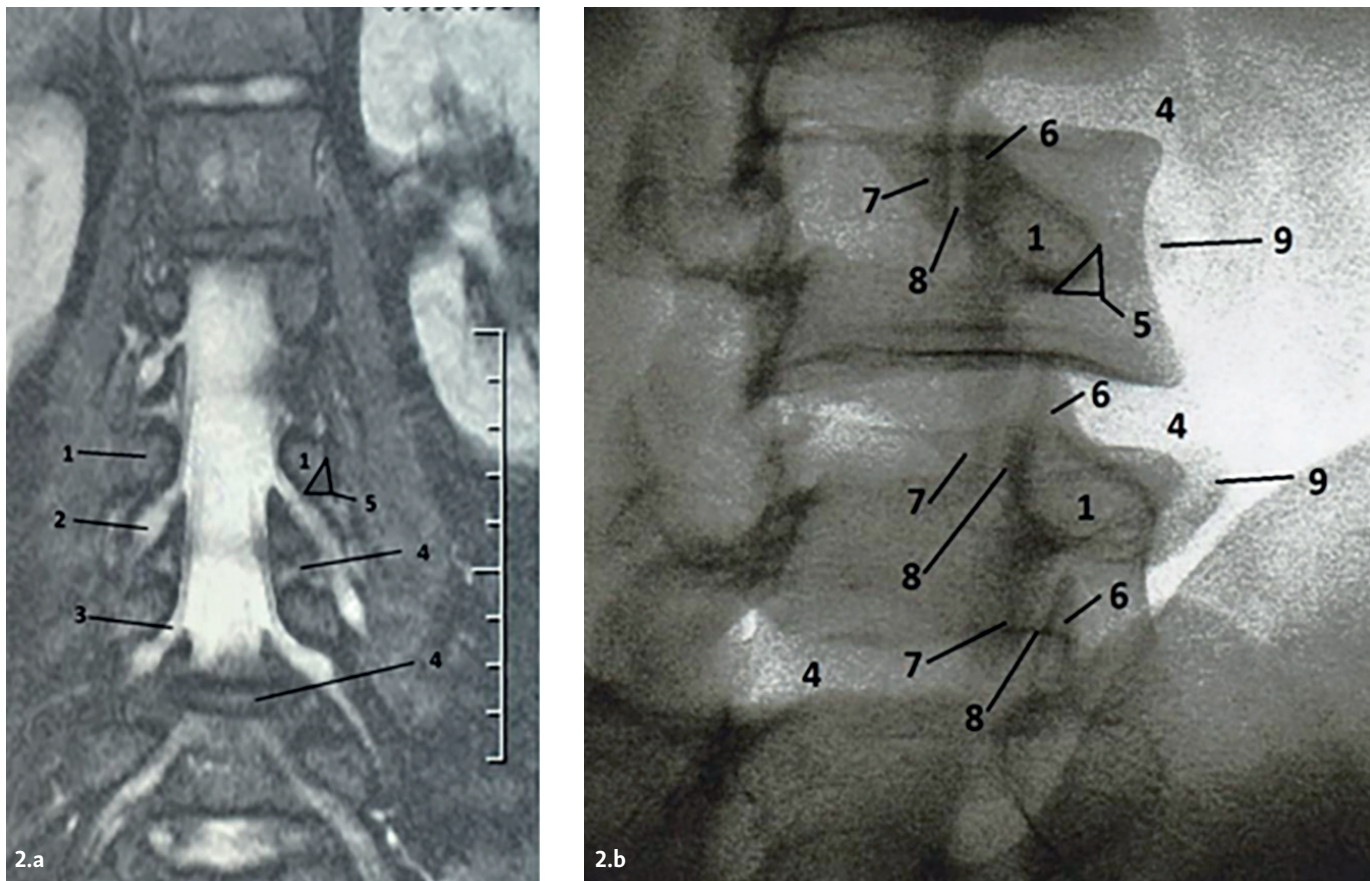


Fig. 2 Anatomic and radiologic detail. 2a – MRI myelography showing the interpositions between the nerve roots and ganglia versus the bone structures and intervertebral discs. 2b – Right oblique “Scotty dog” projection used for transforaminal approach to the anterior epidural space. Numbers indicate: 1 – pedicle of vertebral arch; 2 – dorsal ganglion; 3 – preganglionic nerve root; 4 – intervertebral disc; 5 – safety triangle; 6 – superior articular facet; 7 – inferior articular facet; 8 – facet joint cavity; 9 – transverse process.

The 70 patients with unilateral Sci received anterior epidural injection via the transforaminal approach. In single disc pathology, it was done at the same level, on the side of the affected root. In multiple disc levels and clinical involvement of 2 or more roots, we approached the rostral disc level on the side of maximal clinical radiculopathy. For visualization with this approach we used oblique left or right projections. The C-arm was inclined to 30 degrees in the axial plane until obtaining the “Scotty Dog” image of the pedicle and adjacent bony structures. To avoid conflict with nerve structures, the needle tip should be directed below the pedicle, into the “safety triangle” defined by the tangential lines of the vertical and horizontal contours of the pedicle, as illustrated in Figure 2.

After reaching the safety triangle, the C-arm is positioned for frontal and lateral projections to verify the proper position of the needle tip. Then epidurography is performed and finally the anesthetic/steroid solution is injected.

All patients were observed for 2 hours after the injection.

The procedure was cancelled in cases of intrathecal or intravascular penetration; these patients were treated conservatively and excluded from further participation.

Statistical methods included descriptive, alternative, variance and non-parametric analysis. Statistical level of significance was accepted at $p < 0.05$.

RESULTS

In 5 patients (3.5%, 0.2-5.8%) the procedure was unsuccessful. Three had intrathecal penetration of contrast (2 after interlaminar and one after transforaminal approach). In the other two, aspiration yielded blood, indicating a vessel penetration. There was no associated morbidity.

In the remaining 141 patients, the procedure was uneventful. Their total hospital stay (including 2 hours' observation) was 6 hours (3.5-6.8). All completed the scheduled follow-up.

The patients with LSS had significant pain relief. Their reported pain intensity was 6 +/- 1.8 VAS score immediately before the intervention, 3.2 +/- 0.4 on the day after the injection, 4.3 +/- 0.6 two weeks and 5 +/- 0.4 at one month respectively. The best results were achieved in the 25 patients with single level stenosis, with 3.8 +/- 0.9 VAS score one month after the procedure.

Sci patients improved significantly better. They had initial pain intensity of 7.1 +/- 1.3 VAS points, then 3.0 +/- 0.2 (day one), 3.6 +/- 0.4 (two weeks) and 4.7 +/- 0.3 (one month). The 47 patients with single root involvement had a significantly better outcome at one month (3.9 +/- 0.7).

One-way ANOVA confirmed the significant difference between groups at all comparison points, as illustrated in Figure 4.

The early effects, lasting days to weeks were quite significant in both groups. To better compare the effects of the procedure between LSS and Sci patients at one month we stratified the response at that point of time as good (VAS score decrease with more than 50%), satisfactory

(VAS improvement less than 50%) and poor (return to preoperative values). Results are summarized in Table 2.

The higher effectiveness of the intervention in Sci patients is evident.

DISCUSSION

ESI produced major short-term improvements, significantly greater in Sci than in LSS patients. After one month, nearly half of the LSS but only about 10% of Sci patients returned to their pre-intervention condition. The procedure was particularly effective in LSS patients with a single level of stenosis and Sci patients with monoradicular involvement. The percent of failed interventions was very low.

ESI are the most popular interventional technique in low back and lower extremity pain (at least in the United States) and their use continues to increase (15). While their long-term efficacy and cost-effectiveness remain controversial, most experts agree on the short-term pain relief provided, particularly in sciatica (8-10, 15). We assessed systematically the efficacy of epidural steroid injections in a Middle Eastern population as significant differences in pain tolerance between Middle Easterners and other cultures have been demonstrated (11, 12).

Our study has weaknesses like is the lack of a placebo group (not allowed by the IRB for ethical considerations) that places it into the third class in terms of quality of evidence (16). Another disadvantage is focusing on pain and relying on VAS only. We intended to study functional outcomes using a standard tool (the Oswestry Disability Index) in its Arabic validated translation (17) but it was not well accepted by patients (questions regarding sexual life, hygiene were considered intrusive). As our referrals in a Military Hospital were predominantly male, the sexes proportions in our study cohort are not representative of the incidence of LSS and Sci in the general population.

Despite these shortcomings, we present some significant results.

The efficacy of ESI at one month in our patients was lower than the reported in some studies but similar to or higher than other patient series, originating from very diverse countries and settings and methodologically comparable with our study (9-11, 18-21). While a direct comparison across different studies is methodologically not appropriate, we should note that our results tend toward a “median value” and suggest that the differences are not due to lower tolerance to pain in our population but rather to patient selection, to dose of medication used, different study design (blinded, open) and/or other confounding factors.

The significantly higher utility of ESI in Sci compared to LSS in our study confirms some previous reports (11, 22, 23). It may reflect the different pain mechanisms prevailing in either pathology. In LSS, pain is mostly nociceptive or mixed (nociceptive and neuropathic) (24), determined by mechanical factors. The neuropathic pain component in LSS is considered a consequence of ischemia causing repolarization disturbance of neuronal membranes that

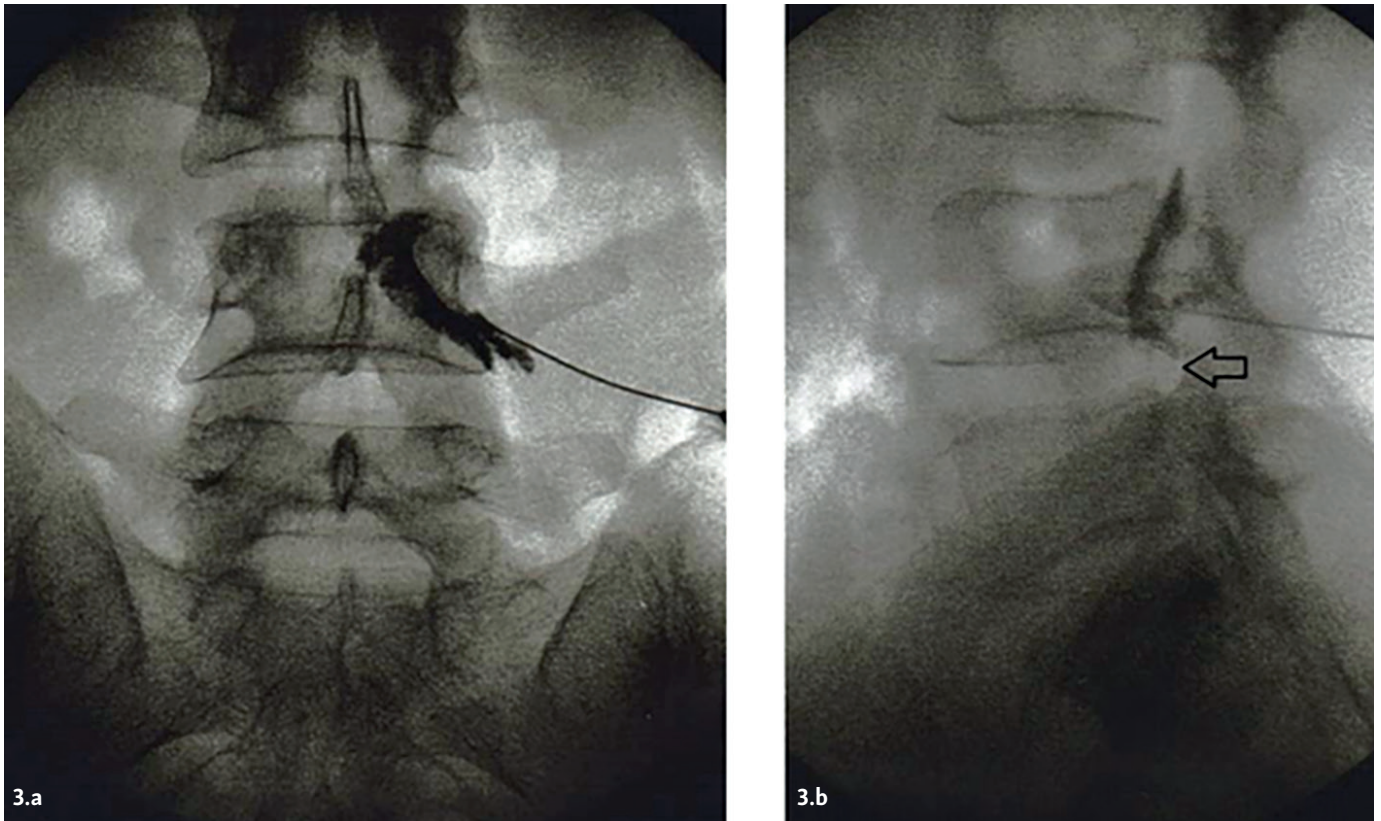


Fig. 3 Epidurography in disc prolapse at L4–L5 level in the frontal (3a) and lateral (3b) projection that visualizes the tip of the needle and the spread of contrast in the anterior epidural space. A “stop” of the contrast by the prolapse (arrow).

manifests clinically as hyperesthesia and neurogenic claudication (24). The membrane-stabilizing effect of steroids with hyperpolarization and inhibition of C-fibers conduction may explain the extended analgesic effect in LSS (25). However, the mechanical and vascular factors involved in LSS would not be corrected by the steroid application.

In contrast, in discogenic radiculopathy the pain is mostly neuropathic and inflammation likely plays a central role (26). Penetration of nucleus pulposus into the superficial layers of annulus fibrosus triggers an immune response, in particular - tumor necrosis factor alpha (TNF- α) from activated macrophages (27). Inflammation leads to disturbances in microcirculation with alteration of the myelin sheets in the nerve root that produce the clinical manifestations of radiculopathy

(26, 27). Neuropathic pain may be also related to prostaglandin cascade activation with release of substance P and other mediators in the affected dorsal ganglion (28).

If inflammation has a much greater significance in the pathogenesis of discogenic sciatica, the anti-inflammatory action of steroids would explain their higher efficacy in Sci versus LSS. This is supported indirectly by the effects of epidural application of TNF- α antagonists - etanercept, adalimumab - that alleviate sciatica (29, 30). The efficacy of epidural clonidine in neuropathic radicular pain may also partially depend on its anti-cytokine actions (31).

The superior effect of epidural steroid/anesthetic in single-level LSS and in monoradicular Sci is intuitively expected. This finding may be helpful in patient selection.

Complications of ESI, from mild to even fatal have been reported (32), but we didn't observe procedure related

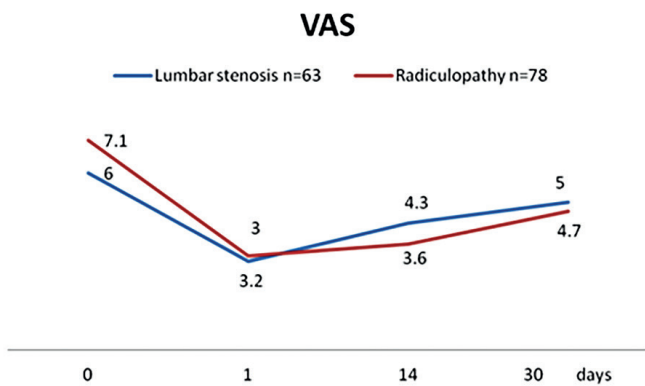


Fig. 4 Mean pain intensity (worst pain irrespective of location) in both groups. P < 0.03 on day one and P < 0.01 at all other comparison points (two-way ANOVA).

Tab. 2 Epidural anesthetic/steroid injection - results at one month.

	VAS Improvement of over 50%	VAS improvement of less than 50%	Return to preoperative levels
Patients with LSS, n = 63	22 (35%, 23.2–46.8)	11 (18%, 8.5–27.5)	30 (47%, 34.7–59.3)
Patients with Sci, n = 78	49 (63%, 52.3–73.7)	18 (23%, 13.7–32.3)	11 (14%, 6.3–21.7)

Notes: Significant difference in outcomes between LSS and Sci patients is confirmed (Fisher's exact probability test, multiple comparison; P = 0.0062).

morbidity neither in the 141 patients with successful injection nor in the minimal percent of cases where we had technical failure.

In conclusion, ESI with fluoroscopic guidance is safe, effective in short term pain relief and may be routinely recommended for patients with Sci and single level LSS, if conservative measures are not sufficient. In multiple level LSS, well-motivated patients should be selected for ESI.

DISCLOSURE

The authors declare no conflicts of interest related with this article.

REFERENCES

- Hoy D, March L, Brooks P, et al. The global burden of low back pain: estimates from the Global Burden of Disease 2010 study. *Ann Rheum Dis* 2014; 6: 968-74.
- Mehling WE, Gopisetty V, Bartmess E, et al. The prognosis of acute low back pain in primary care in the US: a 2-year prospective cohort study. *Spine* 2012; 37: 678-84.
- Chan CW, Peng P. Failed back surgery syndrome. *Pain Med* 2011; 12: 577-606.
- Chou R, McCarberg B. Managing acute back pain patients to avoid the transition to chronic pain. *Pain Manag* 2011; 1: 69-79.
- Arnold E, La Barrie J, DaSilva L, et al. The impact of timing of physical therapy for acute low back pain on health services utilization: a systematic review. *Arch Phys Med Rehabil* 2019; 100: 1324-38.
- Chou R, Deyo R, Friedly J, et al. Noninvasive treatments for low back pain [Internet]. Rockville (MD): Agency for Healthcare Research and Quality (US); 2016 Feb. Available from: <https://www.ncbi.nlm.nih.gov/books/NBK350276/> accessed 05.03.2019.
- McLain RF, Kapural L, Mekhail NA. Epidural steroid therapy for back and leg pain: mechanisms of action and efficacy. *Spine J* 2005; 5: 191-201.
- Rivera CE. Lumbar epidural steroid injections. *Phys Med Rehabil Clin N Am* 2018; 29: 73-92.
- Pinto RZ, Maher CG, Ferreira ML, et al. Epidural corticosteroid injections in the management of sciatica: a systematic review and meta-analysis. *Ann Intern Med* 2012; 157: 865-77.
- Liu K, Liu P, Liu R, Wu X, Cai M. Steroid for epidural injection in spinal stenosis: a systematic review and meta-analysis. *Drug Des Devel Ther* 2015; 9: 707-16.
- Dawson A, List T. Comparison of pain thresholds and pain tolerance levels between Middle Easterners and Swedes and between genders. *J Oral Rehabil* 2009; 36: 271-8.
- Rahavard B, Candido K, Knezevic N. Different pain responses to chronic and acute pain in various ethnic/racial groups. *Pain Manag* 2017; 7: 427-53.
- Thienhaus O, Cole B. Classification of pain. in Weiner R. *Pain management: A practical guide for clinicians*, 6th ed. CRC Press, 2002, pp. 28-30.
- Huskinson E. Measurement of pain. *Lancet* 1974; 2: 1127-31.
- Manchikanti L, Pampati V, Falco FJ, Hirsh JA. Assessment of the growth of epidural injections in the medicare population from 2000 to 2011. *Pain Physician* 2013; 16: 349-4.
- Sackett D, Rosenberg W, Gray J, et al. Evidence based medicine: what it is and what it isn't. *BMJ* 1996; 312(7023): 71-2.
- Guermazi M, Mezghani M, Ghroubi S, et al. [The Oswestry index for low back pain translated into Arabic and validated in a Arab population]. *Annales de readaptation et de medecine physique* 2005; 48: 1-10.
- Ackerman WE, 3rd, Ahmad M. The efficacy of lumbar epidural steroid injections in patients with lumbar disc herniations. *Anesth Analg* 2007; 104: 1217-22.
- Park CH, Lee SH. Correlation between severity of lumbar spinal stenosis and lumbar epidural steroid injection. *Pain Med* 2014; 15: 556-61.
- Kamble PC, Sharma A, Singh V, Natraj B, Devani D, Khapane V. Outcome of single level disc prolapse treated with transforaminal steroid versus epidural steroid versus caudal steroids. *Eur Spine J* 2016; 25: 217-21.
- Kawu AA. Epidural steroid injection in patients with lumbosacral radiculopathy in Abuja, Nigeria. *J Neurosci Rural Pract* 2012; 3: 121-5.
- Rivest C, Katz JN, Ferrante FM, Jamison R. Effects of epidural steroid injection on pain due to lumbar spinal stenosis or herniated disks: a prospective study. *Arthritis Care Res* 1998; 11: 291-7.
- Mobaleghi J, Allahdini F, Nasseri K, et al. Comparing the effects of epidural methylprednisolone acetate injected in patients with pain due to lumbar spinal stenosis or herniated disks: a prospective study. *Int J Gen Med* 2011; 4: 875-8.
- Bagley C, MacAllister M, Dosselman L, Moreno J, Aoun S, El Ahmadi T. Current concepts and recent advances in understanding and managing lumbar spine stenosis. *F1000Res*. 2019 Jan 31; 8. doi: 10.12688/f1000research.16082.1. Accessed on 05.03.2019.
- Johansson A, Hao J, Sjolund B. Local corticosteroid application blocks transmission in normal nociceptive C-fibers. *Acta Anaesthesiol Scand* 1990; 34: 335-8.
- Mulleman D, Mammou S, Griffoul I, et al. Pathophysiology of disk-related sciatica. I. - Evidence supporting a chemical component. *Joint Bone Spine* 2006; 73: 151-8.
- Di Martino A, Merlini L, Faldini C. Autoimmunity in intervertebral disc herniation: from bench to bedside. *Expert Opin Ther Targets* 2013; 17: 1461-70.
- Kobayashi S, Kokubo Y, Uchida K, et al. Effect of lumbar nerve root compression on primary sensory neurons and their central branches: changes in the nociceptive neuropeptides substance P and somatostatin. *Spine* 2005; 30: 276-82.
- Cohen SP, Bogduk N, Dragovich A, et al. Randomized, double-blind, placebo-controlled, dose-response, and preclinical safety study of transforaminal epidural etanercept for the treatment of sciatica. *Anesthesiology* 2009; 110: 1116-26.
- Genevay S, Finckh A, Zufferey P, et al. Adalimumab in acute sciatica reduces the long-term need for surgery: a 3-year follow-up of a randomised double-blind placebo-controlled trial. *Ann Rheum Dis* 2012; 71: 560-2.
- Romero-Sandoval A, Eisenach JC. Perineural clonidine reduces mechanical hypersensitivity and cytokine production in established nerve injury. *Anesthesiology* 2006; 104: 351-5.
- Epstein NE. The risks of epidural and transforaminal steroid injections in the spine: Commentary and a comprehensive review of the literature. *Surg Neurol Int* 2013; 4(Suppl 2): S74-S93.

Duodenal Pressure Necrosis in a Child Caused by a Migrated Percutaneous Endoscopic Gastrostomy

Jan Melek^{1,*}, Markéta Štanclová¹, Radek Štichhauer², Pavel Rozsival¹, Jan Kopřiva³, Jana Dědková³, Eva Terifajova¹, Eva Šedivá¹, Petr Dědek¹, Sylva Skálová¹, Jan Bureš⁴

ABSTRACT

A two-year-old girl with two weeks of abdominal pain, vomiting, and food refusal, ten months after percutaneous endoscopic gastrostomy insertion because of inadequate peroral intake, was admitted to a tertiary centre hospital. On admission, the extracorporeal part of the gastrostomy was much shortened. X-ray examination revealed migration of the end of the gastrostomy tube with a left-shifted course of the tube through the duodenum. Gastroscopy and subsequently laparotomy were performed. A longitudinal pressure necrosis was identified under the tube, with two perforations in the duodenojejunal region. Ten centimeters of that duodenojejunal region were resected, and end-to-end anastomosis was made. The migration of the gastrostomy was probably caused by insufficient care by the parents. Pathophysiologically, the tube caused the pressure necrosis in the duodenojejunal area; this was supported by histology. This is a hitherto undescribed complication of a percutaneous endoscopic gastrostomy, showing that migration of the gastrostomy to the deeper part of the small bowel can lead to pressure necrosis, a potentially life-threatening condition in children which cannot be treated without invasive procedures.

KEYWORDS

children; migration; percutaneous endoscopic gastrostomy; perforation; pressure necrosis

AUTHOR AFFILIATIONS

¹ Department of Pediatrics, Charles University, Faculty of Medicine in Hradec Králové; University Hospital Hradec Králové, Czech Republic

² Department of Pediatric Surgery and Traumatology, Charles University, Faculty of Medicine in Hradec Králové; University Hospital Hradec Králové, Czech Republic

³ Department of Radiology, Charles University, Faculty of Medicine in Hradec Králové; University Hospital Hradec Králové, Czech Republic

⁴ 2nd Department of Internal Medicine – Gastroenterology, Charles University, Faculty of Medicine in Hradec Králové; University Hospital Hradec Králové, Czech Republic

* Corresponding author: Department of Pediatrics, University Hospital Hradec Králové, Sokolská 581, Hradec Králové, 500 05, Czech Republic; e-mail: jan.melek@fnhk.cz

Received: 24 January 2020

Accepted: 7 May 2020

Published online: 10 August 2020

Acta Medica (Hradec Králové) 2020; 63(2): 79–81

<https://doi.org/10.14712/18059694.2020.21>

© 2020 The Authors. This is an open-access article distributed under the terms of the Creative Commons Attribution License (<http://creativecommons.org/licenses/by/4.0>), which permits unrestricted use, distribution, and reproduction in any medium, provided the original author and source are credited.

CASE REPORT

A two-year-old female patient with possible genetic abnormality with percutaneous endoscopic gastrostomy (PEG, Freka® 9 French = 3 mm, Fresenius Kabi) was admitted to a tertiary care center ten months after the tube insertion with a two-week history of intermittent abdominal pain, vomiting, and food refusal. She had no surgical history and was being treated with levothyroxine for mild hypothyroidism. The abdominal ultrasound did not reveal any pathology. Laboratory tests were overall unremarkable, except for mildly elevated C-reactive protein – 23 mg/l (normal: 0–5 mg/l). Stool testing for viruses (adenovirus, rotavirus, and norovirus) and bacteria did not identify any pathogenic agent. Anthropometric measurements were notable for underweight (weight 6.5 kg, –5.0 SD – standard deviation) and short stature (height 78 cm, –2.2 SD) with weight-for-height ratio –4.7 SD. The patient was afebrile, with a soft abdomen and small umbilical hernia. There were no clinical signs of peritoneal irritation. Atypically, the extracorporeal part of the gastric tube was much shortened to 6.5 cm (the regular length from internal bumper to the end of the tube is 31.5 cm).

An abdominal radiograph in standing position (Figure 1) revealed migration of the end of the gastrostomy tube with a left-shifted course of the tube through the duodenum without any other signs of pathology. The tube displacement to the small bowel was verified by the contrast study. Gentle pulling on the tube under radiologic control failed to reposition it. The same day a gastroscopy confirmed migration of the tube from the stomach through the antrum to the duodenum. The first duodenal section appeared normal, the middle was slightly distorted, and

in the distal part was revealed a suspicious ulcer under the tube. The tube seemed to disappear into the bowel wall in the distal duodenum (Figure 2). During the same anesthesia, the surgeon was called and performed a laparotomy. On opening the peritoneal cavity, the pneumoperitoneum was observed. Approximately 40 cm of the duodenum and mainly the jejunum was looped around the tube. Further, there was a longitudinal pressure ulcer with two perforations in the duodenojejunal region under where the tube lay (Figure 3). We did not notice any pathology around the internal bumper. A 10 cm resection of the affected duodenojejunal area was performed. The gastrostomy was removed without any complications, and a duodenojejunal end-to-end anastomosis was performed. The pressure origin of the lesion in the mentioned area was confirmed histologically. For postoperative feeding, a jejunal tube was inserted via the gastrostomy track. The postoperative course was without complications. The jejunal tube was replaced by a Foley catheter 14 days after the operation until a gastrostomy button will be placed. The patient was discharged from the hospital 21 days after the procedure. Five months after the surgery, the girl was without any problems connected to the operation.

DISCUSSION

In this case report, we present a two-year-old girl with a hitherto undescribed complication of a percutaneous endoscopic gastrostomy. No genetic background has yet been elucidated in our patient, but we do not expect it would influence the development of this complication. The indication for the PEG placement was failure to thrive. A poly-

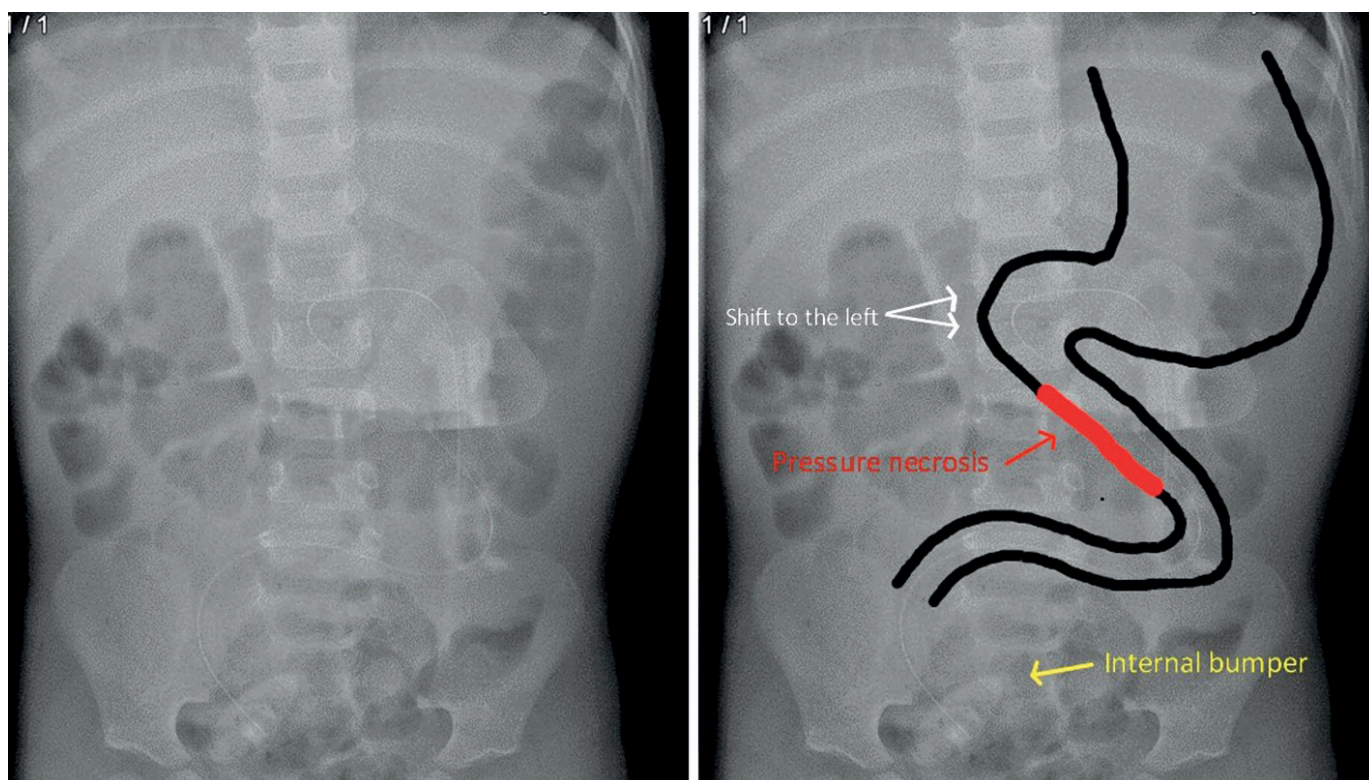


Fig. 1 A – Native x-ray, B – Illustration. The white arrows are showing a left-shifted course of the tube through the duodenum. The red arrow is pointing to the affected area by the pressure necrosis. The yellow arrow is showing internal bumper position.

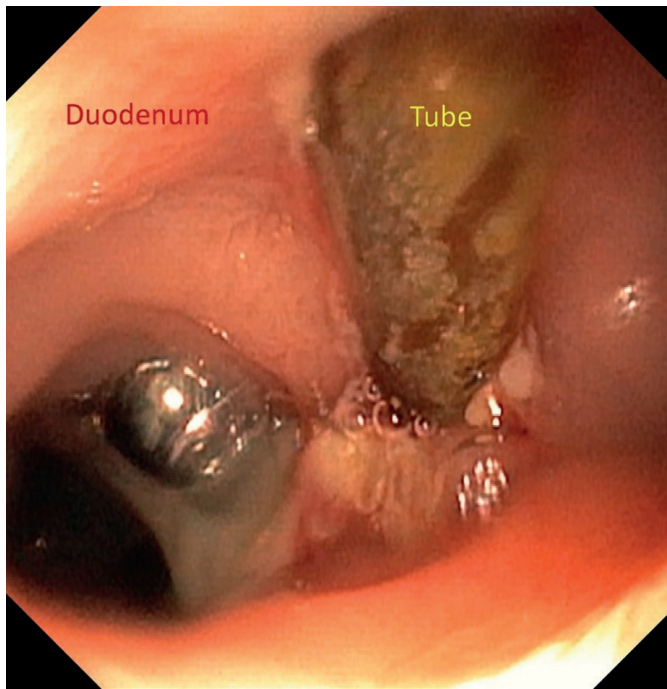


Fig. 2 Distal duodenum with the dislocated PEG tube. Fibrine plaques around the tube. The tube seems to disappear into the bowel wall.

meric formula (Nutrini®, Nutricia) was administered through the gastrostomy. We do not expect that the tube migration was affected by the PEG placement technique (pull method; insertion at the body and antrum junction), applied according to the ESPGHAN recommendations (1).

We presume that the inadequate care of the PEG tube by the parents played a critical role in the PEG migration, even though the parents were adequately instructed by a doctor and a nurse and the gastrostomy was checked two and six months after the placement. This notion was supported one month after the hospitalization when the girl was readmitted with obstructive ileus caused by migration of the Foley catheter with obstruction of the first part of the duodenum by the balloon. However, it can be accepted that a Foley catheter can be more challenging to take care of because there is no external fixation plate. We predict the child may benefit from a gastrostomy button or a balloon gastrostomy. Apart from that, we did not notice any other signs of deficient care or signals indicating child abuse and neglect syndrome. The mentioned clinical signs (abdominal pain, vomiting) could be consistent with the duodenal damage (2), but they could also be evoked by the unintentional “bolus” feeding to the small bowel. Pathophysiologically, we assume the injury in the duodenojejunal area was caused by pressure necrosis induced by the tube (3). We suspect that this damage, as well as the left shift of the course of the tube through the duodenum, were exaggerated by pull on the tube by the peristalsis. Although we did not notice any perforation during the endoscopy, we suspect the artificial inflation in combination with the severely affected area could cause definitive rupture of the bowel wall. Nevertheless, based on the periop-

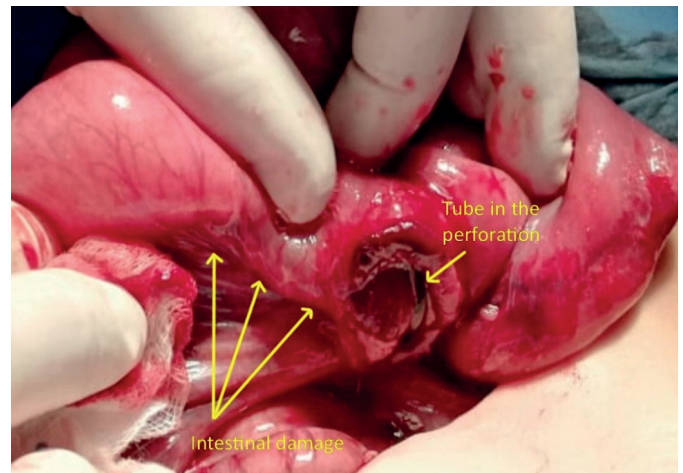


Fig. 3 Longitudinal bowel injury with the perforation and the tube in the duodenojejunal region.

erative finding supported by histology, it was proven that the major duodenal damage was caused by the migrated tube.

In conclusion, we showed that migration of the gastrostomy to the deeper part of the small bowel could not be treated without invasive procedures, and moreover can lead to a very severe or even life-threatening condition. In the case of “inappropriate” external shortening of the tube in a young child, we suggest providing an x-ray imaging study with the perspective that other more invasive examination methods may be needed. If this type of complication is proven, the patient will probably require an acute surgical procedure.

ACKNOWLEDGEMENTS

The authors are grateful to Ian McColl, MD, PhD for assistance with the case report manuscript.

CONFLICT OF INTEREST

None declared.

FUNDING

The study was not funded.

REFERENCES

1. Heuschkel RB, Gottrand F, Devarajan K, et al. ESPGHAN position paper on management of percutaneous endoscopic gastrostomy in children and adolescents. *J Pediatr Gastroenterol Nutr* 2015; 60(1): 131–41.
2. Saranga Bharathi R, Rao P, Ghosh K. Iatrogenic duodenal perforations caused by endoscopic biliary stenting and stent migration: an update. *Endoscopy* 2006; 38(12): 1271–4.
3. Kim HS, Moon HJ, Lee NY, et al. Endoscopic management of duodenal perforations caused by migrated biliary plastic stents. *Endosc Int Open* 2019; 7(6): E792–E5.

Candida Skull Base Osteomyelitis: a Case Report and Literature Review

Madhusudhan Krishnamoorthy^{1,*}, Nik Adilah Nik Othman¹, Nor Eyzawiah binti Hassan^{2,3},
Shahrul bin Hitam³

ABSTRACT

Skull base osteomyelitis (SBO) also commonly known as malignant otitis externa was first described by Meltzer and Kelemen in 1959. Prior to the advent of the antibiotic era, this disease carried a poor prognosis with significant morbidity. It often proved fatal with mortality rates as high as 50%. Commonly seen in the immunocompromised patients, diabetes mellitus is an important associated comorbidity in the pathophysiologic development of this disease. Treatment is instituted by medical therapy with surgery having a limited role. Surgical intervention has a limited role, for example, in fungal SBO. Such cases may require local debridement and intraoperative tissue biopsies for histopathologic confirmation. This is to demonstrate fungal invasion into the skull base, as well as to exclude other sinister differential diagnoses like squamous cell carcinoma of temporal bone. In this case report, we present a rare case of candida SBO and the literature review.

KEYWORDS

skull base; osteomyelitis; fungal; candida; otitis externa

AUTHOR AFFILIATIONS

¹ Department of Otorhinolaryngology and Head & Neck Surgery, Hospital Universiti Sains Malaysia, School of Medical Sciences, Kubang Kerian, Kelantan, Malaysia

² Faculty of Medicine and Health Sciences, Universiti Sains Islam Malaysia (USIM), Pandan Indah, Selangor, Malaysia

³ Department of Otorhinolaryngology and Head & Neck Surgery, Hospital Ampang, Selangor, Malaysia

* Corresponding author: Department of Otorhinolaryngology and Head & Neck Surgery, Hospital Universiti Sains Malaysia, School of Medical Sciences, Kubang Kerian, Kelantan, Malaysia; e-mail: kmadhu_87@yahoo.com

Received: 15 November 2019

Accepted: 22 May 2020

Published online: 10 August 2020

Acta Medica (Hradec Králové) 2020; 63(2): 82–85

<https://doi.org/10.14712/18059694.2020.22>

© 2020 The Authors. This is an open-access article distributed under the terms of the Creative Commons Attribution License (<http://creativecommons.org/licenses/by/4.0>), which permits unrestricted use, distribution, and reproduction in any medium, provided the original author and source are credited.

INTRODUCTION

Skull base osteomyelitis (SBO) is usually caused by *Pseudomonas aeruginosa* (1). Various other microorganisms such as fungi may attribute to the development of SBO (2). A common fungal pathogen responsible is the *Aspergillus* species (3). Our patient, an elderly diabetic, presented with classical symptoms of nocturnal excruciating otalgia and ear discharge. On further investigation however, the etiologic agent was found to be *Candida* species.

CASE PRESENTATION

Informed consent was taken from the patient prior to the commencement of clinical examination, investigation and treatment.

A 60-year-old male presented to us with history of right sided earache associated with ear discharge of one-week duration. The otalgia was described as nocturnal and excruciating in nature, disturbing his sleep. There was no history of reduced hearing, and no complaints of vertigo. Otherwise, there were no complaints over the left ear. He had long standing diabetes mellitus of approximately 20 years requiring insulin therapy for optimization of blood sugar levels. Due to the unsatisfactory diabetic control, he suffered from chronic kidney disease however he did not require renal replacement therapy. He also had a left sided below knee amputation 1-year prior as complications of his poorly managed sugar levels. Clinical examination revealed a narrowed and edematous ear canal, with presence of granulation tissue along the floor of the ear canal. The tympanic membrane was intact, however dull in appearance. He was treated as skull base osteomyelitis with topical ciprofloxacin drops (Tarivid Otic; Daiichi Sankyo, Tokyo, Japan) and systemic ciprofloxacin tablets (C-Flox; Intas Pharmaceuticals, Ahmedabad, India). There was no compromise in any of the cranial nerves functions, espe-

cially the facial nerve. Patient was managed on an outpatient basis as his compliance to medication was good, and he was monitored on a fortnightly basis.

Eight weeks after his first presentation, he complained of a painless right sided facial swelling. Clinical examination revealed a vague right pre-auricular fullness, approximately 4 × 3 cm, circular shaped, smooth surfaced, with ill-defined margins. Otoendoscopy of the right ear revealed a narrowed ear canal, with granulation tissue along the floor of the canal, just like the initial presentation. Patient was admitted for treatment with empirical intravenous ciprofloxacin (Ciproxol; Ain Medicare, Kota Bharu, Malaysia) antibiotics (dosed adjusted based on the underlying impaired kidney functions to prevent nephrotoxicity). His blood investigations revealed hemoglobin of 9.6 g/dL, total white cell count of 10.9 K/ μ L, urea 8.9 mmol/L, and creatinine of 205 mmol/L. His ESR (erythrocyte sedimentation rate) was elevated, 90 mm/hour. A swab taken from the ear for culture and sensitivity prior to commencement of antibiotics confirmed *Candida albicans* infection (Figure 1). He was then treated with systemic anti-fungal (Fluconazole; Pharmaniaga, Bangi, Malaysia) therapy. Biopsies taken from the granulation tissue were confirmatory for inflammatory granulation tissue and ruled out malignancy. There was no fungal hyphae or spores seen on histopathologic examination. An urgent high-resolution computed tomography (HRCT) of the temporal bone was done (Somatom Perspective syngo CT VC30 machine; Siemens, Erlangen, Germany). There was bony erosion along the greater wing of the right sphenoid with osteomyelitic changes (Figure 2). There was also erosion of the anterior wall of the right ear canal (Figure 3). The stylomastoid foramen and adjacent stylomastoid process showed inflammation (Figure 4). The right middle ear cavity and mastoid air cells were filled with soft tissue densities, however there was no destruction of the ossicles or the scutum (Figure 5). After 2 weeks of medical therapy using antimicrobials, there was marked resolution in otalgia, and he was able to sleep well

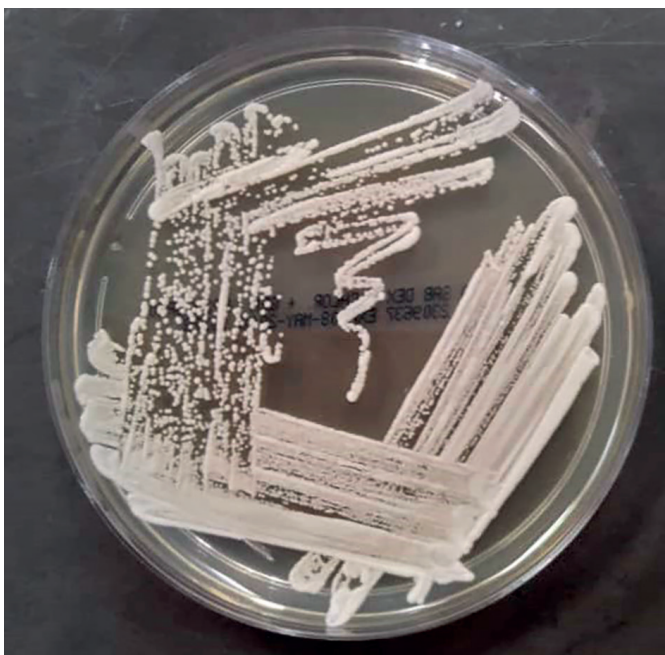

Fig. 1 *Candida albicans* culture.

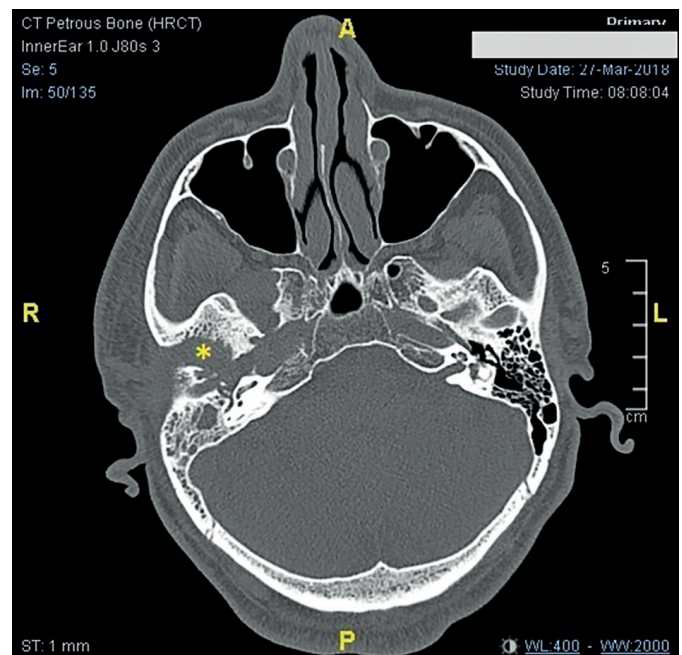


Fig. 2 Erosions along the greater wing of right sphenoid marked as*.

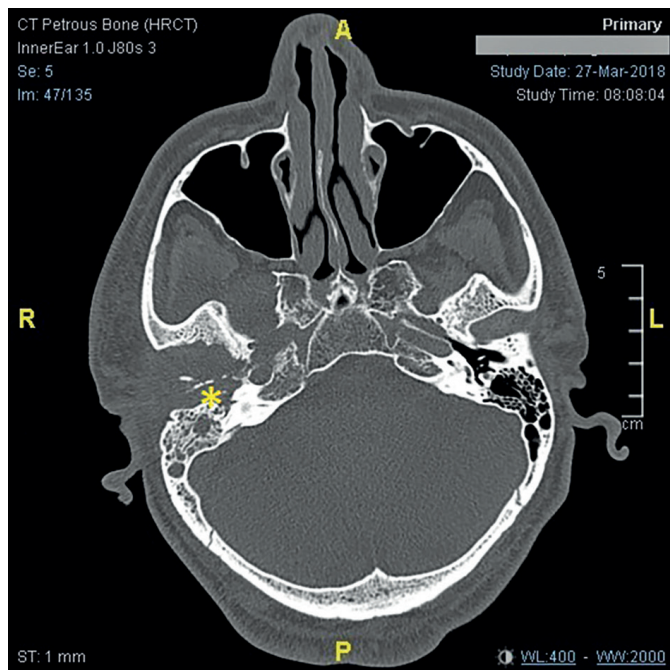


Fig. 3 Erosions along the anterior wall of right external auditory canal marked as *.

at night. Patient was satisfied with his treatment outcome and was discharged home well.

During his one-week post discharge review, the granulation tissue was noted to persist (Figure 6) despite patient's compliance to daily anti-fungal therapy (fluconazole tablets). Patient was advised for a repeat biopsy to rule out other sinister pathologies such as squamous cell carcinoma of the temporal bone, and for surgical intervention, but he refused. Subsequently, he did turn up for his following appointment.

DISCUSSION

The first documentation of progressive temporal bone osteomyelitis dates back to 1838 by Toulmouche (3). Orogenic SBO was first described by Meltzer and Kelemen in 1959 (4). The term malignant otitis externa is a misnomer as it does not define a neoplastic disease (5) and this term is used interchangeably with SBO. It was coined by Chandler in 1968 to describe the aggressive nature of destruction caused by *Pseudomonas aeruginosa* in the ear canal and spreading infection to the skull base (6). Later in 1985, Petrak et al. described the first case of fungal malignant otitis externa (7). Risk factors attributable to the development of SBO include, elderly age of more than 60 years, diabetes mellitus and an immunocompromised state. Diabetes mellitus is an important associated comorbidity in SBO patients, with a prevalence as high as 90–100% of all SBO patients (8). Various other conditions predisposing to SBO are Human Immunodeficiency Virus (HIV) infection, chemotherapy induced aplasia and chronic leukemia (7, 8). In fungal SBO patients, more than 70% have underlying diabetes mellitus (2). There are a few routes of fungal infection spread in the pathogenesis of SBO. They are i) via the external ear canal, the infection spreads through the Santorini fissures and medially to the tympanomastoid

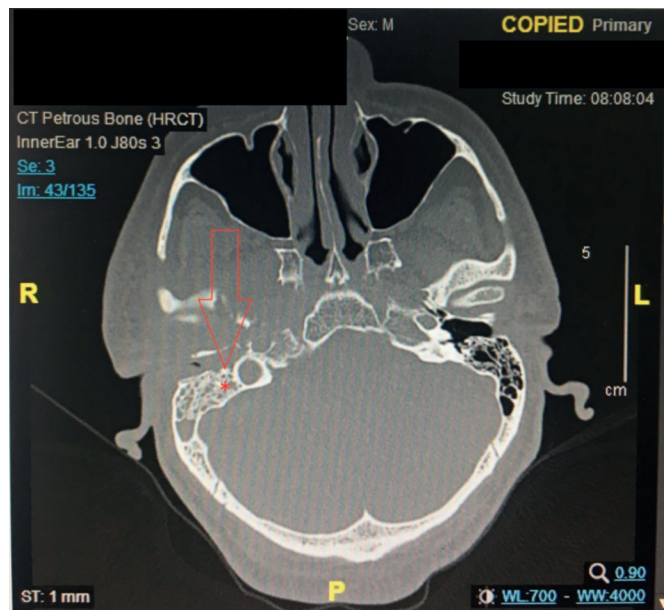


Fig. 4 Inflammation around the stylomastoid foramen and stylomastoid process.

suture (6, 8), ii) via the internal acoustic meatus in cases of fungal meningitis, iii) via the Eustachian tube and iv) via hematogenic spread. Very rarely, it follows a paranasal sinus fungal infection (6). The reason for developing SBO in diabetic patients is attributable to the endarteritis and microangiopathy causing small vessel obliteration (8).

Although the most common etiologic agent for fungal SBO is *Aspergillus fumigatus* (6, 8), cases of *Candida* species similar to our case have been reported in literature (1, 9). A case of proven (definite) SBO is defined as skull base infection with symptoms and signs localizing at presentation, with radiologic evidence of bone erosion and isolation of organism from the affected bone. A probable SBO however, is when the organism is isolated from a source other than bone or tissue (for example, from an ear swab) (2). As seen in our case, fungal SBO is more rapid to present (mean time to presentation of 8 weeks, as compared to 26 weeks for bacterial SBO) (2). The typical presentation is a patient who is 60 years old or older, with underlying diabetes complaining of unremitting earache and headache. Classically fever is absent. They may also present with a swelling in the preauricular region (4). Blood investigations reveal absent leukocytosis with markedly elevated erythrocyte sedimentation rate (ESR) (8–10). In severe cases, cranial nerve palsy occurs, commonest being the facial nerve (cranial nerve VII) (2, 8, 9) due to the proximity of the ear canal to the stylomastoid foramen. The next common group of cranial nerves to be involved are the nerves in the jugular foramen, namely the glossopharyngeal, the vagus and the spinal accessory (cranial nerves IX, X and XI respectively) (8). Clinical examination usually reveals granulation tissue in the ear canal. Our case was similar to the other reported literatures where ear swab grew *Candida albicans* and biopsy of granulation tissue taken from the ear canal was negative for malignancy (4, 9, 10). This presence of granulation tissue seems to indicate a good treatment outcome in fungal SBO (7). However, it is important to remember that in

Tab. 1 Etiology of origin for SBO.

Skull base osteomyelitis						
Sinorhino – otogenic origin			Non Sinorhino – otogenic origin			
Anterior skull base	Middle skull base	Posterior skull base	Trauma	Iatrogenic	Hematogenous	Others

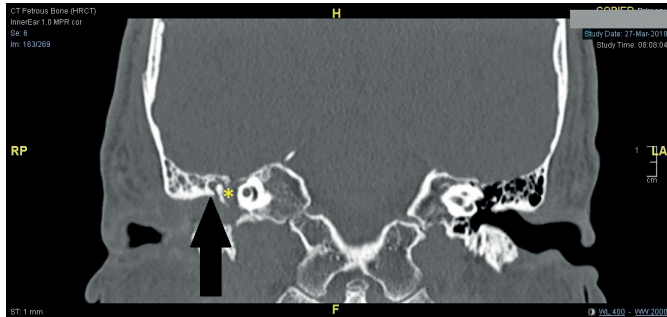


Fig. 5 Soft tissue density in the middle ear cavity and mastoid air cells, neither violating the scutum (black arrow) nor violating the ossicles (*).

cases of recalcitrant disease not responding to treatment, a differential diagnosis of squamous cell carcinoma of the temporal bone must be born in mind. This is because cases of early carcinomas may be misleading and such cases may be presumed to be as SBO (5). Therefore, there is a role of tissue biopsy under general anesthesia for cases of probable SBO.

SBO can be classified based on etiologic origin as seen in Table 1 (3). Fungal SBO infection usually originates from the middle ear cavity or the mastoid air cells (6–8). In our case report, HRCT imaging showed evidence of middle ear destruction with soft tissue density seen in the mastoid air cell system (9, 10), however the ossicles and scutum were not violated. HRCT is sensitive to detect bony erosions and defects, however inadequate to monitor treatment response. As such other imaging modalities are needed such as Technetium 99m-methyl diphosphonate (Tc-99m Mdp) bone scan as well as Gallium scan. Both of these modalities are complementary to diagnose and monitor SBO (8). Treatment constitutes prolonged antibiotic therapy (6) with quinolones due to good bioavailability and effective bone penetration. Aggressive control of blood sugar levels is also crucial. In cases of fungal SBO systemic as well as topical antifungals are required in medical treatment (9, 10). There is a role of surgical therapy in fungal SBO (2), however its role is limited to biopsy, debridement and drainage of abscesses (3, 8). Hyperbaric oxygen therapy has been documented in literature as a useful adjunct, however due to the restricted availability and minimal evidence based results, it is not a common practice (3, 9). Long term survival is based on severity of disease, rather than a particular therapeutic regime (7). Prognosis is largely dependent on the underlying immune status of the patient (6).

CONCLUSION

SBO is an uncommon disease, usually resulting as a complication from an uncontrolled otogenic, odontogenic or sinus infection. Almost half (48%) of SBO patients may develop

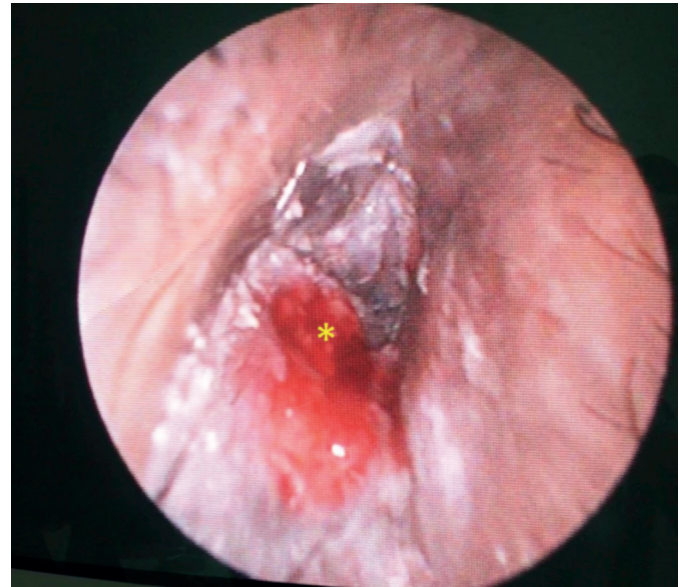


Fig. 6 Persistent granulation tissue.

persistent cranial nerve abnormalities (2). Mortality due to invasive mycosis of the lateral skull base was reported in literature to be approximately 27% (6). Therefore, a multi-disciplinary team approach is needed in the treatment of SBO. The main treatment aim should be culture directed therapy (3) and long term antibiotics (8). In summary, SBO should be suspected in an elderly patient who is a diabetic presenting with otalgia and otorrhoea and if granulation tissue is seen in the ear canal (8). A high index of suspicion is required for diagnosing a fungal cause of lateral SBO especially if there is an intractable course of treatment.

REFERENCES

1. Volsky PG, Hillman TA. Fungal skull base osteomyelitis: Emerging microbial identification techniques. *Laryngoscope* 2017; 127(1): E5-E7.
2. Blyth C, Gomes L, Sorrell T, Da Cruz M, Sud A, Chen SA. Skull-base osteomyelitis: fungal vs. bacterial infection. *Clinical Microbiology and Infection* 2011; 17(2): 306–11.
3. Mortazavi MM, Khan MA, Quadri SA, et al. Cranial Osteomyelitis: A Comprehensive Review of Modern Therapies. *World Neurosurgery* 2018; 111: 142–53.
4. Meltzer PE, Kelemen G. Pyocyanous osteomyelitis of the temporal bone, mandible and zygoma. *Laryngoscope* 1959; 69(10): 1300–16.
5. Gleeson MJ, Clarke RC. *Scott-Brown's Otorhinolaryngology: Head and Neck Surgery*. 7th Ed. CRC Press 2008.
6. Stodulski D, Kowalska B, Stankiewicz C. Otogenic skull base osteomyelitis caused by invasive fungal infection. *European Archives of Oto-Rhino-Laryngology and Head & Neck*. 2006; 263(12): 1070–6.
7. Yao M, Messner AH. Fungal malignant otitis externa due to *Scedosporium apiospermum*. *Annals of Otolaryngology & Rhinology* 2001; 110(4): 377–80.
8. Carfrae MJ, Kesser BW. Malignant otitis externa. *Otolaryngologic Clinics of North America* 2008; 41(3): 537–49.
9. Bowles PF, Perkins V, Schechter E. Fungal malignant otitis externa. *BMJ Case Reports* 2017; 2017: bcr2016218420.
10. Shelton JC, Antonelli PJ, Hackett R. Skull base fungal osteomyelitis in an immunocompetent host. *Otolaryngology - Head and Neck Surgery* 2002; 126(1): 76–8.

Pierre Robin Sequence: Diagnostic Difficulties Faced while Differentiating Isolated and Syndromic Forms

Girish Gulab Meshram^{1,*}, Neeraj Kaur², Kanwaljeet Singh Hura³

ABSTRACT

Pierre Robin sequence (PRS) is characterized by the triad of retrognathia, glossoptosis, and airway obstruction. PRS may occur in isolation or in conjunction with other syndromes. Distinguishing isolated and syndromic forms of PRS helps clinicians decide the management plan. We describe two cases of PRS of Indian ethnicity and describe some of the difficulties that we faced while distinguishing isolated PRS from syndromic PRS. Both cases had a similar clinical presentation. However, one of the cases had a positive family history of congenital deafness and cleft palate, whereas the other case had apparent upper limb anomalies. These facts heightened the suspicion of an associated syndrome. However, based on the available facts and after thorough investigations, a tentative diagnosis of isolated PRS was made for both the patients. Both the cases were managed conservatively and were advised a long-term follow-up. When the associated anomalies are few, minor or concealed at birth, longitudinal follow-up of all PRS cases combined with thorough diagnostics including chromosomal analysis could help differentiate syndromic PRS from isolated PRS. Regardless, all cases of PRS require a multidisciplinary approach.

KEYWORDS

Pierre Robin syndrome; retrognathia; amniotic band syndrome; limb deformities

AUTHOR AFFILIATIONS

¹ Department of Pharmacology, Atal Bihari Vajpayee Institute of Medical Sciences and Research and Dr. Ram Manohar Lohia Hospital, New Delhi, India

² Department of Radiology, The University of Texas Health Science Centre, San Antonio, Texas, USA

³ Department of Paediatrics, Richmond University Medical Centre, Staten Island, New York, USA

* Corresponding author: Department of Pharmacology, Atal Bihari Vajpayee Institute of Medical Sciences and Dr. Ram Manohar Lohia Hospital, New Delhi 110001, India; e-mail: drgirish23@yahoo.co.in

Received: 10 June 2019

Accepted: 7 February 2020

Published online: 10 August 2020

Acta Medica (Hradec Králové) 2020; 63(2): 86–90

<https://doi.org/10.14712/18059694.2020.23>

© 2020 The Authors. This is an open-access article distributed under the terms of the Creative Commons Attribution License (<http://creativecommons.org/licenses/by/4.0>), which permits unrestricted use, distribution, and reproduction in any medium, provided the original author and source are credited.

INTRODUCTION

Pierre Robin sequence (PRS) is the triad of retrognathia, glossoptosis, and airway obstruction. Cleft palate is frequently encountered, but is not considered as a prerequisite for the diagnosis (1). Epidemiological data are sparse, though available evidence suggests the incidence of PRS ranges from 1 in 5600 to 1 in 14000 live births (1, 2). Symptoms include varying degrees of upper airway obstruction and feeding problems. PRS occurs in isolation or as a part of other syndromes such as Stickler, velocardio-facial, and Treacher-Collins syndromes (3). Because the severity of symptoms, presence of long-term sequelae, requirement of surgery, and mortality rate in syndromic PRS are much higher than non-syndromic/isolated PRS, early differentiation between the two is beneficial to clinicians as it increases their preparedness and helps them take decisions regarding the management plan (1, 4, 5). However, the phenotypic heterogeneity of the various associated syndromes, make it very hard for clinicians to distinguish between the two (3). This ordeal is more pronounced when the associated congenital anomalies are few, minor, or concealed at birth as in the case of Stickler syndrome (6). The lack of chromosomal diagnostics in developing nations for phenotype-genotype correlation adds to this obstacle (7). In this paper, we describe two cases of PRS of Indian ethnicity and describe some of the difficulties that we faced while differentiating syndromic PRS from non-syndromic PRS. This paper also includes the review of up to date literature and the latest trends in management of PRS.

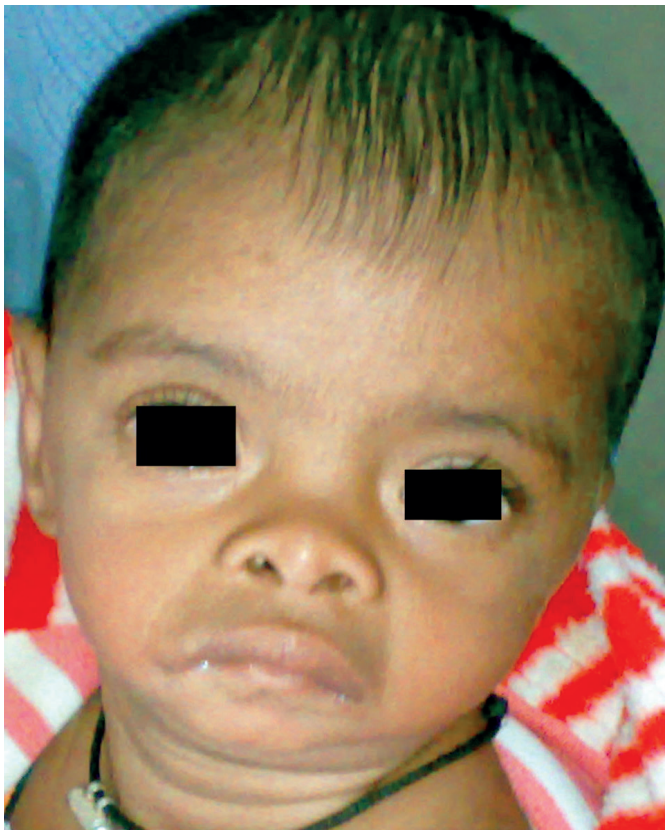

Fig. 1 A 2-month-old infant with isolated Pierre Robin sequence (Case 1).

CASE PRESENTATION

Case 1 was a 2-month-old male infant and Case 2 was a 2-day-old male newborn (Figure 1 and Figure 2). Both were of Indian ethnicity and had visited the pediatric outpatient department with their parents. Both cases were referred to the department of pediatrics from peripheral healthcare centers, where specialists were not available.

Both patients presented with congenital facial deformities and difficulty in breathing. Case 1 had difficulty in breathing while lying down, whereas Case 2 had respiratory distress in both lying down and upright positions. Case 1 was born via normal vaginal delivery at 37 weeks of gestation with a birth weight of 3 kg (appropriate for gestational age) without complications and was second in birth order. Case 2 was born to a primigravida via normal vaginal delivery at 40 weeks of gestation with a birth weight of 3.6 kg (appropriate for gestational age), but the pregnancy was complicated with preeclampsia, which was managed with magnesium sulfate. The parents of both patients had a non-consanguineous marriage. Case 1 had a cousin with history of cleft palate and congenital deafness, whereas none of the close family members of Case 2 had a history of congenital anomalies. History of alcohol consumption during pregnancy or radiation exposure was absent in mothers of both patients. Except for consumption of magnesium sulfate by the mother of Case 2, no significant drug history was present in both patients.

On examination, both patients had small-sized mandibles, which were deflecting backwards (micrognathia) (Figure 1 and Figure 2). Cleft palate and bifid uvula were absent in both cases. Examination of the cardiovascular, musculoskeletal, and central nervous systems of Case 1 did not indicate the presence of any other congenital anomaly. Examination of the cardiovascular and central nervous system of Case 2 did not reveal any abnormality. However, examination of the musculoskeletal system of Case 2 revealed absence of four digits in the right upper limb (Figure 2). The respiratory rates of Case 1 and Case 2 were 42 and 48 breaths/minute, respectively. Both cases had

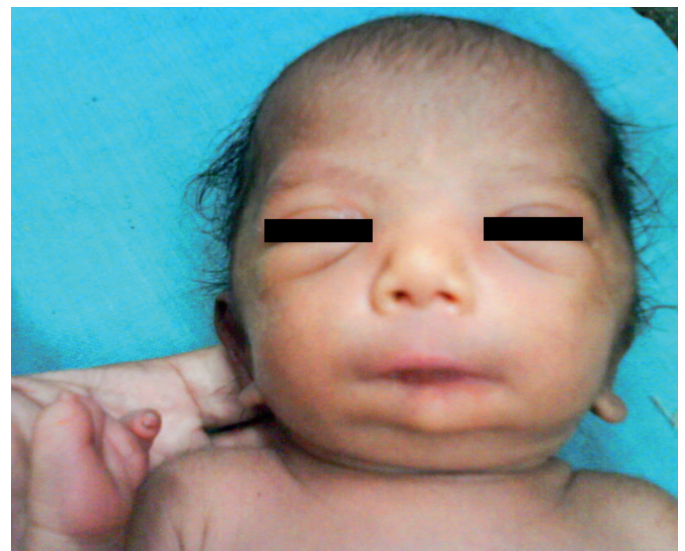

Fig. 2 A 2-day-old neonate with Pierre Robin sequence and absence of 4 digits in the right upper limb (Case 2).

labored breathing without any signs of cyanosis. Case 2, in addition, had mild intercostal recessions. The complete blood count (red blood cell count, hemoglobin, hematocrit, white blood cell count, and platelet count), liver function tests (total bilirubin, serum aminotransferase, and serum alkaline phosphatase), and kidney function tests (blood urea nitrogen, and serum creatinine) levels in both patients were within reference ranges. X-ray chest of both patients did not reveal any abnormality. X-ray of the right upper limb of Case 2 showed absence of the phalanges in four digits, except the thumb. The metacarpals and carpals of all five digits appeared normal. Two-dimensional echocardiography findings of both patients were found to be normal. Ophthalmological examination of both patients did not show any abnormalities. Otoscopy and otoacoustic emission screening test for sensorineural deafness were negative for both patients. The background of congenital deafness in one of the family members of Case 1 made him a high-risk patient for hearing loss. Hence, we wanted to thoroughly investigate him further to rule out the same. Hence, we advised him an auditory brainstem response test (ABR). ABR is a noninvasive measure of sensorineural and conductive hearing loss, wherein electrodes are attached to the scalp of the child via stickers and the responses of the auditory nerve, cochlea and brainstem to various auditory stimuli are measured electronically. In order to assist the diagnosis, rule out associated syndromes and determine the hereditary pattern, we advised genetic testing to both patients. For Case 1 we advised detection of deletion of 22q11 chromosome via fluorescence in situ hybridization to rule out association with velocardiofacial syndrome, and mutations in COL2A1 gene via polymerase chain reaction to rule out association with Stickler syndrome. For Case 2 we advised detection of mutations in SF3B4 and TCOF1 genes via polymerase chain reaction to rule out an association with acrofacial dysostosis syndrome and Treacher-Collins syndrome, respectively.

Both ABR and molecular tests were declined by the patient's families due to their financial limitations.

As Case 1 had a family history of congenital hearing loss and the presence of sensorineural hearing loss was not completely ruled out due to the impending ABR, we considered PRS associated with Stickler syndrome or velocardiofacial syndrome in our differential diagnosis. However, as no other apparent malformations were present in Case 1, suggestive of these syndromes, we made a diagnosis of isolated PRS. Similarly, due to the presence of upper limb anomalies in Case 2, we initially considered PRS associated with acrofacial dysostosis syndrome or Treacher-Collins (Rodriguez, Nager, and Miller subtypes) syndrome. However, the limb anomalies in Case 2 could be also explained by the presence of a constricting amniotic band in the *in utero* period leading to autoamputation of the digits, which seemed more consistent. Hence, Case 2 too was diagnosed as a case of isolated PRS complicated due to an amniotic band.

Both patients were admitted and were advised prone positioning. Oxygen saturation levels of Case 1 and Case 2 were 98.2% and 93.4%, respectively, at the time of admission. The breathing of Case 1 improved with prone-positioning. Hence, his parents were provided appropriate

guidance of prone positioning the child when the respiratory distress increased. The breathing difficulty of Case 2 did not improve with prone positioning. Hence, a nasopharyngeal airway was placed and supplemental oxygen was provided, which improved the oxygen saturation to 98%. Both respiratory and feeding difficulties of Case 2 subsided on day-5 of admission. Both patients were subsequently discharged and anticipatory guidance was provided to their parents. A longitudinal follow-up was advised for both patients with consultation with various faculties such as pediatrics, ophthalmology, otorhinolaryngology, orthopedics, and dentistry. Both patients were requested to follow-up at regular intervals of 2 months for a minimum period of 5 years. Both the cases have not followed up so far. Before their discharge, a written informed consent was obtained from the legally authorized representatives of both patients for anonymized patient information to be published in this case report.

DISCUSSION

PRS is a set of abnormalities affecting the head and face, consisting of micrognathia (small and symmetrically recessed mandible), glossoptosis (tongue that obstructs the posterior pharyngeal space), and resultant airway obstruction (3). Cleft palate is found in almost 90% of the cases (8). However, in both our cases cleft palate was absent.

Ultrasound imaging helps in the prenatal diagnosis of severe cases of PRS and helps specialists plan the further course of pregnancy and postnatal care (8, 9). As both our cases had been evaluated outside our hospital during their prenatal period, we could not detect the presence of abnormal ultrasound findings, suggestive of PRS, such as retrognathia/micrognathia. Also, maternal factors such as oligohydramnios, multigravida pregnancy, and uterine anomalies which could hinder the mandibular growth of the child could be detected early via ultrasonography (9).

The various hypotheses suggested behind the etiology of PRS include *in utero* mechanical compression of the mandible, delay in neurological maturation of the nerves supplying the affected areas, and dysregulation of the rhombocephalus (2, 3, 10). *De novo* mutations in the SOX9 and KCNJ2 genes are linked with non-syndromic/isolated PRS (2, 10). Isolated PRS accounts for around 20-40% of all cases of PRS (2). Once afflicted with isolated PRS, the inheritance pattern followed is autosomal dominant (9). Common medical syndromes with which PRS occurs in conjunction include Stickler, Nager, velocardiofacial, 22q11 deletion, fetal alcohol, and Treacher-Collins syndromes (11, 12). Genetic mutations such as COL2A1, SF3B4, and TCOF1 causing these associated syndromes are implicated in the etiology of syndromic PRS (10, 11). Once afflicted with syndromic PRS, the inheritance pattern followed is the same as the associated condition (9, 11). In both our cases, we could not determine the genetic basis of the etiology via chromosomal studies due to the economic constraints of our patients. Differentiating isolated PRS from syndromic PRS provides insights into the etiology, which in turn determines the pathogenesis and the clinical presentation (4).

In the outpatient department, patients with PRS usually present with a characteristic bird-like face with variable degrees of breathing/feeding difficulties, as found in both our patients (2, 13). When the triad of PRS is spotted, the physician should have an heightened index of suspicion for other anomalies and a detailed family history of congenital anomalies should be elucidated (6, 8). As one of our cases had a family history of congenital hearing loss and cleft palate in a second-degree relative, and the other had apparent upper limb malformations, we initially suspected syndromic PRS in both the cases. Cleft palate and sensorineural hearing loss along with PRS is commonly associated with Stickler and velocardiofacial syndrome (14). Similarly, presence of limb malformations along with PRS is commonly associated with acrofacial dysostosis or Treacher-Collins (Rodriguez, Nager, and Miller subtypes) syndromes (9, 14).

As more than 50 syndromes have been associated with PRS and each of these syndromes have a vast heterogeneity in their respective presentations, it often becomes very difficult for clinicians to accurately identify the associated syndrome (3, 5). We faced a similar predicament. Also, when the anomalies are not apparent at birth or are minor, as in the case of Stickler's syndrome, diagnosis of syndromic PRS is often missed (2, 6). In such situations, a longitudinal follow-up with detailed chromosomal diagnostics has been suggested for identification of the associated syndrome (4, 8). However, in most economically-deprived nations, genotype-phenotype correlation is not commonly carried out due to economic constraints of patients, or unavailability of expert knowledge (7). Such was our case too.

In each of our cases, via radiological imaging and other diagnostics, we systematically tried to rule out other anomalies. However, due to the absence of other detectable congenital anomalies in Case 1 and the upper limb deformities in Case 2 explainable by an *in utero* amniotic band, we diagnosed both cases as isolated PRS (2, 15). However, both these diagnoses were formed without the support of genetic studies. It has been reported that if PRS infants are followed-up until childhood along with appropriate genetic diagnostics, the diagnosis changes in 25% of the cases because with course of time the symptomology of numerous syndromes becomes more apparent or new anomalies are developed (4, 8).

Many believe that delineating syndromic PRS from isolated PRS is crucial as it influences the choice and outcome/efficacy of the management strategy (4). Clinicians mainly focus on the management of the morbidities caused due to PRS (1, 2). The severity of the airway obstruction even in non-syndromic PRS cases requires the use of fiberoptic investigations for exclusion of congenital abnormalities as well as for local description of the degree of obstruction (16). Managing respiratory obstruction is prioritized over addressing feeding dysfunction (2, 3). Algorithms such as the Vancouver Classification for the airway management of PRS have been devised by institutes to individualize the selection of the management plan (5). However, no consensus is present regarding the selection of the management plan in the literature (12). Prone positioning, placing a nasopharyngeal airway, providing continuous positive airway pressure, and using a laryngeal mask airway are

the common noninvasive techniques used to relieve the airway obstruction (1-3). Supplemental feeding using a nasogastric/orogastric tube (mild cases) and gastrostomy tube (chronic and persistent cases) helps resolving feeding difficulties (1, 13). Almost 70% of PRS cases respond to conservative management, as our patient's did (4).

As a substantial set of the population with PRS achieve normal or near-normal mandibular size within a few years of birth, the cornerstone in the management of PRS is conservative therapy (2, 4). Hence, we chose to manage both the patients conservatively and follow them up on regular intervals. Surgical interventions are only needed when all conservative measures are exhausted (3, 4). A report suggested that syndromic PRS cases have a higher requirement of surgical interventions and have poorer outcomes, as compared to isolated PRS (5). Surgical therapies used to relieve airway obstruction include tongue-lip adhesion, mandibular distraction osteogenesis, subperiosteal release of the floor of the mouth, and tracheostomy (3, 8).

It has been observed that the mortality and complication rates in syndromic PRS are much higher than isolated PRS (1, 17). The secondary effects of PRS include failure to thrive, developmental delays, dental anomalies, gastroesophageal reflux, sleeping difficulties, speech disorders, psychological disorders, cardiac failure, and brain damage (1, 3). Hence, considering the constellation of sequelae and complications, which could arise in the clinical course of the disease, a long-term follow-up by a multidisciplinary team of experts is essential for developing an individualized management strategy for patients with PRS (2, 3, 8).

CONCLUSIONS

We presented two cases of isolated PRS of Indian ethnicity. We faced numerous hurdles while differentiating isolated PRS from syndromic PRS, which we have enumerated in our case report. We managed both patients successfully via symptomatic conservative management. Differentiating isolated PRS from syndromic PRS helps clinicians take decisions regarding the management plan, taking into consideration the differences in their complication, morbidity, and mortality rates. Regardless, we recommend a longitudinal follow-up of all PRS cases via a multidisciplinary team, augmented with genetic diagnostics, for devising a dynamic and personalized management plan.

CONFLICT OF INTEREST

The authors disclose no conflicts of interest.

REFERENCES

1. Logjes RJH, Haasnoot M, Lemmers PMA, et al. Mortality in Robin sequence: identification of risk factors. *Eur J Pediatr* 2018; 177: 781-9.
2. Gangopadhyay N, Mendonca DA, Woo AS. Pierre Robin Sequence. *Semin Plast Surg* 2012; 26: 76-82.
3. Evans KN, Sie KC, Hopper RA, Glass RP, Hing AV, Cunningham ML. Robin sequence: from diagnosis to development of an effective management plan. *Pediatrics* 2011; 127: 936-48.
4. Basart H, Paes EC, Maas SM, et al. Etiology and pathogenesis of robin sequence in a large Dutch cohort. *Am J Med Genet A* 2015; 167A: 1983-92.

5. Li WY, Poon A, Courtemanche D, et al. Airway management in Pierre Robin sequence: the Vancouver classification. *Past Surg (Oakv)* 2017; 25: 14-20.
6. Vatlach S, Maas C, Poets CF. Birth prevalence and initial treatment of Robin sequence in Germany: a prospective epidemiologic study. *Orphanet J Rare Dis* 2014; 9: 9.
7. Ratan ZA, Zaman SB, Mehta V, Haidere MF, Runa NJ, Akter N. Application of fluorescence in situ hybridization (FISH) technique for the detection of genetic aberration in medical science. *Cureus* 2017; 9: e1325.
8. Cohen SM, Greathouse ST, Rabbani CC, et al. Robin sequence: what the multidisciplinary approach can do. *J Multidiscip Healthc* 2017; 10: 121-32.
9. Paladini D. Fetal micrognathia: almost always an ominous finding. *Untrasound Obstet Gynecol* 2010; 35: 377-84.
10. Xu JX, Kilpatrick N, Baker NL, Penington A, Farlie PG, Tan TY. Clinical and molecular characteristics of children with Pierre Robin sequence. *Mol Syndromol* 2016; 7: 322-8.
11. Yang Y, Yuan J, Yao X, et al. BMPR1B mutation causes Pierre Robin sequence. *Oncotarget* 2017; 8: 25864-71.
12. Muller-Hagedorn S, Buchenau W, Arand J, Bacher M, Poets CF. Treatment of infants with syndromic Robin sequence with modified palatal plates: a minimally invasive treatment option. *Head Face Med* 2017; 13: 4.
13. Paes EC, de Vries IAC, Penris WM, et al. Growth and prevalence of feeding difficulties in children with Robin sequence: a retrospective cohort study. *Clin Oral Investig* 2017; 21: 2063-76.
14. Bartzela TN, Carels C, Maltha JC. Update of 13 syndromes affecting craniofacial and dental structures. *Front Physio* 2017; 8: 1038.
15. Lopez-Munoz E, Becerra-Solano LE. An update on amniotic bands sequence. *Arch Argent Pediatr* 2018; 116: e409-e420.
16. Koukouvitaki M, Arkaoumanis PT, Brucknerova J, Brucknerova I. Clinical attitude to the patient with non-syndromic Pierre Robin Sequence with the cleft of soft palate and uvula - The necessity of fibroscopic investigation. *Neuro Endocrinol Lett* 2019; 40: 5-9.
17. Butow K, Morkel JA, Naidoo S, Zwahlen RA. Pierre Robin sequence: subdivision, data, theories, and treatment - Part 1: syndromic and nonsyndromic Pierre Robin sequence. *Ann Maxillofac Surg* 2016; 6: 35-7.

Thyrotoxic Hypokalemic Periodic Paralysis Triggered by Dexamethasone Administration

Waraporn Polamaung¹, Jaruwan Kongkit^{2,3}, Parichat Yimnoi³, Patchaya Boonchaya-Anant^{3,4}, Thiti Snabboon^{3,4,*}

ABSTRACT

Thyrotoxic hypokalemic periodic paralysis (THPP) is a disease characterized by recurrent episodes of muscle weakness due to intracellular potassium shifting in the presence of high levels of thyroid hormone. It occurs more commonly amongst young Asian men with underlying Graves' disease. Attacks are commonly precipitated by ingestion of carbohydrate-rich meals or alcohols, stress or strenuous exercise. Herein, we describe an adult Thai man suffering from a hypokalemic periodic paralysis attack after receiving a dexamethasone injection. The diagnosis of Graves' disease was confirmed by his thyroid function test and a presence of thyrotropin-receptor antibody. His weakness and hypokalemia responded well to potassium supplement and a non-selective beta blocker, while his thyrotoxicosis was initially controlled by an anti-thyroid medication and subsequently with a subtotal thyroidectomy. Clinicians should beware of this manifestation when administering steroids in the thyrotoxic patients, especially of Asian male descent.

KEYWORDS

thyrotoxic periodic paralysis; hypokalemia; steroid-induced; dexamethasone administration

AUTHOR AFFILIATIONS

¹ Department of Medicine, Prapokklo Hospital, Chanthaburi Province, Thailand

² Department of Medicine, Vachira Phuket Hospital, Phuket Province, Thailand

³ Department of Medicine, Faculty of Medicine, Chulalongkorn University, Bangkok, Thailand

⁴ Excellence Center in Diabetes, Hormone and Metabolism, King Chulalongkorn Memorial Hospital, Thai Red Cross Society, Bangkok, Thailand

* Corresponding author: Excellence Center in Diabetes, Hormone and Metabolism, Bhumisirimangalanusorn Bldg., 4C Fl., King Chulalongkorn Memorial Hospital, Thai Red Cross Society, Rama IV Road, Patumwan, Bangkok 10330, Thailand; e-mail: thiti.s@chula.ac.th

Received: 31 December 2019

Accepted: 26 May 2020

Published online: 10 August 2020

Acta Medica (Hradec Králové) 2020; 63(2): 91–93

<https://doi.org/10.14712/18059694.2020.24>

© 2020 The Authors. This is an open-access article distributed under the terms of the Creative Commons Attribution License (<http://creativecommons.org/licenses/by/4.0>), which permits unrestricted use, distribution, and reproduction in any medium, provided the original author and source are credited.

INTRODUCTION

Thyrotoxic hypokalemic periodic paralysis (THPP) is characterized by recurrent episodes of muscle weakness and hypokalemia from intracellular potassium shifting (1, 2). This neurological manifestation is indistinguishable from other subtypes of hypokalemic periodic paralysis except for the presence of thyrotoxicosis state (3). Episodes of attacks can be precipitated by an ingestion of high carbohydrate meal or alcohol, stress or strenuous exercise (1, 3). Herein, we describe a patient with THPP attack after receiving a steroid injection and a review of literature.

CASE REPORT

A 36-year-old Thai man complained of acute weakness in both the lower extremities. Five hours prior, his general practitioner has prescribed him a 5 mg of dexamethasone injection to control his pain from right elbow tendinitis. Thereafter, he developed myalgia which has progressed to paralysis predominantly in both of his legs. He was noted about 4 kg weight loss and palpitations during the past 6 months. He denied history of alcohol use or a family history of weakness. On examination, the patient was alert with a normal blood pressure and a pulse rate of 115 beats/min. His thyroid gland was slightly enlarged without audible bruit. No exophthalmos was noted. Neurological examination revealed flaccid paralysis and decreased deep tendon reflexes in both the lower extremities. His weakness of 3/5 motor power also involved in proximal part of the upper extremities. Sensory function and cranial nerves were spared. Laboratory results revealed hypokalemia (2.0 mEq/L, 3.5–4.5), hypophosphatemia (2.0 mg/dL, 2.5–4.5), and mildly elevated serum creatine kinase (300 U/L, 24–195). An electrocardiogram showed sinus tachycardia, a prolonged QTc interval of 0.5 sec and the presence of U wave. His muscle strength and serum potassium were fully restored within 12 hours after the administration of 100 mEq of oral liquid potassium. Rebounded hyperkalemia, 5.8 mEq/L, was noted. Graves' disease was confirmed with FT₄ 1.97 ng/dL (0.8–1.8), TSH < 0.005 μ U/mL (0.3–4.1), and a positive for thyrotropin-receptor antibody. Methimazole (15 mg/d) and propranolol (40 mg/d) were administered. One month later, subtotal thyroidectomy was performed uneventfully, and the patient was in euthyroid state and did not experience paralysis during the follow-up period.

DISCUSSION

Glucocorticoids are currently used in various conditions of Graves' disease including ophthalmopathy due to its anti-inflammatory action; and also in thyroid storm due to its blocking on thyroid hormone peripheral conversion (4). In this report, we demonstrated an unusual complication of glucocorticoid usage in precipitating hypokalemic paralytic attack in a patient with thyrotoxicosis.

Most affected THPP patients are young Asian men (male-to-female ratio of 20–70 : 1) with underlying Graves'

disease despite the female preponderance in hyperthyroidism (male-to-female ratio 1 : 4–10) (1–3). THPP is also described in any etiology of thyrotoxicosis. The overall incidence of THPP in Asian thyrotoxic patients is about 2% comparing with 0.1–0.2% in North America (3). The weakness is characterized by transient and recurrent episodic attacks. It mainly involves the proximal parts of upper and lower extremities and rarely affects bulbar muscles, bowel, bladder or cranial nerves. The severity of weakness usually correlates with the degree of hypokalemia. Sensation is typically intact while deep tendon reflexes are markedly decreased or absent (1, 2). The frequency of the attacks can be variable, and the duration of each episode can take from hours to several days. THPP occurs only in the presence of thyrotoxicosis state and sometimes it can be the first manifestation of thyroid disorders as described in our patient. Prodromal symptoms such as cramps or stiffness of the affected muscles are also noted. The attack frequently occurs during the night or in the early morning, and during the resting time. Myalgia has been reported in some cases, in which rhabdomyolysis may occur. Other electrolyte abnormalities that have also been described are hypophosphatemia and hypomagnesemia (5).

The exact mechanism of THPP is still elusive. Hypokalemia from an intracellular shifting is related to an increase in sodium-potassium adenosine triphosphatase (Na⁺/K⁺-ATPase) pump activity in the skeletal muscle from a direct stimulation by thyroid hormone, catecholamines, androgens and insulin. This could explain the mechanism of those precipitating factors that can provoke the paralysis attacks from thyrotoxicosis, sympathetic overactivity, hyperandrogenism and hyperinsulinism. In addition, genetic predisposition involving the mutation of transmembrane ion channels of skeletal muscle, including *KCNJ18*, *CACNA1S* and *SCN4A* has been shown in some affected patients (6). Glucocorticoids may induce hypokalemia by directly increasing the Na⁺/K⁺-ATPase pool in skeletal muscle and also by causing hyperinsulinemia. Moreover, steroids can also trigger muscle weakness by inducing myopathy and renal potassium loss owing to its mineralocorticoid effects. From the literature reviews, about 10 cases have been reported regarding the steroids as a precipitating factor of THPP, ranging from low dose prednisolone to pulse methylprednisolone (7, 8).

The definitive treatment of THPP is to achieve the euthyroid state. For patients with Graves' disease, an initial treatment with antithyroid drugs followed by radioactive iodine (RAI) therapy or total thyroidectomy is suggested (1–3). According to 2016 ATA guideline, THPP is classified as the clinical situation that favors RAI therapy (4). Nevertheless, our patient chose subtotal thyroidectomy as his preferred treatment. Hypokalemia is usually self-recovery and patients should be monitored for rebound hyperkalemia. Potassium administration during the attacks should be in oral form dividing into small doses with the maximal daily dose of 90 mEq (2). This replacement may shorten the weakness period and prevent the possible fatal arrhythmia; however, it cannot prevent recurrent paralytic attacks. A nonselective β -blocker, propranolol, is considered to be a first-line agent in the treatment and preventing the paralytic attacks.

CONCLUSION

We reported an unusual case of THPP precipitated by the use of a high-dose steroid. Clinicians should beware of the attacks when administering steroids in the thyrotoxic patients, especially of Asian male descent.

ACKNOWLEDGEMENTS

Some parts of this study have been presented at 41st Annual Meeting of the European Thyroid Association, Newcastle upon Tyne, UK, September 15–18, 2018 as an Abstract-ID: P1-02-14, Steroid-induced Thyrotoxic Periodic Paralysis, A Case report.

REFERENCES

1. Kung AW. Clinical review: Thyrotoxic periodic paralysis: a diagnostic challenge. *J Clin Endocrinol Metab* 2006; 91: 2490–5.
2. Vijayakumar A, Ashwath G, Thimmappa D. Thyrotoxic periodic paralysis: clinical challenges. *J Thyroid Res* 2014; 2014: 649502.
3. Maciel RM, Lindsey SC, Dias da Silva MR. Novel etiopathophysiological aspects of thyrotoxic periodic paralysis. *Nat Rev Endocrinol* 2011; 7: 657–67.
4. Ross DS, Burch HB, Cooper DS, et al. 2016 American Thyroid Association Guidelines for Diagnosis and Management of Hyperthyroidism and Other Causes of Thyrotoxicosis. *Thyroid* 2016; 26: 1343–421.
5. Chang CC, Cheng CJ, Sung CC, et al. A 10-year analysis of thyrotoxic periodic paralysis in 135 patients: focus on symptomatology and precipitants. *Eur J Endocrinol* 2013; 169: 529–36.
6. Rasheed E, Seheult J, Gibney J, Boran G. Does thyrotoxic periodic paralysis have a genetic predisposition? A case report. *Ann Clin Biochem* 2018; 55: 713–6.
7. Ahamed R, McCalley S, Sule AA. Steroids and Thyrotoxicosis Precipitate Periodic Paralysis. *Cureus* 2018; 10: e2106.
8. Wongraoprasert S, Buranasupkajorn P, Sridama V, Snaboon T. Thyrotoxic periodic paralysis induced by pulse methylprednisolone. *Intern Med* 2007; 46: 1431–3.

