

# Dual Fungal Infections (Aspergillosis and Mucormycosis) in a Diabetic Mellitus Patient Leading to Maxillary Sinusitis as a Post-COVID Manifestation: First Case Report

Manveen Kaur Jawanda<sup>1</sup>, Ravi Narula<sup>2</sup>, Sonia Gupta<sup>3</sup>, Vineet Sharma<sup>4</sup>, Priya Gupta<sup>5</sup>, Manpreet Kaur<sup>5</sup>

## ABSTRACT

Coronavirus infectious disease-19 caused by Severe acute respiratory distress syndrome-coronavirus-2 has emerged to be an emergency global health crisis for more than a year. And, as the disease has spread, a number of new clinical features have been observed in these patients. Immunosuppression caused by this disease results in an exacerbation of pre-existing infections. While corticosteroids are considered a life-saving therapeutic intervention for this pandemic, they have proved to be a double-edged sword and their indiscriminate use has produced some deleterious results. Recently, in the backdrop of this expression, a notable rise in invasive fungal infections has been identified even in the post-remission phase. Mucormycosis, Aspergillosis, and Candidiasis are the three most common opportunistic fungal infections among those observed. COVID-19 patients with diabetes mellitus are already at a higher risk of developing such secondary infections due to impaired immunity. Here we present a rare case report of a 50-year old male diabetic mellitus patient diagnosed with dual fungal infections (Aspergillosis along with Mucormycosis) leading to maxillary sinusitis as a post-COVID manifestation. To our knowledge, this is the first such case reported till date.

## KEYWORDS

aspergillosis; COVID-19; diabetes; Maxillary Sinus; mucormycosis

## AUTHOR AFFILIATIONS

<sup>1</sup> Department of Oral Pathology & Microbiology and Forensic Odontology, Laxmi bai institute of dental sciences and hospital, Patiala, Punjab, India

<sup>2</sup> Department of Oral and Maxillofacial surgery, Guru Nanak Dev Dental College and Research Institute, Sunam, Punjab, India

<sup>3</sup> Department of Oral Pathology and Microbiology & Forensic Odontology, Rayat and Bahra dental college and hospital, Mohali, Punjab, India

<sup>4</sup> Department of Conservative Dentistry, Laxmi bai institute of dental sciences and hospital, Patiala, Punjab, India

<sup>5</sup> Department of Oral and Maxillofacial Pathology & Microbiology, Laxmi Bai Institute of Dental Sciences and Hospital, Patiala, Punjab, India

\* Corresponding author: Department of Oral Pathology and Microbiology & Forensic Odontology, Rayat and Bahra dental college and hospital, Mohali, Punjab, India; e-mail: Sonia.4840@gmail.com

Received: 31 August 2021

Accepted: 1 December 2021

Published online: 4 March 2022

Acta Medica (Hradec Králové) 2021; 64(4): 227–231

<https://doi.org/10.14712/18059694.2022.7>

© 2021 The Authors. This is an open-access article distributed under the terms of the Creative Commons Attribution License (<http://creativecommons.org/licenses/by/4.0>), which permits unrestricted use, distribution, and reproduction in any medium, provided the original author and source are credited.

## INTRODUCTION

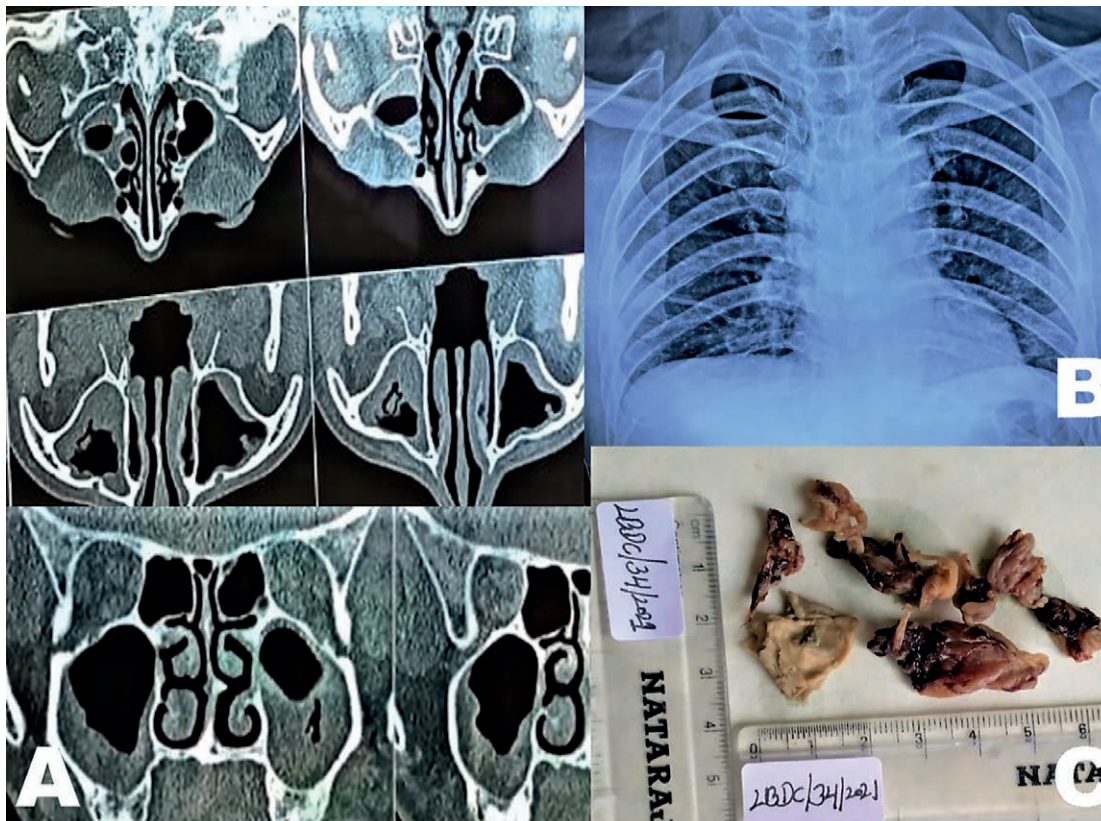
For more than a year, Coronavirus infectious disease-19 (COVID-19) caused by Severe Acute Respiratory Distress Syndrome (SARS-CoV2) has emerged as an emergency global health crisis. And, as the disease has spread, a number of new clinical features have been observed in these patients (1). Recently, in the backdrop of this expression, a notable rise in invasive fungal infections has been identified either during the disease or in the post-remission phase (2-4). Mucormycosis, Aspergillosis and Candidiasis are the three topmost opportunistic fungal infections noticed among those. COVID-19 patients with diabetes mellitus (DM) are already at a higher risk of developing such secondary infections due to impaired immunity (5). Here we present a rare case report of 50-year old male DM patient with dual fungal infections (Aspergillosis with Mucormycosis) leading to maxillary sinusitis as post-COVID manifestation. To our knowledge, this is the first such case reported til date.

## CASE REPORT

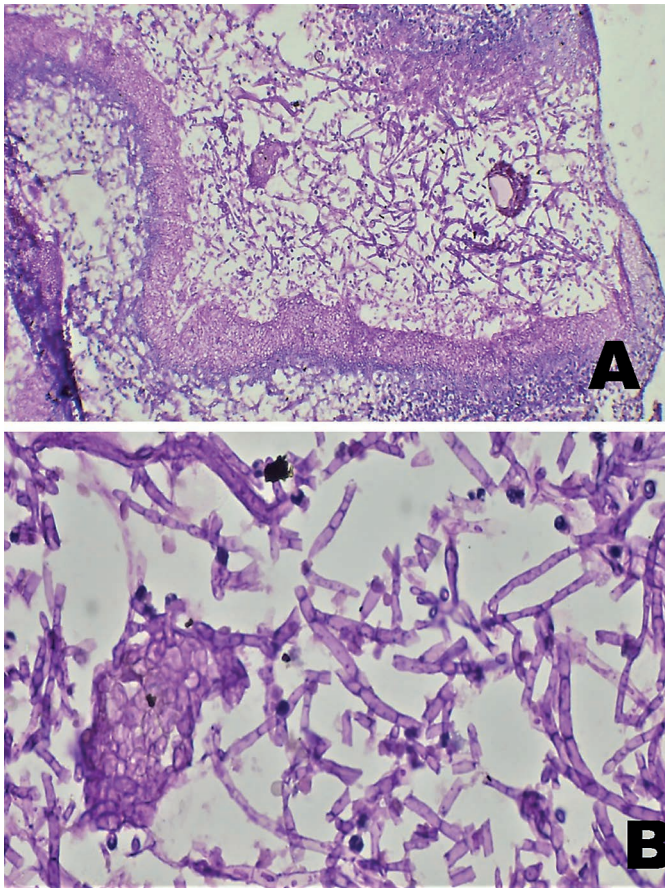
A 50-year-old male patient presented with a chief complaint of slow-growing swelling and continuous pain on the left side of his face since 1 month ago. He was a known case of long-standing DM (more than 10 years) and was on oral anti-hyperglycaemic drugs. He gave a history of fever and COVID-19 infection one and a half months back. He mentioned a drug history of Prednisolone, Remdesivir,

and Tocilizumab administration during his treatment for COVID infection in the hospital. He reported a complaint of continuous pain and gradually increasing swelling on the left side of his face. On inspection, extra oral examination revealed a gross facial asymmetry due to swelling on the left side of the mid-face region; it was about 3.0 cm × 2.0 cm in size. On palpation, the swelling was firm and non-tender.

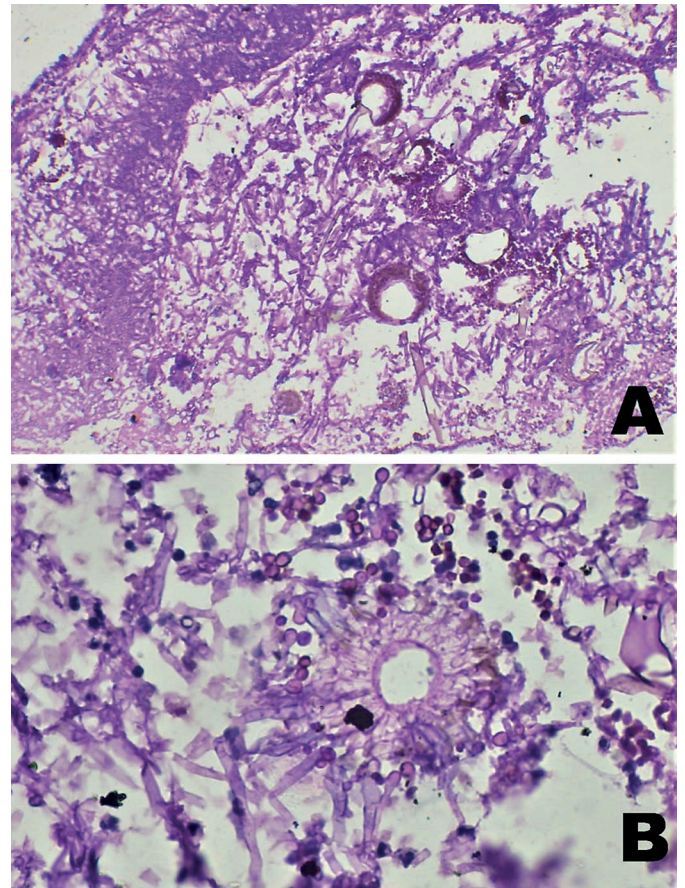
The computerised tomography (CT) scan of paranasal sinus (PNS) revealed a soft tissue density mass in the left maxillary sinus extending into osteomeatal complex resulting in complete blockage with bone erosion of the anterolateral wall, suggestive of fungal infection or malignancy (Figure 1A). A soft tissue density thickening was also noted along the walls of right maxillary sinus. X-ray chest revealed left sided perihilar opacity along with non-homogenous infiltrates in all zones of both lung fields, suggestive of transient pulmonary infiltrates (Figure 1B). With this suspicion, a cadwell-luc procedure was performed under local anaesthesia to incise the mass (Figure 1C) in the left maxillary sinus and sent for histopathological examination. The microscopic examination revealed a pseudostratified ciliated columnar epithelium with intact basement membrane all over and underlying connective tissue was fibro cellular with chronic inflammatory cell infiltrate. Special staining with periodic acid Schiff (PAS) stain showed acute and chronic inflammatory infiltrate along with branched septate hyphae at acute angles (Figure 2A, 2B) which are characteristics of aspergillosis. Apart from hyphal forms, many fruiting bodies and spores of fungus were also seen (Figure 3A). The



**Fig. 1** A) CT scan of paranasal sinus showing soft tissue density mass in maxillary sinus; B) Chest radiograph showing perihilar opacity along with non-homogenous infiltrates in all zones of both lung fields; C) Photograph of gross incisional biopsy mass.



**Fig. 2** A) Photomicrograph showing magenta pink coloured septate broad fungal hyphae of an *Aspergillus* species (PAS stain, 100×); B) (PAS, 400×).



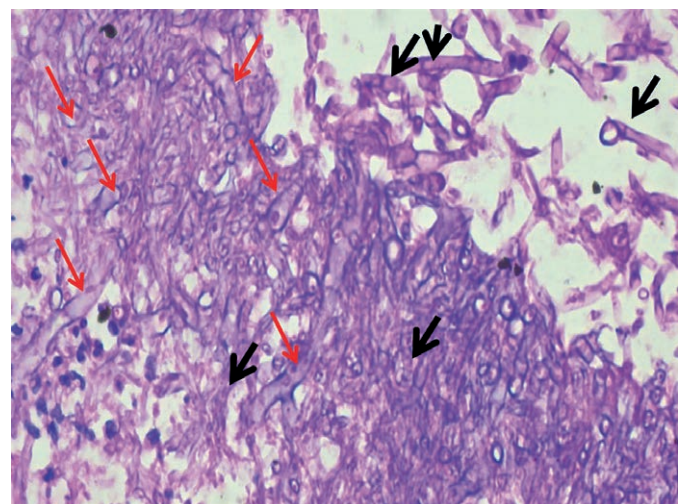
**Fig. 3** A) Photomicrograph showing septate branching fungal hyphae along with numerous conidiophores and conidia (PAS stain, 100×); B) The conidial head is composed of a vesicle, which is crowned by one layer of phialides (PAS stain, 400×).

conidial head (fruiting bodies) was composed of a vesicle, which was crowned by one layer of phialides (sterigmata) (Figure 3B), ending in chains of conidia at the extremity. PAS staining also showed few broad aseptate hyphae with branching at 90° resembling mucor (Figure 4), intermingling with numerous narrow septate hyphae. After reviewing clinical, radiographic, and histopathological findings, diagnosis of Maxillary sinusitis secondary to dual fungal infection (predominantly *Aspergillus* along with *Mucormycosis*) was made. Sequestrectomy was done for the dead left maxillary dentoalveolar region along with curettage for left maxillary antrum and the tissue was sent for histopathological examination that further confirmed the histopathological diagnosis previously made on incisional biopsy tissue.

Postoperatively, the patient was asked to keep his sugar under control, and intravenous voriconazole was started the day before surgery and continued for 10 days (two doses of 6 mg/kg on day 1, followed by 4 mg/kg twice daily, followed by 200 mg orally twice daily). He was also prescribed Posaconazole (400mg BD × 4 months). After 4 months of follow-up, the patient appeared to be in remission and a CT scan showed no radiological evidence of disease, so any further treatment was interrupted. To this date, the patient is asymptomatic and shows no clinical or radiographic evidence of recurrent disease.

**DISCUSSION**

Researchers have reported marked immunosuppression resulting from COVID-19 that may give origin to vivid secondary infections either during the disease or even after



**Fig. 4** Photomicrograph showing numerous broad aseptate (Red arrow) *Mucor*-like hyphae intertwined with narrow septate *Aspergillus* hyphae (black arrow) (PAS stain, 400×).

the recovery phase (6). Studies on SARS-CoV and SARS-CoV-2 have shown that both viruses belong to the same species and have similar biological and clinical characteristics (7). It has been observed in previous studies that fungal infections were very frequent in SARS patients as a leading cause of death in 25–73.7% of cases (8). These results indicate an alarming sign for clinicians to pay attention to the probability of fungal infections accompanying COVID-19 disease. Recently, a rapid rise in the number of fungal infections has been documented in COVID-19 patients. Mucormycosis, Aspergillosis, and Candidiasis are the most commonly encountered fungal infections in patients admitted to hospitals, in the intensive care units (ICU), and as post-COVID sequelae (2–4).

Mucormycosis is a rare but lethal fungal infection caused by fungi (*Mucor*, *Rhizopus*, *Lichtheimia*, *Cunninghamella*) belonging to the mucoromycetes family. The fungus is non-pathogenic to immunocompetent individuals. However, in immunocompromised patients, it results in invasive infection (9). The main route of infection is through spore inhalation that results in germination of spores in the nasal cavity and spreads to the PNS, further invading the palate, orbits, and brain, often leading to death. The fungus exhibits a remarkable affinity for arteries, forming thrombi within the blood vessels, resulting in a reduction of blood supply and leading to tissue necrosis (10). In DM patients, the inhibition of binding of iron to transferrin results in elevated iron levels, promoting the growth of mucor hyphae (11). Mucormycosis is classified into six subtypes: rhinocerebrovascular, pulmonary, gastrointestinal, central nervous system (CNS), and disseminated. Symptoms include headache, fever, lethargy, painful eyes, nasal or sinus congestion, ophthalmoplegia, meningoencephalitis, proptosis, facial swelling, partial loss of vision, coughing, shortening of breath, and altered mental status. In the oral cavity, the infection is manifested as necrotizing ulceration of the palate, blackish slough formation and exposure of bone, tenderness over the maxillary sinus area, tooth loss, etc. (12). Imaging aids and histopathology are used to diagnose mucormycosis. Histologically, mucormycosis is characterised by pathognomonic broad, non-septate hyphae with the branching at right angles. Both medication and surgical management strategies are employed in mucormycosis. Amphotericin B (liposomal) is the most commonly used drug. Combined therapy of amphotericin B and Posaconazole has shown synergistic effects against fungal hyphae formation (13).

Aspergillosis is the second most common oral opportunistic fungal infection caused by *Aspergillus fumigatus*, followed by *Aspergillus flavus*, *Aspergillus niger*, and *Aspergillus terreus* (14). The main routes of infection are through invasion of vascular tissues, leading to thrombosis and infarction. Clinically, this infection represents three subtypes: non-invasive, invasive, and destructive non-invasive. The invasive type is characterised by the invasion of the fungus into tissues, causing slow-progressing and destructive lesions or highly aggressive and lethal lesions. Non-invasive forms evolve as aspergilloma, fungal balls, mycetoma, and allergic sinusitis. Destructive non-invasive types are characterised by local tissue destruction without

deep invasion. The destruction caused is due to the toxic and lytic products released by the fungal pathogen, such as phospholipases, proteases, aflatoxin, gliotoxin, and haemolysin and phthioic acid (14). The infection is more common in immunocompromised individuals, such as those with DM, haematological malignancies, bone marrow transplantation, etc. (15). The fungus is mainly an airborne pathogen, invading lungs and bronchopulmonary tissues. It also affects the PNS, larynx, eyes, ears, or oral cavity. Oral aspergillosis is caused by an invasion of the soft tissue lining of the maxillary sinus, which spreads to the oral mucosa and progresses to the underlying bone and palate, resulting in black or yellow necrotic tissue discoloration. Diagnosis of the fungus is made by microbiological culture and histopathological examination. Histologically, the fungus shows septate hyphae branched at an acute angle, 3 to 4 microns in size, invading adjacent small blood vessels. Occlusion of the vessels often results in necrosis (16). On Sabouraud's dextrose agar culture medium, the fungus shows fluffy granular blue-green colonies. The fungal organism exhibits centrifugal linear growth, developing into ball-shaped masses. The centre of the mass contains calcium phosphate, which appears as a foreign body on radiographic examination. Management of invasive aspergillosis of the sinus includes both surgical and medicinal therapy. Systemic administration of amphotericin B, voriconazole, itraconazole, and caspofungin is recommended. Local debridement with amphotericin B is employed as an adjunct treatment modality following surgical treatment (17).

In the present case, clinical and radiological features led to a provisional diagnosis of some fungal infection or any malignancy. To confirm the diagnosis, a histological examination was performed that showed features of fungal infection, predominantly aspergillosis, along with a few hyphae of mucor. A final diagnosis of maxillary sinusitis secondary to dual fungal infection (predominantly *Aspergillus* along with Mucormycosis) was made. Several cases of pulmonary and rhino-orbital aspergillosis have been reported in COVID-19 patients with DM. But maxillary sinus aspergillosis has been very rarely noticed. The presence of dual infection in a single DM patient as a post-COVID manifestation makes this case unique and intriguing. To our knowledge, this is the first such case reported till date. In 2021, Moorthy et al. in a retrospective study observed that out of 18 COVID-19 patients, only one case showed evidence of mixed fungal infections, i.e., aspergillosis and mucormycosis, but the patient was non-diabetic (4). In 2021, EI-Kohley et al. in a longitudinal prospective study, depicted the presence of such dual infection in 3 out of 36 COVID-19 patients, but all were non-DM (18).

Several factors have been contemplated for the increasing surge of COVID-linked fungal infections in India as compared to other regions of the world. And the same can be hypothesised for the present case also (19).

1. Prolonged use of steroids: Steroids are being implemented as the main line of drug therapy during this pandemic, and it is suggested that they tend to prevent end organ damage by reducing the inflammatory cytokine storm. But, the indiscriminate use of these

anabolic steroids has been shown to cause immunosuppression and a rise in blood sugar levels, providing a medium for the growth of more microbes causing infections.

2. SARS-CoV2 has the potential to damage blood vessels and airway tissues, leading to more infections.
3. It has been observed that during the peak of the second wave, there was an acute shortage of medical grade oxygen. Hence, most hospitals had to shift to industrial oxygen. There is a strong possibility of the use of a contaminated accessory during the inhalation of oxygen by patients.
4. The humidifiers used, i.e., distilled water versus sterile water or even tap water, were also alleged to be a source.
5. There is a high level of iron, in the form of ferritin, among COVID-19 patients, which is favourable for the growth of fungal pathogens.
6. In India, zinc was prescribed as a preventive or therapeutic agent, which is also conducive to fungal growth.
7. Prolonged use of contaminated masks and gloves without changing them leads to infections.

It is well understood that DM patients are more prone to infections. High blood sugar levels act as milieu for microbial growth, dysregulating the glycaemic homeostasis (20). According to recent data, India stands second amongst the top 10 countries in the world, with 77 million people with diabetes and another 36.5 million with prediabetes, which is a high-risk condition for diabetes and cardiovascular disease (4). Diabetic patients are at higher risk of developing COVID-19 disease. Conversely, COVID-19 infection can worsen diabetes control and some treatments used for COVID (e.g., steroids) can exacerbate hyperglycaemia.

In the present case, the patient had a history of DM, COVID-19 infection, and hospitalisation along with widespread use of steroids, monoclonal antibodies, and broad spectrum antibiotics as a part of the armamentarium against COVID-19. All of these factors might have created the perfect storm in which secondary infections took roots and thrived.

## CONCLUSION

The rapid rise of fungal infections in the maxillofacial region reported in COVID-19 patients even after recovery signifies an important clinical finding. Multiple factors have been suggested for the co-existence of fungal infections in COVID-19 patients. The present case report of a DM patient with dual infections (Aspergillosis along with mucormycosis) as a post-COVID manifestation adds another important evidence of the increasing number of such cases during this lethal pandemic. Early diagnosis and treatment planning of such lesions are necessary to prevent further complications in both DM and COVID patients.

## ABBREVIATIONS

CNS: Central nervous system; COV: Coronavirus; COVID: Coronavirus infectious disease; CT: Computerized tomography; DM: Diabetic mellitus; PAS: Periodic acid shiff; PNS: Paranasal sinus; SARS: Severe acute respiratory syndrome.

## REFERENCES

1. Amorim Dos Santos J, Normando AGC, et al. Oral Manifestations in Patients with COVID-19: A Living Systematic Review. *J Dent Res* 2021; 100(2): 141-54.
2. Pathak K, Karadwal A, Nayak P, Nayak S. Mucormycosis in Post Covid Patient - A Case Report. *Indian J Forens Med Toxicol* 2021; 15(3): 240-4.
3. Prestel C, Anderson E, Forsberg K, et al. Candida auris outbreak in a COVID-19 specialty care unit - Florida, July-August 2020. *Morbidity and Mortality Weekly Report*. 2021; 70(2): 56-7.
4. Moorthy A, Gaikwad R, Krishna S, et al. SARS-CoV-2, uncontrolled diabetes and corticosteroids-An unholy trinity in invasive fungal infections of the maxillofacial region? A Retrospective, Multi-centric Analysis. *J Maxillofac Oral Surg* 2021; 20(3): 1-8.
5. Wolff D, Nee S, Hickey NS, Marscholke M. Risk factors for Covid-19 severity and fatality: a structured literature review. *Infection* 202; 49(1): 15-28.
6. Xu Z, Shi L, Wang Y, et al. Pathological findings of COVID-19 associated with acute respiratory distress syndrome. *Lancet Respir Med* 2020; 8(4): 420-2.
7. Peeri NC, Shrestha N, Rahman MS, et al. The SARS, MERS and novel coronavirus (COVID-19) epidemics, the newest and biggest global health threats: what lessons have we learned? *Int J Epidemiol* 2020; 49(3): 717-26.
8. Li CS, Pan SF. Analysis and causation discussion of 185 severe acute respiratory syndrome dead cases. *Zhongguo Wei Zhong Bing Ji Jiu Yi Xue* 2003; 15(10): 582-4. In Chinese.
9. Mehta S, Pandey A. Rhino-orbital mucormycosis associated with COVID-19. *Cureus* 2020; 12: e10726.
10. Jagtap SV, Jagtap SS, Nagar V, Varshney K. Invasive mucormycosis in post COVID-19 infection: Case report with review. *IP Arch Cytol Histopathology Res* 2021; 6(2): 135-9.
11. Hingad N, Kumar G, Deshmukh R. Oral mucormycosis causing necrotizing lesion in a diabetic patient: a case report. *Int J Oral Maxillofac Pathol* 2012; 3(3): 8-12.
12. Muzyka BC, Epifanio RN. Update on oral fungal infections. *Dental clinics of North America* 2013; 57(4): 561-81.
13. Rajendra Santosh AB, Muddana K, Bakki SR. Fungal infections of oral cavity: Diagnosis, management, and association with COVID-19. *SN Compr Clin Med* 2021 Mar 27: 1-12.
14. Deepa A, Nair BJ, Sivakumar T, Joseph AP. Uncommon opportunistic fungal infections of oral cavity: a review. *J Oral Maxillofac Pathol* 2014; 18(2): 235-43.
15. Vučićević Boras V, Jurlina M, Brailo V, Đurić Vuković K, et al. Oral mucormycosis and aspergillosis in the patient with acute leukemia. *Acta Stomatologica Croatica* 2019; 53(3): 274-7.
16. Bathoorn E, Escobar Salazar N, Sepehrkhoy S, Meijer M, de Cock H, Haas PJ. Involvement of the opportunistic pathogen *Aspergillus tubingensis* in osteomyelitis of the maxillary bone: a case report. *BMC Infect Dis* 2013; 13: 59.
17. Jenks JD, Hoenigl M. Treatment of Aspergillosis. *J Fungi (Basel)* 2018; 4(3): 98.
18. El Kohley NA, El-Fattah AMA, Khafagy YK. Invasive Fungal Sinusitis in Post COVID-19 Patients: A New Clinical Entity. *Laryngoscope* 2021; 00: 1-7.
19. Baruah C, Devi P, Deka B, Sharma DK. Mucormycosis and Aspergillosis have been linked to Covid-19-related fungal infections in India. *Adv Case Stud* 2021; 3(1): AICS.000555.
20. Unnikrishnan R, Misra A. Infections and diabetes: risks and mitigation with reference to India. *Diab Metabol Syndr Clin Res Rev* 2020; 14: 1889-94.