

# Rapidly Progressive Interstitial Lung Disease Associated with Melanoma Differentiation-Associated Gene 5 Antibody

Yosuke Maezawa<sup>1</sup>, Mami Narita<sup>1</sup>, Riho Tanimura<sup>1</sup>, Sou Hattori<sup>1</sup>, Hiroaki Satoh<sup>2,\*</sup>

## ABSTRACT

Anti-melanoma differentiation-associated gene-5 (MDA-5) antibody is an autoantibody found in patients with dermatomyositis. These antibody-positive patients are clinically characterized by complications of rapidly progressive interstitial pneumonia resistant to treatment and with poor prognosis. We describe herein a patient with MDA-5 antibody-positive interstitial lung disease, which progressed rapidly to death after a period of slow progress. Recently, attention has been paid to the similarities in clinical courses and CT images between MDA-5 antibody-positive interstitial lung disease and coronavirus disease 2019 (COVID-19)-associated pneumonia. Patients with MDA-5 antibody do not always have diffuse and evenly distributed bilateral opacities at the time of first presentation. This patient had significant laterality of such opacities. It should be considered that MDA-5 antibody-positive patients with such laterality in opacities might progress rapidly. Chest physicians, dermatologists, and dermatologists need to be aware of the characteristics of the disease for optimal treatment choices.

## KEYWORDS

interstitial lung disease; anti-melanoma differentiation-associated gene-5 antibody; smoking; prognosis

## AUTHOR AFFILIATIONS

<sup>1</sup> Division of General Medicine, University of Tsukuba, Mito Medical Center-Mito Kyodo General Hospital, Mito, Ibaraki, Japan

<sup>2</sup> Division of Respiratory Medicine, University of Tsukuba, Mito Medical Center-Mito Kyodo General Hospital, Mito, Ibaraki, Japan

\* Corresponding author: Division of Respiratory Medicine, Mito Medical Center, University of Tsukuba-Mito Kyodo General Hospital, Miya-machi 3-2-7, Mito-city, Ibaraki, 310-0015, Japan; e-mail: hirosato@md.tsukuba.ac.jp

Received: 21 June 2021

Accepted: 26 April 2022

Published online: 29 June 2022

Acta Medica (Hradec Králové) 2022; 65(1): 37–40

<https://doi.org/10.14712/18059694.2022.15>

© 2022 The Authors. This is an open-access article distributed under the terms of the Creative Commons Attribution License (<http://creativecommons.org/licenses/by/4.0>), which permits unrestricted use, distribution, and reproduction in any medium, provided the original author and source are credited.

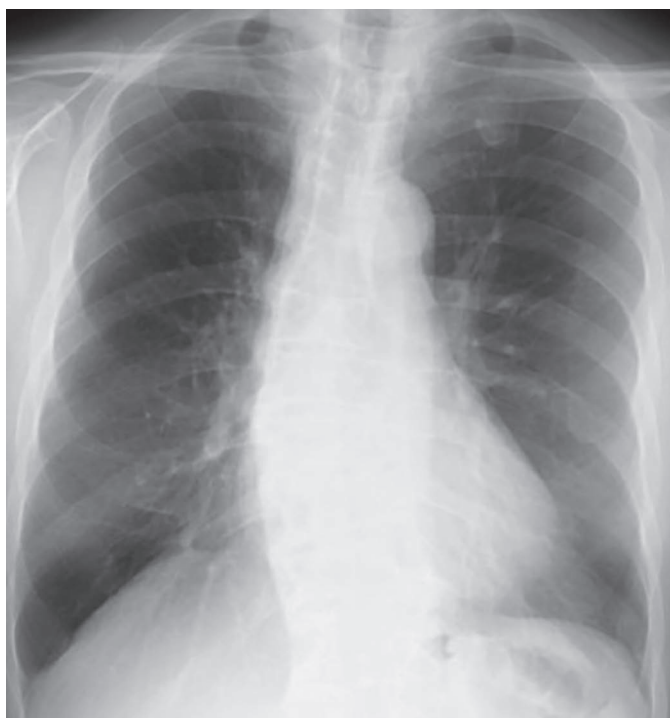## INTRODUCTION

Anti-melanoma differentiation-associated gene-5 (MDA-5) antibody is an autoantibody found in patients with dermatomyositis, especially those with typical skin findings but no myositis (1). These antibody-positive patients are clinically characterized by complications of rapidly progressive interstitial lung disease (ILD) resistant to treatment and with poor prognosis (1). MDA-5 is a protein molecule belonging to the retinoic acid-inducible gene-I (RIG-I) family. RIG-I family proteins contribute to protection from viral infection (2). Therefore, MDA-5 is involved not only in the development of dermatomyositis but also plays an important role in antiviral immunity (2). Recently, attention has been paid to the similarities in clinical courses (3, 4) as well as in CT images (5–10) between MDA-5 antibody-positive ILD and coronavirus disease 2019 (COVID-19)-associated pneumonia. Bilateral subpleural ground glass-like opacities (GGOs) spreading in the lower lobe were the most common findings (5–10).

We describe herein a patient with MDA-5 antibody-positive ILD, which progressed rapidly to death. The patient had unilateral non-diffuse opacities at the time of the first visit, and worsened rapidly to die shortly thereafter.

## CASE REPORT

A 77-year-old man presented after having experienced two weeks of general fatigue and dyspnea. The patient reported having had spinal stenosis five years prior and was followed up by orthopedic outpatient clinic in our hospital. A chest radiograph ten months before this consult showed

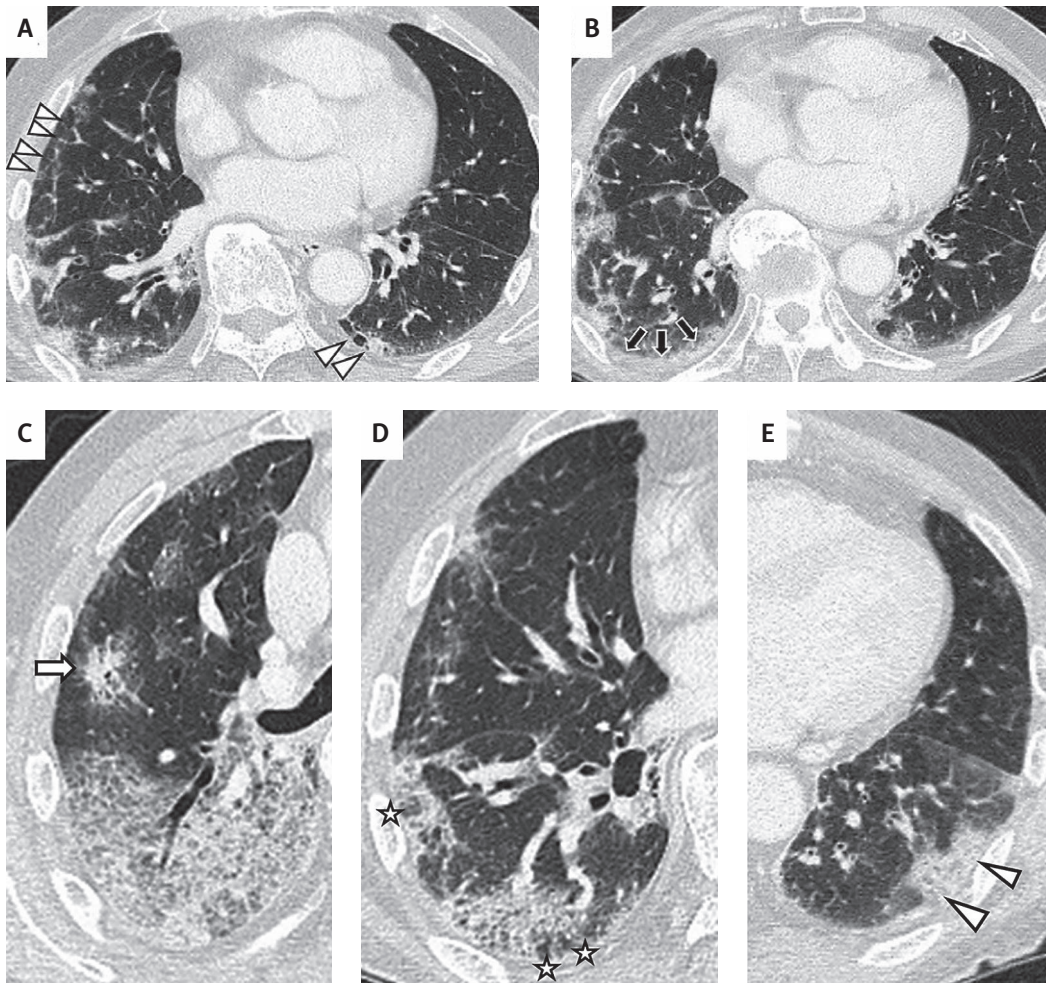


**Fig. 1** A chest radiograph 10 months before the patient's presentation showed no reticular opacities in the left lower lung field.

no reticular opacities in the left lower lung field (Figure 1). He was a 15 pack-year past ex-smoker. On admission, he was alert. His vital signs were: blood pressure of 122/64 mmHg, pulse rate of 69/min, and body temperature of 38.0 °C. Percutaneous arterial blood oxygen saturation was 98% in room air. Pharyngeal redness and hoarseness were observed. Fine crackles at the lung base were not observed. Superficial lymph node swelling was not observed, neither were Gottron signs, swelling, heliotrope rash, purpura, arthritis, or other physical findings suggestive of dermatomyositis. Muscle weakness was also not apparent. On admission, his white blood cell count was 5600/ $\mu$ L, and C-reactive protein was 6.12 mg/dL. Creatine kinase was 154 IU/L, lactic dehydrogenase was 446 U/L, and ferritin was 2469.3 ng/mL;  $\beta$ -D glucan was below 5.0pg/mL. Chest computed tomography (CT) scan revealed peripheral GGOs and consolidation, consistent with MDA-5 antibody-positive ILD (7, 8) (Figure 2, Table 1). These changes were more pronounced in the right lung than in the left lung (Figure 2). Considering his respiratory condition, reverse transcription-polymerase chain reaction (RT-PCR) for COVID-19 was performed, but the result was negative. The patient was initially diagnosed with community-acquired pneumonia, and was subsequently started on antibiotic treatment with tazobactam/piperacillin, but his symptoms of dyspnea and weakness did not improve. On admission, the patient tested negative for autoantibodies against anti-aminoacyl tRNA synthetase (ARS), cyclic citrullinated peptide antibody (CCP), antinuclear antibody (ANA), as well as anti-neutrophil cytoplasmic autoantibodies against proteinase 3 (PR3-ANCA), and myeloperoxidase (MPO-ANCA). MDA5 antibody had a high titer index >150 (normal range, 0–32). The patient's condition worsened nine days after admission and 10 L/min oxygen was required. A chest CT scan revealed exacerbation of the ground-glass opacities in the right lower lung, but not evenly on both sides (Figure 3). The patient was transported to the ICU and placed on respiratory support because of worsening oxygenation. The high level of ferritin, rapidly progressive respiratory failure, and findings on chest CT suggested the possibility of rapidly progressive ILD. Methylprednisolone (1000 mg/day, drip infusion) was administered for acute respiratory failure for three days and was continued at a reduced dose (500 mg/day) without improvement. Therefore, cyclophosphamide (500 mg, drip infusion) and tacrolimus (4 mg once daily for ten days) were added to the steroid regimen. The patient's condition did not improve, and he died of respiratory failure on day 10 after admission.

## DISCUSSION

Two previous studies have described the characteristics of CT images of MDA-5 antibody-positive ILD (7, 8). A study by Tanizawa et al. pointed out the importance of the following three findings: lower peripheral or peribronchovascular consolidations or GGO, lower peripheral or peribronchovascular reticulation, and random peripheral GGO (7). Another study by Chino et al. described the importance of perilobular opacities, which thickened and consolidated



**Fig. 2** A chest CT scan taken at the time of diagnosis revealed rapidly progressive interstitial lung disease associated with melanoma differentiation-associated gene 5 antibody: peripheral intralobular septal thickening (arrow heads) (A) and non-septal linear or plate-like opacities (stars) (B). Peripheral and peribronchovascular consolidation (arrow) (C), peribulbar opacities (stars) (D), and subpleural nonsegmental ground-glass opacities (E) were observed in the CT scan.

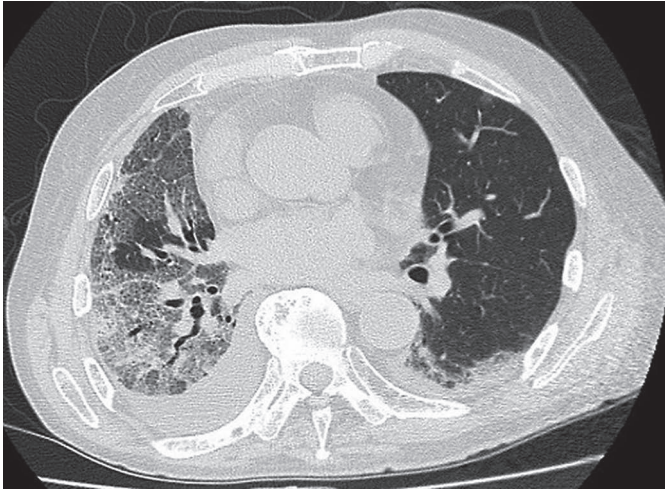
rapidly, which lead to significant reduction of lung volume (8). As shown in Table 1, the characteristics reported by both papers were found in our patient’s chest CT taken at the time of initial diagnosis. In addition to these features of CT images of anti-MDA-5 antibody-positive ILD, the following two findings should be noted. The first was that in the early stages of the disease, opacities did not appear

evenly and diffusely on both sides (11–13). This patient had significant laterality of such opacities. Second, the shadow exacerbations of some patients are slow in the early stages of the disease and then rapidly exacerbate within days (12–14). Increasing evidence highlights the striking similarities between lung injury in patients with anti-MDA-5 antibody and in those with COVID-19 pneumonia (15).

**Tab. 1** Comparison of CT findings by Tanizawa et al., Chino et al., and the authors of the case report.

CT findings	Features	Researchers who pointed out the findings	Presence or absence of findings in this patient
Lower consolidation/GGO pattern	lower peripheral or peribronchovascular nonsegmental consolidations or GGO	Takizawa et al. (Reference Number 7)	Present (Figure 2-B and C)
Lower reticulation pattern	lower peripheral or peribronchovascular reticulation	Takizawa et al. (Reference Number 7)	Present (Figure A and D)
Random GGO pattern	random peripheral GGO	Takizawa et al. (Reference Number 7)	Present (Figure C and E)
Perilobular opacities	perilobular opacities in the lower lobes	Chino et al. (Reference Number 8)	Present (Figure D)

GGO: ground-glass opacity



**Fig. 3** A chest CT scan taken on day 9 revealed exacerbation of the ground-glass opacities in both lower lungs.

Both lung disorders can become severe and can lead to death (15). Autoantibodies against MDA5 in patients with ILD target an intracellular sensor of viral RNA (including coronavirus) that triggers the innate immune response (16). Some studies have pointed out similarities in clinical courses of these two respiratory conditions (3, 4), supported by common pathophysiological mechanisms. However, there has been no evidence that patients with COVID-19 had anti-MDA-5-antibodies. Our patient had a negative PCR for COVID-19, but the patient gradually worsened within nine days, and then rapidly deteriorated and died 14 days later. During this time, he developed a cytokine storm, similar to the course of exacerbation of COVID-19 pneumonia.

It is noteworthy that the features of anti-MDA-5-associated, rapidly progressive ILD on CT images are similar to those in patients with COVID-19 pneumonia. With regard to the 'consolidation/GGO' observed on CT scans, Zarei et al. described that consolidation and/or GGO were observed in 61% of patients, and more frequently in hospitalized patients. About another CT feature, the GGO pattern (9), Yang et al reported that GGO in patients with COVID-19 had various forms of distribution, such as peripheral, bilateral, and involved pulmonary lobes > 2 (17). Regarding 'perilobular opacities', Parry and colleagues reported that these opacities were seen late (>2 weeks) in the course of COVID-19 (10). Therefore, when such features are observed on CT images, it is necessary to consider COVID-19 infection as a differential diagnosis. Particular attention should be paid to patients who are highly positive for MDA-5 antibody.

The most characteristic feature of this patient was the prominent laterality of the opacities at the time of initial presentation. It should be considered that MDA-5 antibody-positive patients with such laterality in opacities might progress rapidly. Accumulation of information about patient background and imaging features is especially important in the treatment of rare diseases such as MDA-5 antibody-positive ILD. Chest physicians, as well as rheumatologists and dermatologists should be aware of the characteristics for optimal treatment choices.

## CONFLICT OF INTEREST STATEMENT

The authors declared no conflicts of interest with respect to the authorship and/or publication of this article.

## FUNDING

The authors received no financial support for the research and/or authorship of this article.

## ETHICS

Written comprehensive consent was obtained from patient. Reporting of this case report was approved by the Hospital Ethics Committee.

## REFERENCES

- McPherson M, Economidou S, Liampas A, Zis P, Parperis K. Management of MDA-5 antibody positive clinically amyopathic dermatomyositis associated interstitial lung disease: A systematic review. *Semin Arthritis Rheum* 2022; 53: 151959.
- Yoneyama M, Kikuchi M, Matsumoto K, et al. Shared and unique functions of the DExD/H-box helicases RIG-I, MDA5, and LGP2 in antiviral innate immunity. *J Immunol* 2005; 175: 2851–8.
- Qian J, Xu H. COVID-19 Disease and Dermatomyositis: A Mini-Review. *Front Immunol* 2022; 12: 747116.
- Wang G, Wang Q, Wang Y, et al. Presence of anti-MDA5 antibody and its value for the clinical assessment in patients with COVID-19: A retrospective cohort study. *Front Immunol* 2021; 12: 791348.
- Kitamura M, Sugimoto H. Clinically amyopathic dermatomyositis during the COVID-19 pandemic. *Oxf Med Case Reports* 2021 Aug; 2021(8): omab061.
- Giannini M, Ohana M, Nespola B, Zanframundo G, Geny B, Meyer A. Similarities between COVID-19 and anti-MDA5 syndrome: what can we learn for better care? *Eur Respir J* 2020; 56: 2001618.
- Tanizawa K, Honda T, Nakashima R, et al. HRCT features of ILD in dermatomyositis with anti-CADM-140 antibody. *Respir Med* 2011; 105: 1380–7.
- Chino H, Sekine A, Baba T, et al. Radiological and pathological correlation in anti-MDA5 antibody-positive interstitial lung disease: rapidly progressive perilobular opacities and diffuse alveolar damage. *Intern Med* 2016; 55: 2241–6.
- Zarei F, Moezi P, Jahromi MG, Zeinali-Rafsanjani B. Comparison of chest CT findings in outpatient and hospitalized COVID-19 RT-PCR positive patients of Shiraz. *J Med Imaging Radiat Sci* 2022; 53: 107–12.
- Parry AH, Wani HA, Choh NA, Shah NN, Jehangir M. Spectrum of chest CT manifestations of coronavirus disease (COVID-19): A pictorial essay. *Indian J Radiol Imaging* 2021; 31 (Suppl 1): S170–S7.
- Watanabe T, Takizawa N, Nagasaka T, et al. Fatal and extensive multiorgan hemorrhages in anti-melanoma differentiation-associated gene 5 antibody-positive dermatomyositis: An autopsy case report. *Medicine (Baltimore)* 2020; 99: e18600.
- Kaenmuang P, Navasakulpong A. Clinical characteristics of anti-MDA5 antibody-positive interstitial lung disease. *Respirol Case Rep* 2020; 9: e00701.
- Kagawa H, Tsujino K, Yamamoto Y, et al. Acute lung injury after plasma exchange in a patient with anti-MDA5 antibody-positive, rapidly progressive, interstitial lung disease: A case report. *Respir Med Case Rep* 2020; 29: 101016.
- Aoyama J, Hayashi H, Yajima C, et al. Anti-MDA5 antibody-positive rapidly progressive interstitial pneumonia without cutaneous manifestations. *Respir Med Case Rep* 2019; 26: 193–6.
- Mehta P, McAuley DF, Brown M, et al. COVID-19: consider cytokine storm syndromes and immunosuppression. *The Lancet* 2020; 395: 1033–4.
- Dias Junior AG, Sampaio NG, Rehwinkel J. A balancing act: MDA5 in antiviral immunity and autoinflammation. *Trends Microbiol* 2019; 27: 75–85.
- Yang H, Lan Y, Yao X, Lin S, Xie B. The chest CT features of coronavirus disease 2019 (COVID-19) in China: a meta-analysis of 19 retrospective studies. *Virol J* 2020; 17: 159.