

COVID-19 Can Unveil Brugada: A Rare Case

Savalan Babapoor^{1,*}, Zachary Port², Philip C. Wiener³,
Roohbeh Tarighati Rasekhi⁴, Ali Babapour Farrokhran⁵, Sumeet K. Mainigi²

ABSTRACT

Brugada syndrome (BRS) is a channelopathy with three characteristic electrocardiogram patterns and an increased risk of sudden cardiac death (SCD), in the absence of gross structural heart disease. Fever is shown to precipitate ventricular arrhythmias in patients with BRS. Here, we report a rare case of Brugada pattern in a patient with Coronavirus Disease 2019 (COVID-19) without fever. A baseline ECG should be considered for patients with COVID-19, even in the absence of fever. COVID-19 by itself may be a factor that can induce Brugada pattern ECGs.

KEYWORDS

Brugada Syndrome; Corona Virus Disease-19; ST-Elevation myocardial injury

AUTHOR AFFILIATIONS

¹ Leon H. Charney Division of Cardiology, Cardiac Electrophysiology, NYU Langone Health, New York University School of Medicine, NY, USA

² Department of Medicine, Division of Cardiology, Einstein Medical Center, Philadelphia, PA, USA

³ Department of Internal Medicine, Division of Cardiology, Washington University in St. Louis, St. Louis, MO, USA

⁴ Department of Neurology, SUNY Upstate, Syracuse, NY, 13210, USA

⁵ Urmia University of Medical Sciences, Urmia, Iran

* Corresponding author: Leon H. Charney Division of Cardiology, Cardiac Electrophysiology, NYU Langone Health, New York University School of Medicine, NY, USA; Savalan.BabapourFarrokhran@NYULANGONE.org

Received: 12 May 2023

Accepted: 22 May 2023

Published online: 8 November 2023

Acta Medica (Hradec Králové) 2023; 66(2): 68–71

<https://doi.org/10.14712/18059694.2023.18>

© 2023 The Authors. This is an open-access article distributed under the terms of the Creative Commons Attribution License (<http://creativecommons.org/licenses/by/4.0>), which permits unrestricted use, distribution, and reproduction in any medium, provided the original author and source are credited.

INTRODUCTION

First described in 1992, Brugada syndrome (BRS) is an inherited arrhythmia disorder which leads to an increased risk of sudden cardiac death in a structurally normal heart (1).

Nearly half of Brugada cases are caused by loss of function mutations in the genes encoding the cardiac sodium channel, SCN5A and SCN10A (2). Patients with BRS are often otherwise healthy and unaware of their genetic predisposition. As a result, the diagnosis of BRS is often made after a syncopal episode or an aborted sudden cardiac arrest (3). In the case where a patient is found to have the characteristic electrocardiographic changes without any prior history of sudden cardiac death, ventricular arrhythmias, or syncopal episodes, the patient is diagnosed with the “Brugada pattern” rather than the syndrome phenotype.

A febrile state, electrolyte abnormalities such as hyper/hypokalemia, substance use such as alcohol or cocaine, and sodium channel blocking medications are some of the provocative triggers that may unmask the ECG manifestation and induce an arrhythmia in patients with BRS (4). Arrhythmias and conduction system abnormalities are one of the major complications of COVID-19 (5). Here, we report a rare case of type 2 Brugada pattern in a patient with Coronavirus Disease 2019 (COVID-19) without fever.

CASE REPORT

A male patient in his 40s with a history significant for diabetes and hypertension, presented to the emergency department (ED) reporting a one-week history of fever, chills, and headache. In the ED, his nasal swab sample tested positive for COVID-19 by reverse transcriptase polymerase chain reaction (RT-PCR). He was discharged home due to stable vital signs and clinical condition with no new medications.

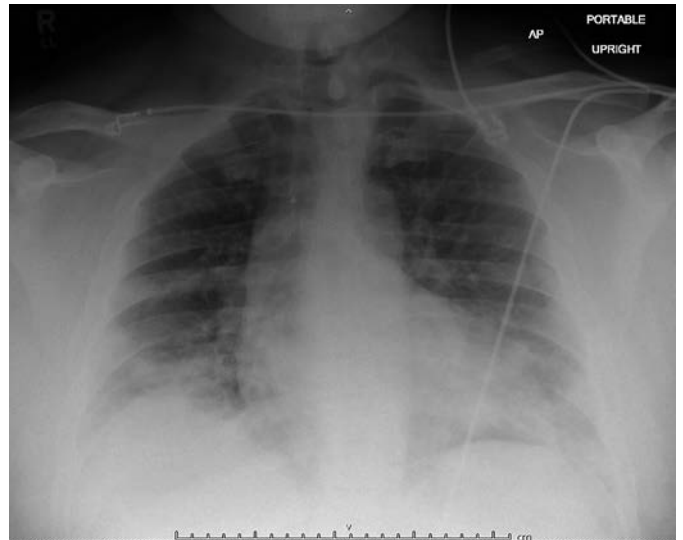

Fig. 2 Chest X-Ray

Two days following discharge, he reported dyspnea on exertion, shortness of breath, with worsening headache and myalgias and underwent re-evaluation in the ED. On presentation the patient was afebrile (36.9 °C), had a pulse of 84 bpm, respiratory rate of 19, and an oxygen saturation of 92% on room air. He was placed on 2 liters of supplemental oxygen and his oxygen saturation improved to 98%. In discussion with the patient, he denied recent or remote syncope or a family history for sudden cardiac death (SCD).

An electrocardiogram (ECG) was obtained that showed ST elevation in lead V1 and V2 (Figure 1). There were no prior ECGs for comparison. Chest x-ray demonstrated diffuse interstitial and patchy ground-glass opacities throughout both lungs consistent with COVID pneumonia (Figure 2). He had a normal echocardiogram with normal ejection fraction and no significant structural or valvular abnormalities. There was no pericardial effusion.

The patient re-tested for COVID-19 with nasal swab RT-PCR at this second evaluation and remained positive. Computed tomography (CT) scan of the chest with and

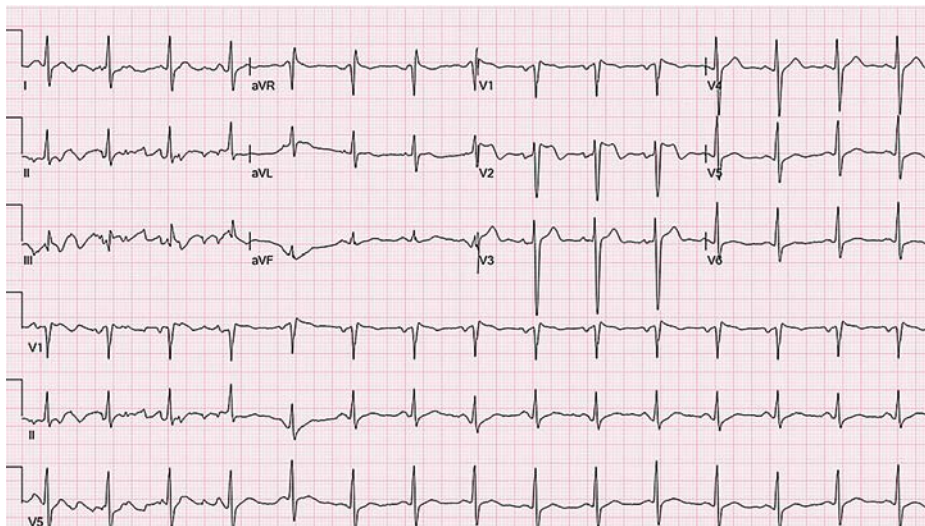


Fig. 1 ECG: Presentation electrocardiogram (ECG) for our patient demonstrating sinus rhythm with incomplete right bundle branch block pattern and ST elevation in precordial leads > 2 mm with “saddle back” conformation indicative of the type 2 Brugada pattern.

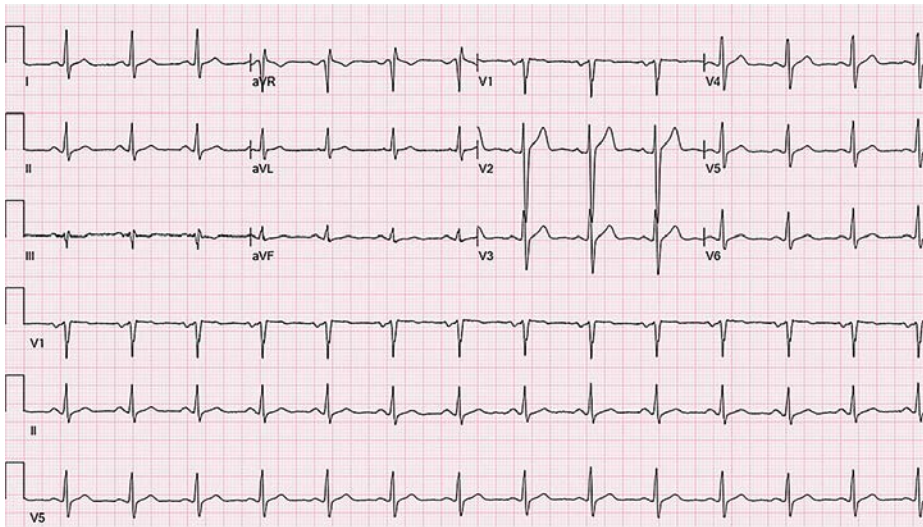


Fig. 3 ECG Prior to discharge: Electrocardiogram prior to discharge demonstrating sinus rhythm with resolution of precordial ST elevation and Brugada pattern.

without contrast showed no evidence of pulmonary emboli and confirmed multi-lobe pneumonia. His admission laboratory tests were within normal limits except for an elevated creatinine of 1.22 mg/dl, ferritin of 1305 ng/ml (normal range of 22–275 ng/ml) and lactate dehydrogenase of 470 IU/L (normal range of 125–220 IU/L).

Based on an initial concern for an ST elevation myocardial infarction (STEMI), he received aspirin 325mg, sublingual nitroglycerine, and one dose of dexamethasone. CT coronary angiogram showed clear coronaries. Troponin I (high sensitivity troponin) levels were trended three times with all 3 resulting <0.03 ng/mL. The patient was treated with steroids and remdesivir. On day 2 of admission, the ST elevation resolved and returned to normal baseline (Figure 3). His renal function also returned to normal with a creatinine of 0.86 mg/dl. The patient remained afebrile on admission, throughout hospitalization, and during each ECG evaluation. No arrhythmia was noted on telemetry monitoring during his hospital stay.

The patient's home medications were unchanged prior to or during admission. These medications included glimepiride, irbesartan, dexamethasone, and atorvastatin.

On post discharge follow up appointments, patient had ECG pattern similar to the ECG prior to discharge with no evidence of Brugada pattern

DISCUSSION

BRS is a channelopathy with three characteristic electrocardiogram patterns and an increased risk of SCD, in the absence of gross structural heart disease (6). Type 2 pattern is characterized by ST-segment elevation of ≥ 2 mm with a saddleback morphology in ≥ 1 right precordial leads (Figure 1). Fever is shown to precipitate ventricular arrhythmias in patients with BRS. One study showed that more than half of their participating patients experienced syncope or cardiac arrest in the setting of a fever (7). It is known that COVID-19 results in multiple cardiac rhythm abnormalities and conduction system disorders

via multiple mechanisms including direct damage to the myocytes and conduction system via inflammation and altered electrolyte channel function.

Fever is the most common clinical presentation in patients testing positive for COVID-19. However, in our case the patient was afebrile when the ECGs were obtained making fever induced Brugada pattern less likely. In addition to that he was not taking any antipyretics that would mask fever. Medications, another possible etiology for unmasking Brugada, did not appear to be a culprit as the home medications for our patient remained unchanged prior to and during admission. Dexamethasone and remdesivir have not been reported to provoke Brugada. The potential mechanism for why COVID caused Brugada pattern in this case can be explained by myocardial inflammation, interstitial edema leading to electrophysiological and structural remodeling, altered intercellular coupling, and action potential abnormalities.

Although type 2 Brugada pattern may be seen spontaneously and the ECG phenotype can be variable from day to day, in this case, ECG pattern disappearance with symptom resolution and absence of Brugada pattern on follow up ECGs post hospital discharge favors COVID-19 to be a potential trigger for revealing Brugada pattern.

All in all, based on the history and above findings, the likelihood of this patient having inherited arrhythmia is not excluded and it is likely that COVID-19 unmasked the Brugada pattern regardless of having inherited arrhythmia.

CONCLUSION

Multiple cases of different electrophysiological complications of COVID-19 have been reported and the number is still growing (5, 8). Brugada pattern and ventricular arrhythmias more commonly occur in patients with fever. In this report we describe a patient with Brugada pattern ECG in the setting of COVID-19 infection without fever. A baseline ECG should be considered for patients with

COVID-19, even in the absence of fever. As demonstrated by this case, Brugada pattern ECG can be seen in COVID-19 patients even in the absence of fever. COVID-19 can be considered as a provocative trigger for Brugada pattern ECG. Cardiac monitoring may be particularly important in patients with suspected or history of BRS.

LIMITATIONS

The patient did not undergo cardiac MRI to better assess cardiac structure and rule out microstructural abnormalities. No drug provocation test with sodium channel blockers, and genetic testing were done.

DECLARATIONS

Funding

This research did not receive any specific grant from funding agencies in the public, commercial, or not-for-profit sectors.

Competing interests

The authors declare no competing interests.

Ethics approval

Research conducted according to ethical guidelines.

REFERENCES

1. Brugada P, Brugada J. Right bundle branch block, persistent ST segment elevation and sudden cardiac death: a distinct clinical and electrocardiographic syndrome. A multicenter report. *J Am Coll Cardiol* 1992; 20(6): 1391–6.
2. Hu D, Barajas-Martínez H, Pfeiffer R, et al. Mutations in SCN10A Responsible for a Large Fraction of Brugada Syndrome Cases. *J Am Coll Cardiol* 2014; 64(1): 66.
3. Priori SG, Napolitano C, Gasparini M, et al. Natural history of Brugada syndrome: insights for risk stratification and management. *Circulation* 2002; 105(11): 1342–7.
4. Antzelevitch C, Brugada P, Borggrefe M, et al. Brugada Syndrome: Report of the second consensus conference. *Circulation* 2005; 111(5): 659–70.
5. Babapoor-Farrokhran S, Rasekhi RT, Gill D, Babapoor S, Amanullah A. Arrhythmia in COVID-19. *SN Compr Clin Med* 2020; 2(9): 1430–5.
6. Sieira J, Brugada P. The definition of the Brugada syndrome. *Eur Heart J* 2017; 38(40): 3029–34.
7. Amin AS, Meregalli PG, Bardai A, Wilde AAM, Tan HL. Fever increases the risk for cardiac arrest in the Brugada syndrome. *Ann Intern Med* 2008; 149(3): 216–8.
8. Babapoor-Farrokhran S, Port Z, Wiener PC, Amanullah A, Mainigi SK. Polymorphic Ventricular Tachycardia with a Normal QTc Interval in a Patient with COVID-19 and Fever: Case Report. *SN Compr Clin Med* 2020; 2(11): 2387–90.