

COMPARISON THE HISTOPATHOLOGICAL FINDINGS AFTER CERVICAL BIOPSY AND EXCISIONAL PROCEDURES

Aljosa Mandic, Slavica Knezevic-Usaj, Dejan Nincic, Jelka Rajovic, Marina Popovic, Tatjana Ivkovic Kapicl

Oncology Institute of Vojvodina, Sremska Kamenica, Serbia

Summary: Introduction: A definitive diagnosis of cervical intraepithelial neoplasia (CIN) is confirmed after histopathological (HP) examination of the tissue obtained through the biopsy. The aim of this study was to compare histopathological results obtained with punch biopsy and results obtained through one of the excisional techniques. Material and methods: We analysed histology results of 130 patients referred to our institution with abnormal smear. Punch biopsy was performed after colposcopic examination in all patients before one of the excision methods. Excision methods performed were: large loop excision of transformation zone (LLETZ), radio-frequency knife conisation or cold knife conisation. Based on the histopathological examination of the punch biopsy specimen or excisional specimen diagnosis of CIN was established. Results: CIN and invasive cancer were the most common diagnoses in the 31–40 age group at 45.4% (59/130). Discrepancies in the histological diagnosis between punch biopsy and excisional biopsy was identified in 58.5% (76/130) of the patients. In 6% of the cases the biopsy did not detect an invasive carcinoma. Conclusion: The most frequent discrepancies between punch biopsy and excisional biopsy were in the group of patients with a higher grade cervical dysplasia. Mild dysplastic changes diagnosed through punch biopsy, require a more conservative approach, as the majority of this group had negative specimens on the cone after excision, especially in the younger population. It is advisable that the patients above 30 years of age and a higher grade dysplasia in the biopsy specimen, should undergo one of the excisional techniques as a diagnostic/therapeutic method of treatment.

Key words: *Dysplasia; Biopsy; Excisional techniques*

Introduction

Each year, 274,000 women die of cervical cancer in the world (1, 2). Cervical intraepithelial neoplasias (CIN) are precancerous changes in the squamous epithelium which can precede the development of cervical cancer. Richart (3) introduced a concept of Cervical Intraepithelial Neoplasia (CIN), which are histologically classified as follows:

- low grade cervical intraepithelial neoplasias (CIN 1),
- medium grade cervical intraepithelial neoplasias (CIN 2),
- high grade cervical intraepithelial neoplasias (CIN 3).

CIN 1 changes are usually diagnosed in younger women, with a high incidence of spontaneous clinical regression (60–70%), while about 10% may progress to CIN 2 or 3. CIN 2 may also spontaneously regress, but there may be a risk of progression to a higher grade dysplasia or carcinoma (22% CIN 2 changes may advance to CIN 3). CIN 3 may persist or progress to a carcinoma in approximately 12% (3–5).

The Bethesda cytological classification (6) divides abnormalities into:

- low-grade squamous intraepithelial lesions: HPV/CIN 1;
- high-grade squamous intraepithelial lesions: CIN 2 and CIN 3.

Diagnosis of cervical intraepithelial changes are usually established by combination of cervical cytology, colposcopy,

biopsy and endocervical curettage. This approach enables an adequate therapeutic approach depending on the size, distribution and grade of the lesion (7,8).

Precancerous cervical lesions are treated with operative techniques divided into two groups. The first group comprises destructive ablative techniques (cryotherapy or cold coagulation and laser ablation) which cause destruction of the superficial layer where change is located. The second group encompasses excisional techniques: cold-knife conisation, radio-frequency knife or laser conisation and large loop excision of transformation zone (LLETZ) (8–12).

Aim

The aim of this study was to compare and analyse histopathological results obtained by punch biopsy and excisional techniques.

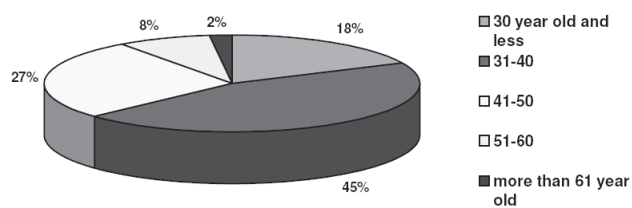
Materials and methods

The study reports results of histology specimens from 130 patients who were referred to the Oncology Institute of Vojvodina in Sremska Kamenica based on initial abnormal smear or suspicious looking cervix. Some of the patients had the biopsy performed offsite at a different institution.

The biopsy material taken from the transformation zone and ectocervix was fixed in the 10% formaldehyde and sent for histopathological analysis at the Pathology and Cyto-Diagnostics Department of our Institute. The excisional techniques used in the study were: a classical cold-knife conisation, large loop excision of the transformation zone (LLETZ) or radio-frequency knife conisation. Radio-frequency conisation and cervical loop excision were done with a high-frequency radio-surgical apparatus, dr Oppel ST 501 according to usage instructions. The obtained material was histopathologically examined in the Department of Pathology and Cyto-Diagnostics of the Institute. All biopsy material (punch biopsy and excisional biopsy) were examined and the grade of the pre-cancerous lesion was determined in each specimen. Grading of these changes was performed using the WHO/ISGYP classification (World Health Organisation and International Society of Gynaecological Pathologists Classification). The statistical processing was done with the SPSS 16 computer programme. The statistical processing of the obtained results was performed according to basic descriptive statistical methods: statistical mean, standard deviation and median of numeric values. The estimation of the existence of the level of statistical importance of the difference between parametric data was tested by the Paired Samples Test. All data are presented both in tables and graphically.

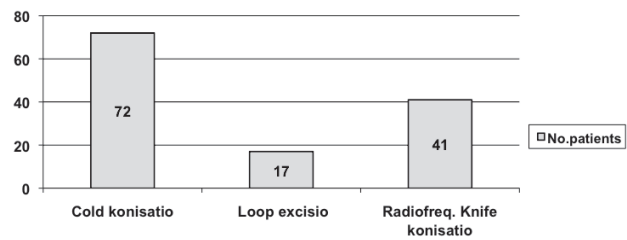
Results

In the study we analysed biopsy material from 130 patients whose average age was 38.42 years (SD = 8.925), range 21–63. Most of the patients were in the 31–40 year age group 45.4% (59/130), followed by 41–50 years of age group 27% (35/130). Eighteen percent (24/130) were younger than 30 years of age, and the group 51–60 years of age was 8% (10/130). Two patients were older than 61 years (Graph 1) After confirmation of the existence of pre-cancerous lesions by punch biopsy, one of the excisional techniques was performed on each patient. Large loop exci-



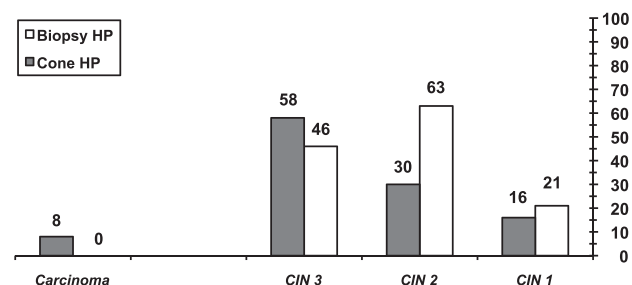
Graph 1: Distribution of patients according to age groups

sion of transformation zone (LLETZ) was used in 13.1% (17/130) of the cases, radio-frequency knife conisation was performed in 31.5% (41/130) of the cases, and the classical cold-knife conisation in 55.4% (72/130) of the cases (Graph 2).



Graph 2: Applied excisional techniques

The histopathological analysis of the punch biopsy material taken from the cervix showed the following lesions: CIN 1 16.2% (21/130), CIN 2 in 48.5% (63/130), CIN 3 in 35.4% (46/130). When material from the excisional procedures in the same patients was analysed, the following distribution of CIN changes was reported: CIN 1 was found in 12.3% (16/130), CIN 2 in 23.1% (30/130), CIN 3 in 44.62% (58/130) of the patients and an invasive cervical carcinoma in 6.2% (8/130) of the cases (Graph 3). In 13.65% (18/130) patients, the specimen obtained did not show the presence of any dysplasia or cancerous lesions. In the punch biopsy group most of the precancerous and cancerous changes were diagnosed in the 31–40 year age group, 59 of them in total, followed by 35 patients in the 41–50 year age group and the least changes were found in the group of over 60 years of age. About 3/4 of the diagnosed changes were in the 31–50 year age group (Tab. 1).



Graph 3: Precancerous and cancerous lesions verified through the histopathological analysis of the biopsy and excisional techniques

By comparing the two histopathological analyses, punch biopsy and excisional methods, the higher grade dysplasia in the cervix was found in specimens obtained by excisional techniques.

The invasive carcinoma was diagnosed in the specimens obtained by excisional methods in those patients where the punch biopsy specimen showed CIN 3 lesions. In patients with verified CIN 1 obtained by punch biopsy, 50% cases were confirmed in the specimen obtained by excisional

Tab. 1: Distribution of changes confirmed by the histopathological examination of cones in different age groups

	Under 30	31–40	41–50	51–60	Over 60	TOTAL
CIN1	5	7	3	1	0	16
CIN2	5	15	8	2	0	30
CIN3	11	14	18	4	1	58
Ca	1	3	3	1	0	8
Without changes	2	10	3	2	1	18
TOTAL	24	59	35	10	2	130

technique. Among these patients with CIN 1 diagnosed by punch biopsy, 43% (9/21), was without any pathological changes in the specimen obtained by excision (Tab. 2). There was complete congruence among both histological specimens in 56.2% (73/130) cases. Discrepancies in the diagnostic findings in the punch biopsy and the specimens obtained by excisional procedures were evident in 43.8% (57/130) patients. By the application of the Paired Simple t-Test it was established that there is a statistically significant difference between the histopathological diagnosis obtained by biopsy examination and the diagnosis established through histopathological examination of specimens obtained by excisions ($t = 7.921$, $df = 130$, $p = 0.000$).

Tab. 2: Ratio between the grade of cervical dysplastic lesions in the biopsy material and in the corresponding specimens obtained by excision

biopsy \ cone	CIN1	CIN2	CIN3	Ca	No changes	Total
CIN1	10	6	0	0	0	16
CIN2	2	27	1	0	0	30
CIN3	0	22	36	0	0	58
Ca	0	0	8	0	0	8
No changes	9	8	1	0	0	18
Total	21	63	45	0	0	130

The highest level of discrepancy in pathological findings between punch biopsy and excisional procedures was observed in the group of patients with CIN 2 lesions. In cases of CIN 2 in the specimens obtained by punch biopsies the CIN 3 was confirmed in 35% (22/63), CIN 1 in 10% (6/63) and without any pathological findings in 13% (8/63) after excisional procedures of the cervix. In 42% (27/63) the CIN 2 was obtained in both specimens.

In CIN 3 lesions obtained by punch biopsy, there were discrepancies in 22% (10/45) cases. All invasive carcinomas, 17% (8/45), cases were obtained by excisional methods in this group of patients.

Invasive cervical carcinoma was diagnosed in 6.15% (8/130) of patients in specimens obtained by excisional procedures.

Discussion

Cervical intraepithelial neoplasia (CIN) represents a great problem, especially in the countries where a wide population screening programme is not established. The percentage of cervical carcinoma in Vojvodina compared to all malignant diseases in women amounts to 7.76% and 6.7% of the total mortality due to malignant tumours in the female population. According to the age-specific incidence rate, the peak of the diagnosed cervical carcinoma is in the age group of 40 to 44 years of age (13). Bosch et al. showed in their study that mild abnormalities of the cervical epithelium (CIN 1) appear most often in the group between 20 and 30 years of age. Moderate and severe dysplasia are usually found in the 30–40 year age group, while in the age group from 40 to 60 years, invasive carcinoma is more common (4). Our results showed a similar age distribution. Due to a small sample, the difference within the older age groups in this study could not be statistically established.

Abnormal PAP test is usually followed by colposcopy which is a good method for the detection of areas with suspected change. The sensitivity of the conventional PAP test and colposcopy together are as high as 87–99%, but the specificity of the method was relatively low, 23–87%. The sensitivity and specificity of both methods in distinguishing mild dysplasia from higher grades of cervical dysplasia, were 64–99% and 30–99% (14). The most frequent discrepancies were observed within the group of patients with biopsies showing high grade dyskaryosis (CIN 2 and CIN 3), where the findings in the specimens obtained by excisional procedures showed higher grade of dysplasia. Usually CIN 2 obtained by punch biopsy, was reported as CIN 3 on the excised specimen in 35% of the cases. In CIN 3 obtained by biopsy, 17% of cases had an invasive carcinoma. However, if we classified CIN 2 and CIN 3 into one group, i.e. the H SIL, a grade of discrepancy would be significantly lower. Therefore, the modality of the therapy in this case does not change, and the application of one of the excisional techniques represents an acceptable diagnostic-therapeutic modality of treatment. In the presented material, 6% of diagnosed invasive carcinoma cases were not obtained by biopsy. Costa S and others also showed about 6% of non-diagnosed cervical carcinomas in their study material of 739 patients with biopsy obtained H SIL changes in comparison with patho-histological findings after conisation (15). In earlier studies, the percentage of non-diagnosed cervical carcinoma in the biopsy was between 0–8.9% with a median of about 2% (16–18). In the same study, the definitive HP findings in cones were without any lesion in 13% of patients. This result is similar to the obtained results in our study of 14%. The majority of the patients without dysplasia are in the group of

patients with a CIN 1 lesion. One of the most significant problems was missing a coexisting carcinoma, and consequently giving inadequate treatment, which can lead to serious consequences. Furthermore, the consequences of inadequate treatment may impact on a doctor's confidence in the conservative approach of treating CIN changes. Also this questions the quality of the cyto-diagnostics, colposcopy and biopsy as basic diagnostic methods of proving early invasive carcinoma (19, 20).

The possible factors which may influence the findings are: (15, 21):

- Age of the patients
- Visibility of squamous-columnar junction
- Quality of colposcopy
- Clear recognition of suspicious areas in the cervix through colposcopy
- The necessity of multi-area biopsies
- Multi-focal changes

Cardenas-Turanzas M et al. in their review article included approximately 26 studies, and suggested that optical spectroscopy may help localize lesions and therefore be an effective adjunct to colposcopy (22).

Conclusion

A statistically significant difference was demonstrate by comparing the punch biopsy findings and the material obtained by excisional techniques. The most frequent discrepancies were observed in the group of patients with a CIN 2 lesion. In about 6% of the total number of patients invasive carcinoma was not diagnosed through punch biopsy. Cervical carcinoma is usually diagnosed in patients with a higher grade of dysplasia obtained by punch biopsy and patients older than 30 years. Based on the obtained results, regarding the group of patients over 30 years of age and such discrepancy in histopathological findings, it is necessary to insist on one of the excisional techniques as a diagnostically-therapeutically acceptable method. The CIN 1 lesions confirmed by biopsy require a more conservative approach due to the fact that this group usually demonstrated a negative finding in the cone after an excisional technique.

References

1. Boyle P, Ferlay J. Cancer incidence and mortality in Europe, 2004. *Annals of Oncology* 2005, 16: 481–8.
2. Mandić A. Seksualno prenosive bolesti, promene na grliću materice i Papanikolau test. Institut za onkologiju Sremska Kamenica, Štamparija Zamurović, 2006: 1–15.
3. Richart RM. Cervical intraepithelial neoplasia: a review. In: Sommers SC, ed. *Pathology Annual*. East Norwalk, CT: Appleton-Century-Crofts; 1973: 301–28.
4. Bosch X, de Sanjose S. Human papillomavirus and cervical cancer – burden and assessment of causality. *Nat Cancer Inst Monogr* 2003; 31: 3–13.
5. Pagliusi S, Aguado MT. Efficacy and other milestones for human papillomavirus vaccine introduction. *Vaccine* 2004; 23: 569–78.
6. Solomon D, Davey D, Kurman R, et al. The 2001 Bethesda System: terminology for reporting results of cervical cytology. *JAMA* 2002; 287(16): 2114–9.
7. Kešić V. Kolposkopija i bolesti donjeg genitalnog sistema žene. Zavod za udžbenike i nastavna sredstva, Beograd, 2000: 9–15.
8. Wright TC Jr, Massad LS, Dunton CJ, et al. 2006 consensus guidelines for the management of women with cervical intraepithelial neoplasia or adenocarcinoma in situ. *J Low Genit Tract Dis* 2007 Oct; 11(4): 223–39.
9. Cox JT. Management of cervical intraepithelial neoplasia. *Lancet* 1999 Mar; 353(9156): 857–9.
10. Mitchell MF, Tortolero-Luna G, Cook E, et al. A randomized clinical trial of cryotherapy, laser vaporization, and loop electrosurgical excision for treatment of squamous intraepithelial lesions of the cervix. *Obstet Gynecol* 1998 Nov; 92(5): 737–744.
11. Radiohirurški nož, dr Opiel. http://www.011medicalgroup.rs/radiohirurški_aparat.html.
12. Stanimirović B. Dijagnostika i lečenje oboljenja cerviksa, vagine i vulve. Elit-Medica, Beograd, 2006; 63–71.
13. Dugandžija T, Mikov Miladinov M. Epidemiological characteristics 1 of cervical cancer in Vojvodina from 1993–2002. Knjiga sažetaka, Simpozijum: Dijagnostika i lečenje raka dojke i vrata maternice, Hrvatska liga protiv raka, Zagreb, 2006; 76.
14. Mitchell MF, Schottenfeld D, Tortolero-Luna G, Cantor SB, Richards- Kortum R. Colposcopy for the diagnosis of squamous intraepithelial lesions: a meta-analysis. *Obstet Gynecol* 1998; 91(4): 626–31.
15. Costa S, De Nuzzo M, Rubino A, et al. Independent determinants of inaccuracy of colposcopically directed punch biopsy of the cervix. *Gynecologic Oncology*, 2003; 90: 57–63.
16. Chen R-J, Chang D-Y, Yen M-L, et al. Independent clinical factors which correlate with failures in diagnosing early cervical cancer. *Gynecol Oncol* 1995; 58: 356–61.
17. Kirkup W, Singer A, Hill AS. The accuracy of colposcopically directed biopsy in patients with suspected intraepithelial neoplasia of the cervix. *Br J Obstet Gynaecol* 1980; 87: 1–4.
18. Matseoane S, Williams SB, Navarro C, Hedriana H, Mushayandebu T. Diagnostic value of conization of the uterine cervix in the management of cervical neoplasia: a review of 756 consecutive patients. *Gynecol Oncol* 1992; 47: 287–91.
19. Serafini M, Cordaro C, Montanari E, Falcini F, Bucchi L. Diagnosis and treatment of cervical intraepithelial neoplasia grade 3: a registrybased study in the Romagna region of Italy (1986–1993). *Int J Epidemiol* 1999; 28: 196–203.
20. Heatley MK, Bury JP. The correlation between the grade of dyskaryosis on cervical smear, grade of cervical intraepithelial neoplasia (CIN) on punch biopsy and the final histological diagnosis on cone biopsies of the cervix. *Cytopathology* 1998; 9: 93–9.
21. Gage JC, Hanson VW, Abbey K, et al. Number of cervical biopsies and sensitivity of colposcopy. *Obstet Gynecol* 2006 Aug; 108(2): 264–72.
22. Cardenas-Turanzas M, Benedet JL, Atkinson N, et al. The clinical effectiveness of optical spectroscopy for the in vivo diagnosis of cervical intraepithelial neoplasia: Where are we? *Gynecologic Oncology* 2007; 107: S138–S146.

Received: 27/09/2012

Accepted in revised form: 28/01/2013

Corresponding author:

Aljosa Mandić, MD, PhD, Oncology Institute of Vojvodina, Institutski put 4, 21204 Sremska Kamenica, Serbia; e-mail: mandic.aljosa@onk.ns.ac.rs
