

Professor Ivo Šteiner, MD, PhD, Editor

CASE 1-2013: FATAL MANIFESTATION OF MYELOPROLIFERATIVE DISEASE

Hana Ševčíková¹, Radek Pelouch¹, Adéla Matějková², Petr Dulíček³

Charles University in Prague, Faculty of Medicine and University Hospital Hradec Králové, Czech Republic: 1st Department of Internal Medicine¹, The Fingerland Department of Pathology², 4th Department of Internal Medicine³

Key words: *Myeloproliferation; Acute coronary syndrome*

Introduction

Myeloproliferative disorders (MPDs) are defined as clonal stem cell diseases. The cardiovascular system is involved in 4 to 21% of MPD cases, presenting as acute ischemic coronary artery disease, valvular heart involvement, pericardial involvement, aortitis, thrombosis of major vessels, pulmonary embolism, systemic and pulmonary hypertension. Acute coronary syndrome may be the first manifestation of myeloproliferation.

Clinical data

A 33-year-old man was admitted to our intensive care unit with acute myocardial infarction. He had no history of arterial hypertension, hyperlipidemia or smoking. Several years earlier, he was assessed for asymptomatic thrombocytosis, and possible MPD was considered (bone marrow biopsy, positive mutation in the gene for JAK2); the “wait and watch” strategy (i.e. no therapy) was chosen. Physical examination on admission showed incipient cardiogenic shock. Urgent coronary angiography was indicated and left main stem occlusion was found. Thrombaspiration and bifurcation stenting LAD-RCx was done and intraaortic balloon contrapulsation inserted. During the coronary intervention the patient was intubated and artificially ventilated. The platelet count on admission was $992 \times 10^9/l$ with gradual decrease during the hospital stay. A complex therapy of the cardiogenic shock continued – artificial ventilation, intraaortic balloon contrapulsation, catecholaminergic support (including levosimendan) and continual hemoelimination. The Swan-Ganz catheter was inserted for optimization of fluid therapy. Dual antiplatelet therapy, IIb/IIIa glycoprotein inhibitors and anticoagulation therapy were introduced. Mechanical circulation support was contraindicated for a febrile state. Despite complex therapy, the shock with multiple organ dysfunction

syndrome progressed and the patient died after 11 days due to circulatory failure.

Pathological findings

Grossly, an extensive subacute transmural myocardial infarction dominated, involving most of the left ventricle. Apart from the infarction, the heart appeared basically normal (heart weight 410 g). A metallic stent was implanted in the proximal left coronary artery. There were signs of heart failure – pulmonary congestion and edema, pericardial effusion (100 ml), bilateral hydrothorax and congestion of the abdominal organs. There were multiple thrombi in the vascular system, affecting (among others) superior and inferior vena cava, both brachiocephalic veins and abdominal aorta, with multiple renal and splenic infarctions. However, practically no atherosclerosis was found. Microscopy confirmed subacute myocardial infarction affecting approximately 80% of the left ventricular myocardium. Multiple small intramyocardial vessels were occluded by fibrinous and thrombotic thrombi. There were signs of a diffuse alveolar damage (ARDS) in the congested lungs. The bone marrow was hypercellular due to panhyperplasia of myeloid cells, particularly erythroid precursors and clusters of megakaryocytes. The latter were pleiomorphic, frequently with hyperlobulated nuclei. The bone marrow histology confirmed the diagnosis of myeloproliferative disorder – polycythemia vera like type.

Discussion

MPDs are neoplastic disorders characterized by proliferation of the myeloid stem cell. Polycythemia vera (PV, one of the MPD family) is characterized by erythrocytosis and thrombocytosis. PV usually affects old individuals, but 4–7% of patients are younger than 40 years (1). Other

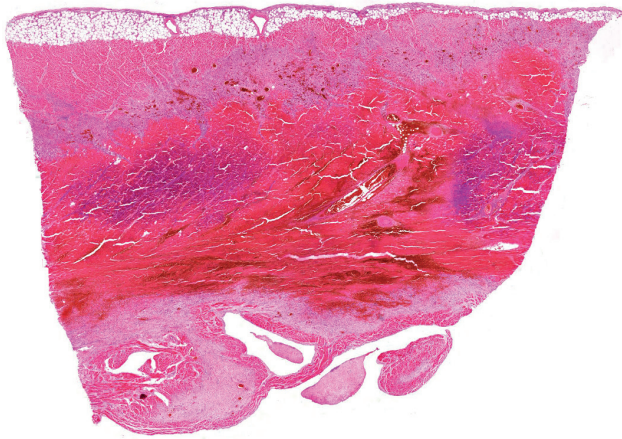


Fig. 1: Transmural myocardial infarction in the anterior wall of the left ventricle, modified by reperfusion (hematoxylin-eosin)

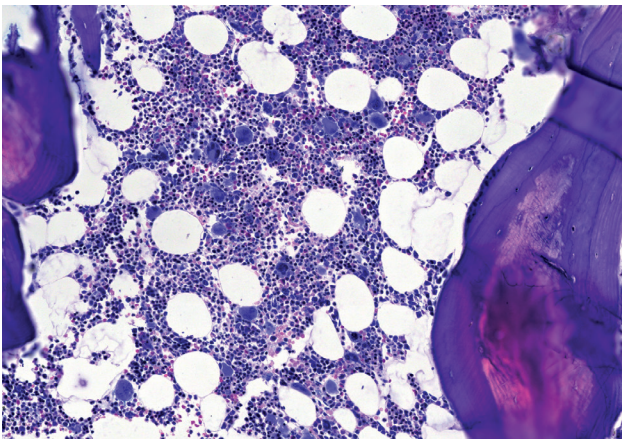


Fig. 2: Bone marrow biopsy (examined one year before death) show the picture of incipient myeloproliferative syndrome of the polycythemia vera type (mild hypercellularity, panhyperplasia of myeloid cells, small noncohesive clusters of pleomorphic megakaryocytes without dysplastic changes). In addition, there were fine reticular fibers and minimal hemosiderin deposits (hematoxylin-eosin)

features of the disease include leukocytosis, splenomegaly, thrombotic or hemorrhagic complications, vasomotor disturbances, pruritus and risk of progression into acute leukemia (2). Bleeding and thrombosis (arterial or venous) are the primary causes of morbidity and mortality. Advanced age, prior history of thrombosis, hyperlipidemia, hypertension, smoking, diabetes mellitus and leukocytosis have been reported as risk factors for thrombosis. Leukocytosis is a consistent risk factor for coronary heart disease and in polycythemia vera it is associated with a higher risk of myocardial infarction (3). The cardiovascular system is

involved in 4 to 21% of cases of myeloproliferative diseases. PV and essential thrombocytemia (ET) predispose to thrombotic complications in cerebral, digital, mesenteric, portal and retinal circulation. Coronary circulation may also be involved, with acute coronary syndrome or sudden death being the first manifestation of newly diagnosed or untreated PV. This, however, is very uncommon under the age of 40 (4, 5). The pathophysiologic mechanisms of thrombus formation include an increased procoagulant activity of the platelets, changes in glycoproteins on the thrombocyte surface, or a possible deficiency of selective lipooxygenase (6). However the pathophysiology of thromboembolism is not fully understood (7). Thrombosis can occur without a severely abnormal platelet count (8). Treatment of patients with acute coronary syndromes and myeloproliferative disorders include reperfusion and antithrombotic therapy. Optimal pharmacologic and interventional management strategies remain unclear; the treatment can be difficult, particularly in the presence of bleeding. An elevated platelet count is an independent risk factor for poor outcome of the myocardial infarction. Given the results of the ECLAP study in PV, low-dose aspirin from the time of presentation in such a patient may possibly reduce the risk of myocardial infarction (5).

Hematologist's comments

The coagulation disorders in MPDs are rather complex and they can be the first manifestation of the disease as well as a later complication. The precise incidence of bleeding and thrombotic events is difficult to assess (9, 10). According to published data, thrombotic complications are more frequent (arterial, venous and microcirculation). In patients with PV and ET, thrombosis has been found in 12 to 39% and 11 to 25% respectively, at the time of diagnosis. Further on the incidence of thrombosis is ca. 1.2%/patient/year in PV and 6.6%/patient/year in ET. Bleeding at diagnosis has been reported with considerable variability: in 1.7 to 20% in PV and in 3.6 to 37% in ET. The incidence of bleeding thereof is close to zero in PV and 0.33%/patient/year in ET (11, 12).

The pathogenesis is multifactorial; changes in all blood elements play a role in coagulopathy (13). Among them, an increased hematocrit, thrombocytemia, thrombocytopathies, and activation of leucocytes are the most important. The risk factors for thrombosis include age, previous thrombosis, inherited or acquired thrombophilia and common cardiovascular risk factors. The treatment is complex. Aspirin is recommended for primary prevention in patients with thrombocytosis and at least 1 risk factor. In the case of thrombosis, it is necessary to maintain the blood count within normal range, and anticoagulation is administered according to standard rules. Anticoagulation therapy is long-term, and often life-long. The classification of patients according to the risk of thrombosis is shown in Tab. 1 (12).

Tab. 1: Stratification of patients according to thrombotic risk

Magnitude of risk	Age	Personal history of thrombosis	Additional risk factor (RF)	Cytoreductive therapy	Antithrombotic
High	> 60 y.	Positive	No	+	Aspirin, Warfarin
Moderate	< 60 y.	Negative	Yes	According to RF	Aspirin
Low	< 60 y.	Negative	No	–	Aspirin

Message from the Editor (Prof. Šteiner)

A young man with an untreated myeloproliferative disease – polycythemia vera – died from myocardial infarction. He had no classical risk factors of atherosclerosis (hyperlipidemia, hypertension, diabetes, smoking) and, indeed, the autopsy showed virtual absence of coronary atherosclerosis.

This is a rare case of coronary thrombosis with myocardial infarction as a lethal manifestation of polycythemia vera.

There are four major diagnostic entities recognized within the family of myeloproliferative disorders – chronic myelogenous leukemia, polycythemia vera, primary myelofibrosis, and essential thrombocythemia. Polycythemia vera usually affects patients over 50 years of age. The major anatomic changes stem from increased blood volume and viscosity brought about by the polycythemia (with low levels of serum erythropoietin). About 30% of patients with polycythemia vera develop thrombotic complications, usually affecting the brain or heart.

Roughly half of affected victims die from thrombosis or hemorrhage, and the other half from leukemia, myelofibrosis with anemia, congestive heart failure, or some other cause.

In our case, we can only speculate whether treatment of the known myeloproliferative disease would prevent the deadly complication.

References

1. Perea G, Remacha A, Besses C, et al. Is polycythemia vera a serious disease in young adults? *Haematologica* 2001; 86(5): 543–4.
2. Tefferi A. Annual clinical updates in hematological malignancies: a continuing medical education series: polycythemia vera and essential thrombocythemia: 2011 update on diagnosis, risk stratification and management. *Am J Hematol* 2011; 86(3): 292–301.
3. De Stefano V, Za T, Rossi E, et al. Recurrent thrombosis in patients with polycythemia vera and essential thrombocythemia: incidence, risk factors, and effect of treatments. *Haematol* 2008; 93(3): 372–380.
4. Venegoni P, Cyprus G. Polycythemia and the heart. *Texas Heart Institute Journal* 1994; 21: 198–201.
5. Kelly SV, Burke RF, Lee KS, et al. Presentation of essential thrombocytosis in a 17-year-old man. *Clinical Advances in Hematology & Oncology* 2008; 6(2): 133–9.
6. Alioglu E, Tuzun N, Sahin F, et al. Non ST-segment elevation myocardial infarction in patient with essential thrombocythemia. *Thrombosis journal* 2009; 7: 1.
7. Saif MW, Khan U, Greenberg BR. Cardiovascular manifestation of myeloproliferative disorders: A Review of the Literature. *Hospital Physician* 1999; July: 43–54.
8. Nanavati A, Patel N, Burke J. Thrombocytosis and coronary occlusion. *J Am Coll Cardiol Intv.* 2012; 5(6): 18–19.
9. Schafer AI. Bleeding and thrombosis in the myeloproliferative disorders. *Blood* 1984; 64: 1–12.
10. Landolfi R, Rocca B, Patron C. Bleeding and thrombosis in myeloproliferative disorders: mechanism and treatment. *Critical reviews in Oncology-Hematology* 1995; 20: 203–22.
11. Elliot MA, Tefferi A. Thrombosis and haemorrhage in polycythemia vera and Essentials thrombocythaemia. *Br J Haematol* 2004; 128: 275–290.
12. Cortelazzo S, Viero P, Finazzi G, et al. Incidence and risk factors for thrombotic complications in a historical cohort of 100 patients with essential thrombocythemia. *Journal of Clinical Oncology* 1990; 8: 556–562.
13. Landolfi R, Cipriani MC, Novarese L. Thrombosis and bleeding in polycythemia vera and essential thrombocythemia: pathogenic mechanism and prevention. *Best Pract Res Clin Haematol* 2006; 19(3): 617–633.

Corresponding author:

Hana Ševčíková, MD, 1st Department of Internal Medicine, University Hospital, Sokolská 581, 500 05 Hradec Králové, Czech Republic; e-mail: hana.sevcikova@fnhk.cz
