

“ELEPHANT TRUNK” AND ENDOVASCULAR STENTGRAFTING – A HYBRID APPROACH TO THE TREATMENT OF EXTENSIVE THORACIC AORTIC ANEURYSM

Tomáš Holubec¹, Jan Raupach², Jan Dominik¹, Jan Vojáček¹

Charles University in Prague, Faculty of Medicine and University Hospital in Hradec Králové, Czech Republic: Department of Cardiac Surgery¹, Department of Radiology²

Summary: A hybrid approach to elephant trunk technique for treatment of thoracic aortic aneurysms combines a conventional surgical and endovascular therapy. Compared to surgery alone, there is a presumption that mortality and morbidity is reduced. We present a case report of a 42-year-old man with a giant aneurysm of the entire thoracic aorta, significant aortic and tricuspid regurgitation and ventricular septum defect. The patient underwent multiple consecutive operations and interventions having, among others, finally replaced the entire thoracic aorta with the use of the hybrid elephant trunk technique.

Key words: *Elephant trunk; Endovascular stentgrafting; Hybrid approach; Thoracic aortic aneurysm*

Objective

Despite significant improvements of the surgical treatment of complex thoracic aortic diseases, these operations still remain challenging for cardio-thoracic surgeons. The establishment of two-stage “elephant trunk” technique by Borst et al. in 1983 facilitated a surgical treatment of these pathologies (1). The first step is performed through a median sternotomy, replacing the ascending aorta and the aortic arch, and leaving an elephant trunk graft in the descending aorta. The second-step procedure (completion of operation) demands an extension of the elephant trunk graft to the healthy distal aorta via left thoracotomy. This approach provides the surgeon with better surgical comfort and allows shortening the aortic cross-clamp time. Although this two-stage procedure is, by many authors, still considered as the “gold standard” (2), the mortality and morbidity remain significant (3).

Case report

A 42-year-old male, with history of rheumatic fever, was referred to our hospital presenting with progressive congestive heart failure. On echocardiography, severe aortic regurgitation combined with moderate stenosis of a bicuspid aortic valve and massive tricuspid valve insufficiency were demonstrated (Figure 1A). Ejection fraction of the left ventricle was 20%. Additionally, a restrictive defect in the mid-muscular part of the ventricular septum (diameter 9 mm) was detected (Figure 1B). On CT scan the whole thoracic aorta, including the aortic root, was dilated. The

maximal diameters of ascending aorta, arch and descending aorta, according to CT-scan, were 87 mm, 40 mm and 72 mm. (Figure 2A, C).

The patient underwent an elective first-step cardio-surgical procedure, through a median sternotomy, using cardiopulmonary bypass and moderate hypothermic arrest with antegrade cerebral perfusion. The aortic valve, root and ascending aorta were replaced with a mechanical valved conduit (modified Bentall procedure). The aortic arch was replaced with a tubular prosthesis using the elephant trunk technique. The innominate artery was direct reimplanted and due to anatomical conditions debranching of the left carotid and subclavian artery had to be done. The left carotid artery was consequently bypassed from ascending aorta using 8 mm tubular prosthesis (Figure 3). Additionally, the tricuspid valve was repaired using an anuloplasty ring and direct closure of the muscular septal defect was accomplished through the tricuspid valve.

The postoperative course was uneventful. Ten weeks after the operation the patient underwent the stentgraft implantation into the descending thoracic aorta. The proximal landing zone of the stentgraft was within the vascular prosthesis of the elephant trunk. The left subclavian artery was occluded using an Amplatz vascular occlusion device. Due to the distal endoleak, type Ib, of the implanted stentgraft a distal extension with another stent-graft was done two months later (Figure 4A, B).

Twenty-nine months postoperatively the patient is symptom-free and in a very good clinical condition. The control echocardiography and CT-angiography scans showed an optimal result of the two-step hybrid procedure

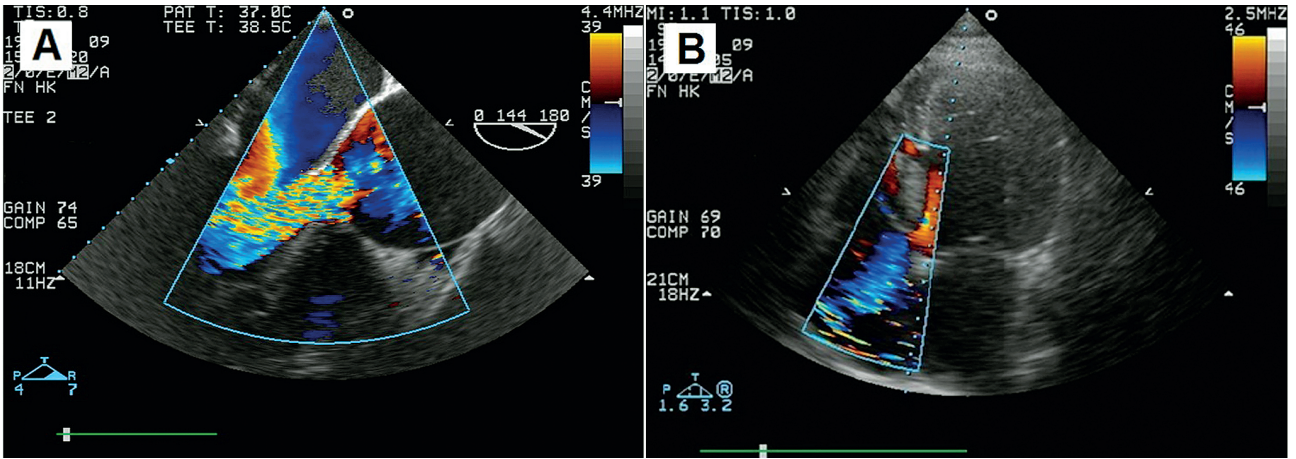


Fig. 1: (A) A preoperative transesophageal echocardiogram with colour Doppler showing a giant aneurysm of the aortic root and adjacent ascending aorta with massive aortic valve regurgitation. (B) A preoperative transesophageal echocardiogram with colour Doppler showing a severe tricuspid regurgitation and mid-muscular ventricular septal defect.

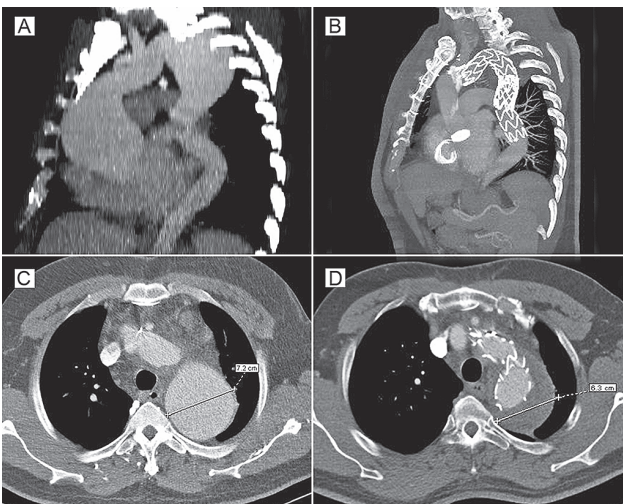


Fig. 2: (A) A preoperative CT scan reconstruction (sagittal plane) showing extensive aneurysms of the ascending and descending aorta. (B) A CT scan reconstruction (sagittal plane) 6 months after distal endovascular extension of implanted stentgraft showing an optimal position of „elephant trunk“, and two distally placed stentgrafts, without evidence of endoleak. (C) A preoperative CT scan (transverse plane) demonstrating a giant aneurysm of the descending aorta, maximal diameter of 72 mm. (D) A CT scan (transverse plane) 6 months after distal endovascular extension of implanted stentgraft demonstrating a completely thrombosed aneurysm of the descending aorta.

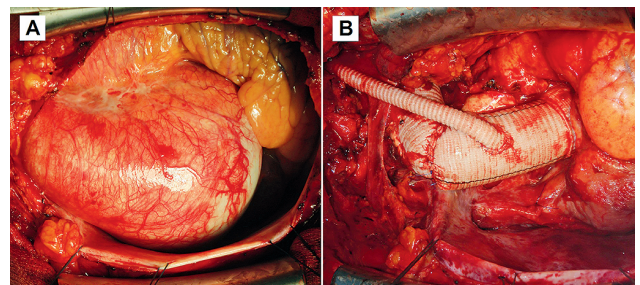


Fig. 3: (A) An intraoperative view of giant fusiform aneurysm of the ascending aorta. (B) An intraoperative view of replaced aortic valve, root and ascending aorta using a mechanical valved conduit. The aortic arch is replaced using elephant trunk technique with re-implanted innominate artery and debranched left carotid artery with bypass from ascending aorta (tubular prosthesis).

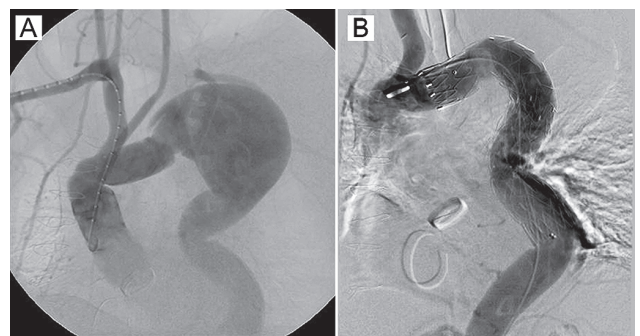


Fig. 4: (A) Aortic angiography (left oblique projection) showing a replaced ascending aorta and arch using the elephant trunk technique (B) Control angiography (left oblique projection) after placement of two stentgrafts into the descending aorta demonstrating a complete exclusion of the descending aortic aneurysm.

using the elephant trunk technique (Figure 2B, D), including the improvement of systolic left ventricular function (ejection fraction 60%).

Discussion

The double-stage “elephant trunk” technique has been a standard procedure for surgical treatment of extensive thoracic aortic aneurysms with satisfactory morbidity and mortality for many years (1, 2). Kouchoukos et al. reported their experience using single-stage repair of the entire diseased thoracic aorta, thereby eliminating the interval period with its attendant risk of aortic rupture. Based on their extended experience they demonstrated this technique to be a safe and suitable alternative to the double-stage procedure (3). Despite this fact, the single-stage approach seems not to be widespread, most likely due to its complexity and more invasive nature.

Since the concept of endovascular completion of the elephant trunk procedure was presented by Fann et al. in 1995, there has been an increasing preference for this hybrid approach (4). It combines the first conventional surgical step performed through sternotomy, followed by the endovascular implantation of a stentgraft into the descending aorta, as a distal extension of the elephant trunk, in the second step. There is some evidence of notable risk reduction in terms of mortality and morbidity, especially paraplegia (5). The first attempts to implant a stentgraft into the descending aorta as an endovascular elephant trunk completion were limited only to high-risk and a selected group of patients (4). Nevertheless, this approach became more popular and widespread over the last years, despite the fact that it may carry a risk of significant complications such as stroke and paraplegia, as well as the occurrence of endoleak and stentgraft migration (5).

Increasingly, these procedures are performed in one step using a “frozen elephant trunk” technique (6, 7). This procedure combines concepts of the elephant trunk and the endovascular stentgrafting performed in one session. It is performed via median sternotomy, where the stentgraft is delivered through the opened aortic arch and its proximal non-

stented Dacron portion is then either sutured directly into the aortic orifice distal to the left subclavian artery (6), or used for replacing the aortic arch (7). Again, this approach promises further reduction in mortality and morbidity by avoiding the stepwise procedure (8). On the other hand, this procedure may be limited by technical equipment of performing institution, sometimes even requiring a hybrid operating room.

Conclusion

We present here a complex cardio-surgical procedure combining several steps and utilizing conventional and endovascular treatment of thoracic aortic disease with satisfactory result. This seems to be a reasonable option for treatment of such a pathology.

Acknowledgements

This work was supported by the project (Ministry of Health, Czech Republic) for conceptual development of research organization [00179906] and by the program [PRVOUK P37/04].

References

1. Borst HG, Walterbusch G, Schaps D. Extensive aortic replacement using the elephant trunk prosthesis. *Thorac Cardiovasc Surg* 1983; 31: 37–40.
2. LeMaire SA, Carter SA, Coselli JS. The elephant trunk technique for staged repair of complex aneurysms of the entire thoracic aorta. *Ann Thorac Surg* 2006; 81: 1561–9.
3. Kouchoukos NT, Masetti P, Mauney MC, Murphy MC, Castner CF. One-stage repair of extensive chronic aortic dissection using the arch-first technique and bilateral anterior thoracotomy. *Ann Thorac Surg* 2008; 86: 1502–9.
4. Fann JJ, Dake MD, Semba CP, et al. Endovascular stent-grafting after arch aneurysm repair using the “elephant trunk”. *Ann Thorac Surg* 1995; 60: 1102–5.
5. Greenberg RK, Haddad F, Svensson L, et al. Hybrid approaches to thoracic aortic aneurysms: the role of endovascular elephant trunk completion. *Circulation* 2005; 112: 2619–26.
6. Karck M, Chavan A, Hagl C, et al. The frozen elephant trunk technique: a new treatment for thoracic aortic aneurysms. *Thorac Cardiovasc Surg* 2003; 125: 1550–53.
7. Uchida N, Ishihara H, Sakashita M, Kanou M, Sumiyoshi T. Repair of the thoracic aorta by transaortic stent grafting (open stent). *Ann Thorac Surg* 2002; 73: 444–9.
8. Uchida N, Katayama A, Tamura K, et al. Long-term results of the frozen elephant trunk technique for extended aortic arch disease. *Eur J Cardiothorac Surg* 2010; 37: 1338–45.

Received: 04/09/2012

Accepted in revised form: 25/03/2013

Corresponding author:

Tomáš Holubec, M.D., Department of Cardiac and Vascular Surgery, University Hospital Zurich, Rämistrasse 100, 8091 Zürich, Switzerland; e-mail: tomasholubec@email.cz
