

USE OF THE NOVABONE® AUGMENTATION MATERIAL IN THE TREATMENT OF CHRONIC PERIODONTITIS. PRELIMINARY COMMUNICATION

Radovan Slezák, Vladimíra Paulusová

Charles University in Prague, Faculty of Medicine in Hradec Králové, and University Hospital Hradec Králové, Czech Republic: Department of Dentistry

Summar: The pilot study deals with the clinical results of the regenerative therapeutical method in intraosseous periodontal defects done by surgical augmentation procedure using a material of a new generation prepared on the basis of a bioactive glass. A group of 10 individuals were treated properly for chronic periodontitis. Some of treated infraalveolar periodontal lesions, both periodontal pockets and interradicular defects, persisted or recurred in posterior teeth. In order to eliminate them they were indicated for advanced periodontal surgery or regenerative surgical therapy stimulating healing processes of supportive tissues, mostly alveolar bone around treated teeth. Relevant clinical parameters, i. e. values of the pocket depth, gingival recession, and loss of attachment were evaluated before and after the periodontal surgery and compared with each other. The therapy led to significant improvement of clinical parameters in terms of the reduction of pocket depth and loss of attachment values.

Key words: *Periodontitis; Bone; Regeneration; Augmentation; Bioactive glass*

Introduction

The main target of periodontal treatment still remains the same and it is to stop the progression of the disease which may lead to premature loss of teeth. In an optimal situation, this is achieved by healing of periodontal pockets as a result of their adequate treatment. Healing mostly occurs through the mechanism sometimes called *repair* of periodontal tissues. Periodontal pockets treated using a state-of-the-art procedure heal relatively quickly and easily leading to the formation of connection called *long junctional epithelium* between the dental root and the surrounding tissues. The new epithelial connection does not have the quality of the original fibrous connection of the tooth to the walls of the bony socket conditioned by the presence of periodontal ligaments and also the vital cementum on the surface of the dental root. Healing of periodontal defects enabled by the formation of periodontal tissues, i.e. the alveolar bone, cementum, and periodontal ligament, which may also occur, is termed the *regeneration* (1–4). If treatment is successful, both repair and regeneration of periodontal tissues leads to a measurable improvement in clinical parameters (reduction of the pocket depth and gingival recession, attachment gain), and also to an improvement in X-ray finding (new bone formation). However, these positive findings do not reveal the mechanism by which the improvement was achieved, whether by repair (long junctional epithelium) or periodontal tissue regeneration (new dental cementum and

new periodontium). This question can only be resolved by histological examination of the treated tooth with its surroundings.

A number of surgical methods have been developed to support the regeneration of the periodontal tissue allowing to achieve this desired type of healing of periodontal lesion, i.e. a pocket or furcation defect of a suitable morphology. Regeneration of supportive tissue can be performed using several methods, including in particular:

- augmentation methods,
- modification of biological properties (biomodification) of the tooth root surface,
- method of guided tissue regeneration,
- combination of the above methods.

Historically, the first regenerative techniques were augmentation methods based on the application of different materials into the cleaned periodontal defect in order to support bone tissue healing by their osteoconductive, osteostimulating or even osteogenetic effects. Today, these materials are in abundance, including autologous and xenogeneic bone as well as new, fully synthetic bone substitutes of different chemical compositions (alloplastic grafts) which change over time, achieving more and more beneficial properties (1–3, 5–7). New bone formation achieved with their contribution can very significantly improve clinical and radiographic parameters, but it is not always associated with new formation of dental cementum and periodontal ligament, i.e. true regeneration of periodontal tissue.

The purpose of our communication was to describe the first results obtained in our department by regenerative therapy of some periodontal defects using a new synthetic augmentation material developed on the basis of bioactive glass which is still rarely referenced in the literature.

Patients and methods

In 2011 and 2012 we treated 10 patients diagnosed with the generalized form of chronic periodontitis using the synthetic augmentation material NovaBone Putty®. The material has been approved duly for clinical use in human medicine including dentistry in the Czech Republic since 2010. The monitored clinical parameters were the depth of periodontal pocket (PD), gingival recession (GR) and loss of attachment (AL). The nature of periodontal pockets and bone resorption and/or the type of infraalveolar defect, i.e. intraosseous defect, and the type of furcation defect was evaluated as accurately as possible preoperatively based on clinical and X-ray findings and specified in more detail perioperatively. In all cases, the surgical procedure was performed only after incompletely successful non-surgical treatment, i.e. in the case of its early (persisting pockets) or late (recurrent pockets) failure. The standardized surgical procedure was performed under local anaesthesia, with only minimally invasive therapy in order to avoid damaging soft tissue as much as possible (marginal intrasulcular incision with a maximum saving of interdental papillae, manual instrumentation, atraumatic suture, magnifying optics) (1, 7, 8). The surface of the tooth root was mechanically cleaned with hand tools and washed with saline only. An adequate amount of augmentation material (without excess) was applied into the cleaned and, if possible, organised intrabony or furcation defect followed by suture which was covered by standard periodontal dressing. After the surgery, in addition to the usual oral hygiene, the patients performed mouth rinses with 0.1% chlorhexidine solution in the usual dosing schedule (2 × 1 minute per day at a dose of 15 ml) until the removal of sutures on post-operative day 9–10. If necessary, they took non-steroidal analgesics. We did not use antibiotic prophylaxis. We also monitored the incidence of postoperative complications and their severity.

The effect of the regenerative surgery was evaluated according to the changes in the values of PD, GR and AL, and mainly according to the parameter called attachment gain given by the difference of pre-operative and post-operative values of AL. The findings were statistically evaluated using the Student's paired t-test, although for the purpose we consider the number of observations (as well as the average duration of post-operative follow-up of the treated teeth) to be near the limit. Also, we did not compare the results of the study to a control group of patients treated for the same indications by classic resective surgical techniques with no stimulation of periodontal tissue. For these reasons, this study is considered to be only a *pilot* study.

Results

The group, characterised in Table 1, consisted of 10 individuals, non-smokers (4 women and 6 men). Their average age at the time of surgery was 51.3 years (range 39–68 years), the average age of the male group was higher than for females (56.7 years and 43.3 years, respectively). A total of 7 teeth were in the upper dental arch, 3 teeth were in the lower arch. The treated teeth were 6 molars and 4 premolars where we treated a total of 10 intrabony defects which were persistent or recurrent 3-wall and 2-wall periodontal pockets, changed during the intra-operative assessment to perioperatively non-diagnosed, or rather non-diagnosable furcation defects of the F2 type according to the Ramfjord classification. The intrabony defects were located mostly on the interproximal, less often vestibular or distal surfaces. The average duration of the postoperative follow-up was 22.4 weeks (range of 10–56 weeks). Table 2 shows the PD, GR and AL values for periodontal defects before and after the regenerative procedure, and also the value of attachment gain in terms of the change in the value of AL. The average changes in the monitored parameters, including their statistical significance, are shown in Table 3. The average postoperative reduction in PD was more than 4 mm. Reduction of the average postoperative values of AL by about 3 mm and adequate postoperative attachment gain differed by slightly higher postoperative GR values (which were on average less than 1 mm) which were detected only in 4 of the teeth treated (Fig. 1). These changes in the PD and AL values were statistically significant. When comparing the effectiveness of the regenerative surgical procedure in a subset of teeth with “only” intrabony defects and the group of teeth with intrabony defects facing furcation areas, we identified a positive effect of the surgery in both types of periodontal defects, both in terms of reduction in the values of PD and AL. The effect was more significant in the intrabony defect subgroup, similar to the values of attachment gain, as shown in Table 4.

Tab. 1: Characteristics of the monitored group

Patient No.	Gender	Age	Tooth + location	Type of intrabony defect
1	M	53	15 dist.	Two-wall, persistent
2	F	44	25 dist.	Two-wall, persistent
3	F	39	46 dist.	Two-wall, persistent
4	F	50	47 vest.	Furcation F2, recurrent
5	M	64	34 vest.	Two-wall, persistent
6	M	68	26 mes.	Furcation F2, recurrent
7	F	40	26 vest.	Three-wall, persistent
8	M	61	15 dist.	Two-wall, persistent
9	M	46	26 distal-palatal	Furcation F2, recurrent
10	M	48	26 distal-palatal	Furcation F2, recurrent

Tab. 2: The depths of periodontal pocket (PD), sizes of gingival recession (GR), loss of attachment (LoA) before and after the treatment of each tooth and values of attachment gain (mm)

Patient No.	PD pre-oper.	GR pre-oper.	LoA pre-oper.	DPP Post-oper.	GR post-oper.	LoA post-oper.	Attachment gain
1	8	2	10	1	2	3	7
2	10	0	10	5	3	8	2
3	6	0	6	4	0	4	2
4	6	1	7	3	1	4	3
5	6	1	7	1	3	4	3
6	5	1	6	4	1	5	1
7	7	0	7	2	0	2	5
8	8	1	9	2	3	5	4
9	7	0	7	1	2	3	4
10	5	1	6	3	0	3	3

Tab. 3: Average changes in values of the monitored clinical parameters in the entire set (mm)

Parameter	Pre-operative value	Post-operative value	Difference in values and standard deviation	Statistical significance level
Depth of periodontal pocket	6.8	2.6	-4.2 ± 2.04	p = 0.0001
Gingival recession	0.7	1.5	+0.8 ± 1.31	p = 0.0868
Loss of attachment	7.5	4.1	-3.4 ± 1.71	p = 0.0001

Tab. 4: Comparison of average changes in PD and LoA before and after the treatment in the subgroups of intrabony pockets and furcation defects and average values of attachment gain (mm).

Defect type	PD pre-oper.	PD post-oper.	Difference in values DPP	LoA pre-oper.	LoA post-oper.	Difference in LoA values (= attachment gain)
Intrabony defect	7.5	2.5	5.0	8.2	4.3	3.9
Furcation defect	5.8	2.8	3.0	6.5	3.8	2.7

Postoperative conditions, which can be termed as the situations complicating the treatment, included in 2 patients dehiscence of soft tissue with exposure of the augmentation material in the oral cavity, which most probably did not affect negatively the defect treated or the success of the regenerative procedure according to the assessment of the clinical parameters. Other conditions included pain or swelling inadequate to the surgical procedure and retrograde pulpitis, always in a single patient.

Discussion

The NovaBone® augmentation material has an interesting history and it appears to have a number of interesting properties. It was developed in 2002 from the previous products prepared at the end of 1960s by L. Hench and his co-workers from Bioglass® Research Center and Advanced Materials Research Center at the University of Florida,

Jacksonville, Fl., USA, on the order of the U.S. Army. It was to address the then arduous treatment of many serious bone defects associated with the American intervention in Vietnam and it was to be a high-quality material for their treatment (9, 10). In 1969, this development resulted in the material Bioglass®, including its modification for the use in dentistry, mainly periodontal indications, called PerioGlas®, launched in the dental market in 1995. The results obtained in regenerative periodontal surgery with this material and similar products are summarized in a recent meta-analysis, the strict criteria of which were met by only 15 studies out of 25, and which shows that the success rate of the treatment of periodontal defects using this augmentation material is very high (11). Information about the effectiveness and benefits of NovaBone®, which is a newer material, in periodontal indications is still missing in the literature.

In periodontal indications, bioactive glass can be combined with the method of guided tissue regeneration (12),

autologous bone (13), with the treatment of intrabony defects using laser (14). In addition, the development of new bioactive glass modifications is heading to the area of nanoparticles (15). The purpose of these combinations and modifications is to achieve induction of the formation of dental cementum and periodontal fibres, i.e. to achieve the properties which in the other non-periodontal indications are not required from these materials.

According to the authors, it is a synthetic, fully resorbable, completely non-toxic calcium-phosphosilicate material exhibiting osteoconductive and osteostimulative effects commensurate with the effect of autologous bone graft (16–18). It is generally applicable in bone regenerative surgery, including dentistry. For these reasons, it is made in several modifications which differ in the sizes of bioglass particles, consistency, and the method of preparation, and it is designed for different types of bone defects (10). In periodontal and similar indications in dental implantology and dentoalveolar surgery, the material with the consistency of putty under the trade name NovaBone Putty® is recommended, as it has been available in the Czech Republic since 2010. Its use in dental indications is not covered by health insurance, unlike orthopedic or neurosurgical indications, and therefore requires financial participation by the patient.

Also its other physical properties put it apart from the rest of other augmentation materials. The putty-like

material does not stick to tools and gloves although it very well clings to the bone. It is of sufficiently stiff consistency, but well condensable. It is also sufficiently radiopaque (Fig. 2). The advantage is its immediate applicability after removal from its protective packaging. As a fully synthetic biomaterial, it is quite free from “biological” risks, such as inadvertent transmission of infections.

All surgeries were indicated primarily for the diagnosis of persistent or recurrent periodontal pocket of the intrabony defect type (infraalveolar pocket) deeper than 5 mm. In four cases, however, it was revealed that alveolar bone resorption continued in the depths of intrabony defect into the furcation area which we could not detect preoperatively (and which could also have been the cause of the previous treatment failure). We always completed the procedure, although generally the guided tissue regeneration method is recommended for furcation defects, or its combination with other regenerative techniques (19).

The two cases, in which we observed in the postoperative period premature loosening of the suture associated with exposure of the augmentation material into the oral cavity, resulted in reepithelisation of the dehiscence and successful healing of both surgical wounds. In conclusion, postoperative complications occurred in 50% of the treated individuals, however, they did not affect the success of the treatment. Higher price will be considered as a time- and

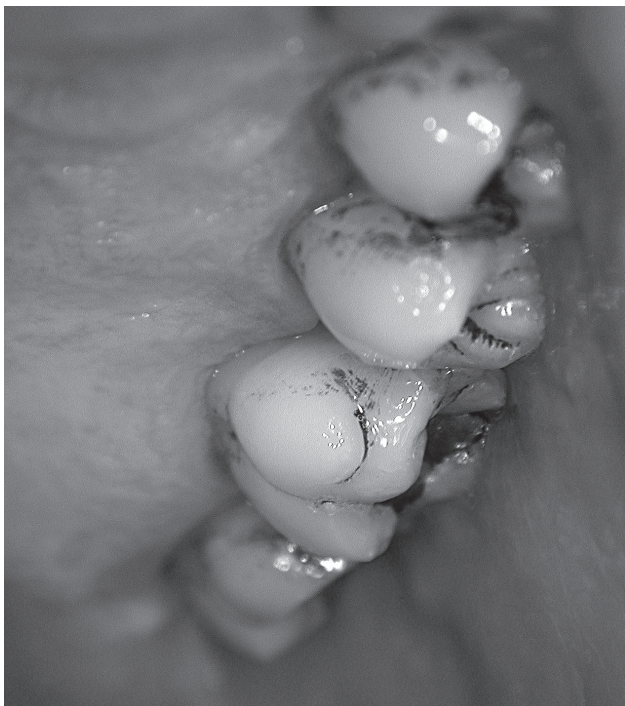

Fig. 1: Postoperative intraoral view on palatal aspects of upper posterior teeth. Note the very small gingival recession at the first upper molar done by a minimal postoperative shrinkage of the previously mobilized gingival flap to get access to the persistent infrabony defect

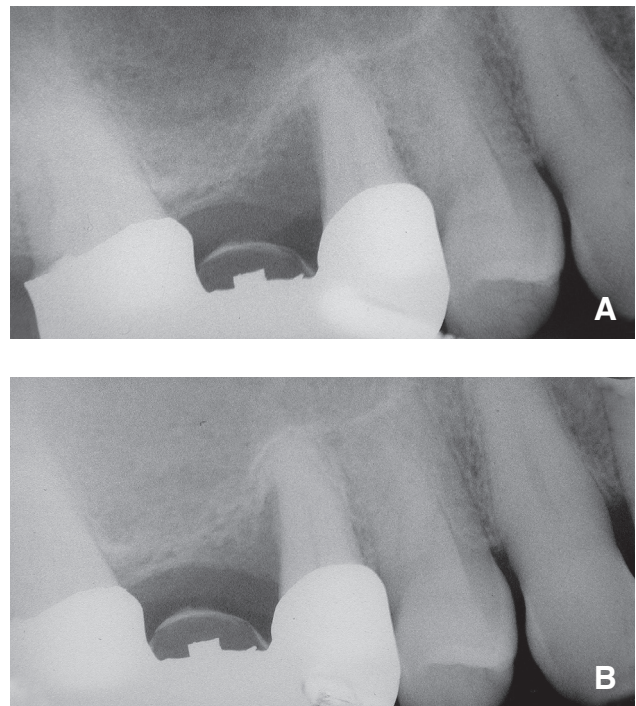


Fig. 2: Detailed radiographs before (a) and three months after (b) the regenerative surgical procedure using NovaBone Putty® augmentation material for filling of the treated persistent intraosseous defect adjacent to the distal aspect of the single root of the right second upper premolar serving as a pillar tooth of the fixed bridge

location-specific problem associated with the use of this augmentation material, which will be reflected in the cost of this method of treatment.

Unlike countless foreign studies, the number of recent domestic studies on regenerative methods and procedures in the treatment of periodontitis remains low (1, 5, 6, 11, 20). Nevertheless, we tried to compare the findings of this truly preliminary study with the results of domestic work from the same workplace. By using synthetic augmentation material based on a mixture of calcium sulphate and beta tricalcium phosphate, Sukumar et al. achieved an average reduction in periodontal pocket depth of 2 mm and a similar attachment gain (21, 22). These were retrospective studies with groups of patients treated for chronic periodontitis as well. Surgical procedures, however, were conducted mainly on anterior teeth, they were associated with bio-modification of tooth roots and systemic antibiotic administration, and the total follow-up was significantly longer.

Conclusions

The results of this pilot study suggest that in the short term, clinical values that characterize the state of the regenerative periodontal surgery using a new generation of materials prepared on the basis of the bioactive glass are quite positive. The material in question appears to have many beneficial properties already during the procedure and we can only hope these will correlate with its regenerative potential in the long-term follow-up. There is no doubt that for more detailed and fully objective evaluation of its properties, particularly the way of healing of periodontal defects, further and more extensive clinical and experimental studies will be necessary.

Acknowledgements

This work came into existence as a part of the research project PRVOUK P37.

References

1. Cortellini P, Tonetti M. Regenerative periodontal therapy. In: Lindhe J, Lang NP, Karring T, eds: Clinical periodontology and implant dentistry. Blackwell Munksgaard, 2008: 901–54.
2. Giannobile WV, Rios HF, Lang NP. Bone as a tissue. In: Lindhe J, Lang NP, Karring T, eds: Clinical periodontology and implant dentistry. Blackwell Munksgaard, 2008: 86–98.
3. Karring T, Lindhe J. Concepts in periodontal tissue regeneration. In: Lindhe J, Lang NP, Karring T, eds: Clinical periodontology and implant dentistry. Blackwell Munksgaard, 2008: 541–69.
4. Wikesjö UME, Susin C, Lee J. Periodontal regeneration: Experimental observations – clinical consequences. In: Larjava H, ed: Oral wound healing. Cell biology and clinical management. Wiley-Blackwell, 2012: 243–60.
5. Sculean A, Arweiler NB. Klinické přístupy v regenerativní terapii parodontu (Clinical approaches in regenerative therapy of periodontium). Quintessenz – Parodontologie (Periodontology) 2010; 11: 37–42.
6. Sukumar S, Dřížhal I. Bone grafts in periodontal surgery. Acta Medica (Hradec Králové) 2008; 51: 203–7.
7. Trombelli L, Farina R. Flap design for periodontal healing. In: Larjava H, ed: Oral wound healing. Cell biology and clinical management. Wiley-Blackwell, 2012: 229–42.
8. Rethman MP, Harrel SK. Minimally invasive perio therapy: Will periodontal therapy remain a technologic laggard? J Periodontol 2010; 81: 1390–5.
9. Imperial College London, College Directory, Department of Materials, at <http://www3.imperial.ac.uk/people/l.hench>.
10. NovaBone. Bioactive Synthetic Bone Graft, at <http://www.NovaBone.com>.
11. Sohrabi K, Saraiya V, Laage TA, Harris M, Blieden M, Karimbux N. An evaluation of bioactive glass in the treatment of periodontal defects: A meta-analysis of randomized controlled clinical trials. J Periodontol; 2012: 453–64.
12. Keles GC, Cetinkaya BO, Albayrak D, Kopulu H, Acikgoz G. Comparison of platelet pellet and bioactive glass in periodontal regenerative therapy. Acta Odont Scand 2006; 64: 327–33.
13. Galindo-Moreno P, Ávila G, Fernández-Barbero JE, Mesa F, O'Valle-Ravassa F, Wang H-L. Clinical and histologic comparison of two different composite grafts for sinus augmentation: A pilot clinical trial. Clin Oral Implant Res 2008; 19: 755–9.
14. Aboelsaad NS, Soory M, Gadalla LM, et al. Effect of soft laser and bioactive glass on bone regeneration in the treatment of infra-bony defects (a clinical study). Lasers Med Sci 2009; 24: 387–95.
15. Tavakoli M, Bateni E, Rismanchian M, et al. Genotoxicity effects of nano bioactive glass and Novabone bioglass on gingival fibroblasts using single cell gel electrophoresis (comet assay): An in vitro study. Dent Res J 2013; 9: 314–20.
16. Hench LL, Polak JM. Third-generation biomedical materials. Science 2002; 295: 1014–17.
17. Oréfice R, Hench L, Brennan A. Evaluation of the interactions between collagen and the surface of a bioactive glass during in vitro test. J Biomed Mater Res A 2009; 90: 114–20. doi: 10.1002/jbm.a.32080.
18. Qiu Z, Yang H, Wu J, Wei L, Li J. Ionic dissolution products of NovaBone® promote osteoblastic proliferation via influences on the cell cycle. J Int Med Res 2009; 37: 737–45.
19. Carnevale G, Pontoriero R, Lindhe J. Treatment of furcation-involved teeth. In: Lindhe J, Lang NP, Karring T, eds: Clinical periodontology and implant dentistry. Blackwell Munksgaard, 2008: 823–47.
20. Stein J, Fickl S, Yekta SS, Hoischen U, Ocklenburg Ch, Smeets R. Clinical evaluation of a biphasic calcium composite grafting material in the treatment of human periodontal intrabony defects: A 12-month randomized controlled clinical trial. J Periodontol 2009; 80: 1774–82.
21. Sukumar S, Dřížhal I, Bukač J, Paulusová V, Pilathadka S. Surgical treatment of periodontal intrabony defects with calcium sulphate in combination with beta tricalcium phosphate. A 12-month retrospective clinical evaluation. Acta Medica (Hradec Králové) 2010; 53: 229–34.
22. Sukumar S, Dřížhal I, Paulusová V, Bukač J. Surgical treatment of periodontal intrabony defects with calcium sulphate in combination with beta tricalcium phosphate: Clinical observations two years post-surgery. Acta Medica (Hradec Králové) 2011; 54: 13–20.

Received: 26/09/2013

Accepted in revised form: 06/12/2013

Corresponding author:

Radovan Slezák, M.D., Ph.D., Assoc. Prof., University Hospital Hradec Králové, Department of Dentistry, Sokolská 870, 500 38 Hradec Králové, Czech Republic; e-mail: slezak@lfhk.cuni.cz
