

## PNEUMOPERITONEUM IN IN-VITRO CONCEIVED QUADRUPLET NEONATE: RARE MANIFESTATION OF HIRSCHSPRUNG'S DISEASE – REPORT OF A CASE

*Jakov Mihanović<sup>1</sup>, Ivo Jurić<sup>2</sup>, Zenon Pogorelić<sup>2</sup>, Ivana Mrklič<sup>3</sup>, Miro Jukić<sup>2</sup>, Dubravko Furlan<sup>2</sup>*

Department of Surgery, General Hospital Zadar, Zadar, Croatia<sup>1</sup>, Department of Pediatric Surgery, Split University Hospital and Split University School of Medicine, Split, Croatia<sup>2</sup>, Department of Pathology, Split University Hospital and Split University School of Medicine, Split, Croatia<sup>3</sup>

**Summary:** Introduction: Hirschsprung's disease is a congenital colonic aganglionosis, usually presented as inability or difficulty in passing of meconium, chronic and persistent obstipation, maleficent feeding, vomiting, distension and lethargy. Case presentation: We presented a case of an in-vitro conceived quadruplet premature neonate who presented with pneumoperitoneum caused by transverse colon spontaneous perforation and microcolon appearance of distal bowel, treated by resection and temporary colostomy turns to be a rare manifestation of Hirschsprung's disease. Conclusion: Assisted reproductive technologies increases chances for multiple pregnancies and may increase chance for major congenital anomalies. Rare manifestation of Hirschsprung's disease is spontaneous pneumoperitoneum which remains a surgical emergency. Delay in recognizing and treatment can significantly worsen prognosis. In neonate with intestinal perforation one should consider Hirschsprung's disease.

---

**Keywords:** *Hirschsprung disease; Pneumoperitoneum; quadruplets; In vitro fertilization*

---

### Introduction

Hirschsprung's disease (HD), a congenital colonic aganglionosis, usually presents as inability or difficulty in passing meconium, chronic and persistent obstipation, poor feeding, vomiting, distension and lethargy. Rare manifestation of the disease is spontaneous perforation which usually takes place proximally to aganglionic colon segment (1, 2). Since introduction in 1978 in-vitro fertilization (IVF) has greatly increased incidence of multiple pregnancies, which raises chances of premature delivery and accompanying complications (3, 4). We present a case of in-vitro conceived premature neonate from quadruplet pregnancy presented with abdominal distension and pneumoperitoneum as a complication of HD.

### Case report

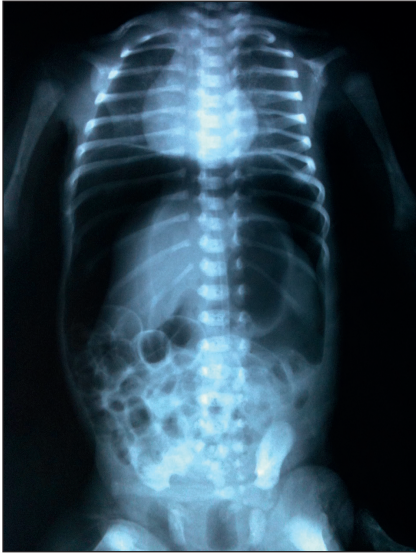Premature male born by caesarean section at 32 weeks + 2 days of gestation presented with spontaneous pneumoperitoneum. Birth weight was 1630 grams. Two fraternal sisters and identical brother were born from quadruplet pregnancy. Mother was healthy 35 years-old, underwent IVF procedure and gave uncomplicated vaginal birth 3 years earlier. Current pregnancy was result of triple transfer of the previously cryopreserved embryos. There were no congenital disorders

in family anamnesis. The patient showed signs of respiratory distress syndrome after birth and was immediately intubated and given endotracheal surfactant. Total parenteral nutrition was introduced. During the first day of life patient was extubated because of satisfactory spontaneous breathing and placed in incubator with oxygen supplementation. Meconium passage was delayed and he had first stool 48 h after birth. Third day of life marked abdominal distension was noticed. Abdominal X-ray revealed massive pneumoperitoneum (Fig. 1).

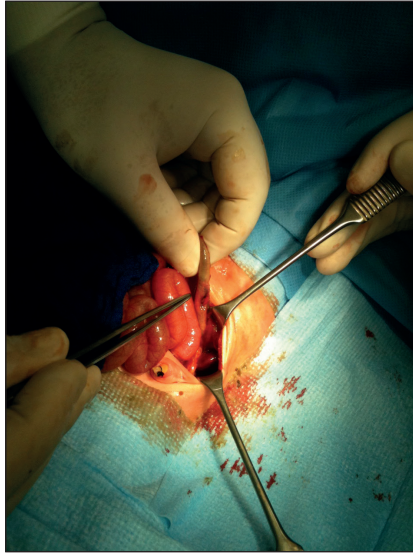
The patient underwent emergency surgery. Transverse laparotomy was performed and perforation measuring 1 × 2 cm was found on antimesenteric border of distal transverse colon with minor local spillage. Distal to perforation colon was narrow – microcolon appearance (Fig. 2). Caecum and ascending colon appeared normal. Resection of affected microcolon was performed, followed by colostomy proximal to the site of perforation. Early postoperative course was uneventful.

Pathohistological analysis confirmed the diagnosis – short segment HD with aganglionic segment beginning on descending colon (Fig. 3).

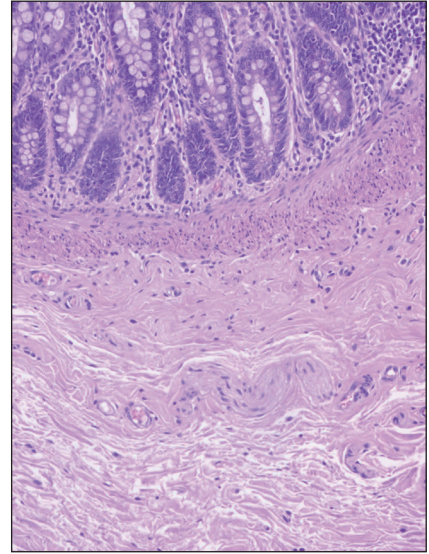
The child had regular stools via colostomy and was thriving well. The patient made rapid recovery and was discharged from the hospital on seventh day after the surgery. Six months later colostomy was closed and standard transabdominal Soave procedure was performed.



**Fig. 1:** Abdominal X-ray: massive pneumoperitoneum.



**Fig. 2:** Perforation on antimesenteric border of distal transverse colon with minor local spillage. Colon distal to perforation site was narrow – microcolon appearance.



**Fig. 3:** Pathohistological findings – Submucosal (Meissner) plexus from the resected specimen of the colon: nerve fibers of the plexus are present, but ganglion cells are absent (HE,  $\times 200$ ).

## Discussion

Assisted reproductive technologies (ART) is general term referring to methods used to achieve pregnancy by artificial means. Several studies showed increased risk of low-birth weight, cerebral palsy and major congenital malformations in newborns conceived in assisted reproductive technologies (4–6). The most important risk factor for children born after ART is high iatrogenic multiple pregnancy rate (4). This is directly related to the practice of transferring multiple embryos at embryo transfer procedure. Even after restriction of number of embryos transferred to 3, percentage of multiple births remains relatively high. Quadruplets delivery rate is between 0.04–0.4% (3, 7). Multiple pregnancy is linked to increased risk of miscarriage, obstetrical complications, prematurity and neonatal morbidity. Neonatal outcome after IVF is worse than in general population, mainly due to the large proportion of multifetal births after IVF. Most mortality rates were twice as high as figures in the general population (8). Hansen et al. have found that infants conceived with use of intracytoplasmic sperm injection or in vitro fertilization have twice as high a risk of a major birth defect as naturally conceived infants (9). Among mentioned congenital malformation are gastrointestinal anomalies, such as cleft lip with or without cleft palate, oesophageal atresia and anorectal atresia. There are no data for incidence of HD among children conceived with ART. In general population HD occurs in approximately 1 per 5000 live births, and is defined as congenital aganglionosis of the distal bowel due to arrest of migration of neural crest cells during embryonic development. HD should be considered in any newborn

with delayed passage of meconium (more than 48 hours). Pneumoperitoneum is rarely the first symptom. It occurs in only 3.4–6% of cases (1, 2, 10, 11). Traditionally, diagnosis and management of intestinal perforation revolves around necrotizing enterocolitis (NEC) which has been used synonymously to the neonatal pneumoperitoneum in the past (12). Classically NEC affects preterm low-birth weight infants. On the other hand, the majority of children with HD are born at term with a normal birth weight. Reports from developing countries warn that NEC participates in almost 50% cases of neonatal pneumoperitoneum, but other causes of perforation should be kept on mind; meconium ileus in cystic fibrosis, intestinal atresia, appendicular perforation, ventilation related barotraumas and particularly HD (12). The mechanism of perforation appears to be directly related to increased intraluminal pressure from distal obstruction. Perforation as first symptom of HD is exclusively seen in neonatal period and is more likely associated with long-segment or total colonic aganglionosis (1, 2). HD in children with neonatal perforation should be on surgeon's mind to avoid delay in the treatment and to plan the resection level. The goal is to place stoma proximal to aganglionic segment, because colostomy at the site of perforation is not satisfactory enough and is related with more complications (2).

Surgical management for HD aims at removing the aganglionic bowel and reconstructing the intestinal tract by bringing the normally innervated bowel down to the anus while preserving normal sphincter function. The surgical approach changed gradually from three-stage procedures to one-stage pull-through without colostomy. This has turned out to be as favorable as the multistage procedures with ben-

efits for the patients and reduction in health care costs due to shorter and fewer hospital stays (12). The development of new techniques has changed the surgical management of HD considerably during the last decade and they are dominating the modern treatment of HD today. The main operative approaches used today are the total transanal endorectal pull-through and the laparoscopic assisted pull-through.

### Conclusion

Assisted reproductive technologies increases chances for multiple pregnancy and may increase chance for major congenital anomalies. Multiple pregnancies are burdened with premature deliveries, lower birth weight, shorter gestation period and associated perinatal morbidity and mortality. HD is congenital aganglionosis and might be related to our patient's perinatal history. Rare manifestation of HD is spontaneous pneumoperitoneum which remains a surgical emergency. Delay in recognizing and treatment can significantly worsen prognosis. In neonate with intestinal perforation, a suspicion of HD should be raised, especially if other causes such as NEC, intestinal atresia or meconium ileus are excluded. Although an uncommon cause, HD has to be kept on mind when facing neonate with free air in abdominal cavity.

### Corresponding author:

---

Ass. Prof. Zenon Pogorelić, M.D., Ph.D., Department of Pediatric Surgery, Split University Hospital Centre, Spinčićeva 1, 21 000 Split, Croatia; e-mail: zenon@vip.hr

---

### References

1. Surana R, Quinn FMJ, Puri P. Neonatal perforation in Hirschsprung's disease. *Pediatr Surg Int* 1994; 9: 501–502.
2. Newman B, Nussbaum A, Kirkpatrick Jr. JA. Bowel perforation in Hirschsprung's disease. *Am J Roentgenol* 1987; 148: 1195–1197.
3. Balen AH, Macdougall J, Tan SL. The influence of the number of embryos transferred in 1060 in-vitro fertilization pregnancies on miscarriage rates and pregnancy outcome. *Hum Reprod* 1993; 8: 1324–1328.
4. Kurinczuk JJ. Safety issues in assisted reproduction technology. From theory to reality – just what are the data telling us about ICSI offspring health and future fertility and should we be concerned? *Hum Reprod* 2003; 18: 925–931.
5. Hansen M, Sullivan E, Jequier AM, et al. Practitioner reporting of birth defects in children born following assisted reproductive technology: Does it still have a role in surveillance of birth defects? *Hum Reprod* 2007; 22: 516–520.
6. Reefhuis J, Honein MA, Schieve LA, Correa A, Hobbs CA, Rasmussen SA. Assisted reproductive technology and major structural birth defects in the United States. *Hum Reprod* 2009; 24: 360–366.
7. Andersen AN, Gianaroli L, Nygren KG. Assisted reproductive technology in Europe, 2000. Results generated from European register by ESHRE. *Hum Reprod* 2004; 3: 490–503.
8. Koivurova S, Hartikainen AL, Gissler M, Hemminki E, Sovio U, Jarvelin MR. Neonatal outcome and congenital malformations in children born after in-vitro fertilization. *Hum Reprod* 2002; 17: 1391–1398.
9. Hansen M, Kurinczuk JJ, Bower C, Webb S. The risk of major birth defects after intracytoplasmic sperm injection and in vitro fertilization. *N Eng J Med* 2002; 346: 725–730.
10. Polley TZ, Jr, Coran AG. Hirschsprung's disease in the newborn. *Pediatr Surg Int* 1986; 1: 80–83.
11. Swenson O, Sherman JO, Fisher JH. Diagnosis of congenital megacolon: an analysis of 501 patients. *J Pediatr Surg* 1973; 8: 587–593.
12. Khan TR, Rawat JD, Ahmed I, et al. Neonatal pneumoperitoneum: a critical appraisal of its causes and subsequent management from a developing country. *Pediatr Surg Int* 2009; 25: 1093–1097.

Received: 20/08/2015

Accepted in revised form: 20/09/2015