

Adult Bochdalek Hernia with Organo-Axial Gastric Volvulus: Misdiagnosed as Hydropneumothorax

Sugandha Arya, Saqib Shahab, Rahul Kumar, Pankaj Kumar Garg*

ABSTRACT

Bochdalek hernia (BH) in an adult may manifest clinically with a myriad of abdominal or chest symptoms or a combination of them. Diagnosis of an adult BH is usually delayed in view of rarity of the lesion and its varied presentation. A 30-year-old adult gentleman presented to us with a left thoracostomy which was draining pus and ingested food particles. The tube thoracostomy had been performed in another hospital for an apparent left hydropneumothorax before he arrived in our hospital. Computed tomography of Chest and abdomen revealed a left diaphragmatic defect with herniation of stomach, spleen and omentum into the chest with organo-axial volvulus of the stomach. A thoracostomy tube was seen to be traversing through the stomach with its tip located close to the left pulmonary artery. The patient underwent left thoraco-abdominal exploration with dissection and reposition of the hernial contents in the abdominal cavity. The gastric perforations and the diaphragmatic defect were repaired. This case reiterates a well-known fact that an adult type BH must find a place in the differential diagnosis of a hydropneumothorax. Though the adult BH is a rare diagnosis, unawareness or reluctance to consider the possibility of adult BH may prolong the suffering of the patient as it happened in our patient who had iatrogenic perforation of the stomach due to tube thoracostomy.

KEYWORDS

diaphragmatic hernia; Bochdalek hernia; tube thoracostomy; gastric volvulus; misdiagnosis

AUTHOR AFFILIATIONS

Department of Surgery, University College of Medical Sciences and Guru Teg Bahadur Hospital, University of Delhi, Delhi, India

* Corresponding author: Department of Surgery, University College of Medical Sciences and Guru Teg Bahadur Hospital, Dilshad Garden, Delhi, India 110095; e-mail: dr.pankajgarg@gmail.com

Received: 21 January 2018

Accepted: 25 May 2018

Published online: 12 December 2018

Acta Medica (Hradec Králové) 2018; 61(3): 108–110

<https://doi.org/10.14712/18059694.2018.127>

© 2018 The Authors. This is an open-access article distributed under the terms of the Creative Commons Attribution License (<http://creativecommons.org/licenses/by/4.0>), which permits unrestricted use, distribution, and reproduction in any medium, provided the original author and source are credited.

INTRODUCTION

Bochdalek hernia (BH) occurs due to persistence of the pleuroperitoneal canal due to the incomplete fusion of the pleura-peritoneal folds (1). They are commonly present on the left posterolateral aspect of diaphragm. BH is usually observed in pediatric age group and rarely diagnosed in adults. The majority of the diaphragmatic hernias seen in adults are frequently secondary to trauma. Though BH in adults is usually detected incidentally, it may present with a varied clinical features including both abdominal or chest symptoms. Failure to consider BH in the differential diagnosis of left lower zone opacity with or without air-fluid level in a chest X-ray may result in misdiagnosis of pleural effusion or hydropneumothorax and a tube thoracostomy injuring the hernia contents. We present a case of BH in an adult who presented to another hospital with chest symptoms. He was erroneously diagnosed to have hydropneumothorax resulting in tube thoracostomy which perforated the stomach, the hernia content.

CASE REPORT

A 30-year-old gentleman presented to us with an in-situ tube thoracostomy which was draining the ingested food. He had developed severe pain in his abdomen in March 2016; the pain responded to nasogastric tube aspiration and proton-pump inhibitors in two days. He did not undergo further investigations that time. Two months later in May 2016, he developed persistent cough. A chest radiograph suggested left lower zone opacity in the chest with an air-fluid level (Fig. 1). He was apparently diagnosed to have left hydropneumothorax in a private hospital and a tube thoracostomy was performed. Surprisingly, the thoracostomy tube started draining the ingested food. Then, the patient was referred to our hospital. Computed tomography of the Chest and abdomen revealed a left diaphragmatic defect with herniation of stomach, spleen and omentum into the chest; there was organo-axial volvulus of the stomach. The thoracostomy tube was seen to be traversing through the stomach with its tip located close to left pulmonary artery (Fig. 2 and 3). The patient underwent left thoraco-abdominal exploration which revealed a large defect in the left posterior diaphragm; the proximal two thirds of the stomach, the spleen and the distal pancreas were present in the left hemithorax with dense adhesions.

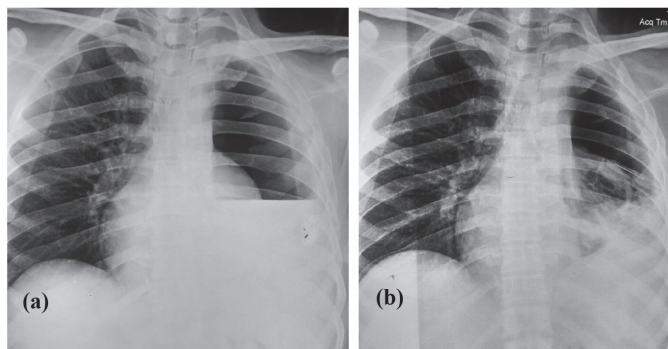


Fig. 1 (a) Pre and (b) post tube thoracostomy chest radiograph.

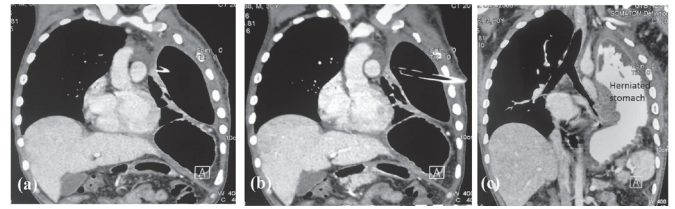


Fig. 2 (a-c) Coronal sections of computed tomography of chest and abdomen.

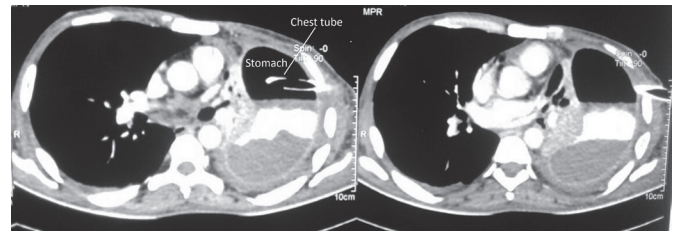


Fig. 3 (a-b) Axial sections of the computed tomography of chest.

Thoracostomy tube was traversing through the greater and lesser curvature of the stomach. There was 100 ml of pus in the left pleural cavity. The abdominal contents were meticulously dissected and positioned back in the abdominal cavity. The gastric perforations were repaired after generous resection of the devitalized edges. The diaphragmatic defect was repaired after a tube thoracostomy was performed for drainage. The postoperative period was uneventful except superficial surgical site infection. The patient is well after 8 months of follow-up.

DISCUSSION

Congenital diaphragmatic hernias were first described by a Czech anatomist and Professor, Vincent Alexander Bochdalek in 1848 (2). This condition was later known by his name as Bochdalek Hernia. Interestingly, Bochdalek hypothesized that the diaphragmatic defect was not the congenital malformation, but rather, it resulted from rupture of an intact membrane of the diaphragm referred to as the trigone of Bochdalek. John J. White argued that it would not be right to label this as BH as the hernia mostly protrudes through the pleuroperitoneal hiatus and not through the trigone of Bochdalek. However, this congenital posterolateral hernia still continues to be known as BH because of the widely appreciated belief of giving due credit to the initial observations of Bochdalek (3). A true BH, which is extremely rare, occurs due to the failure of the development of muscle in the lumbocostal triangle as it leaves the serous pleural sac above and the peritoneum below. Thus, a true BH is a congenital posterolateral hernia with a hernia sac (3).

BH in an adult may present with a myriad of abdominal or chest symptoms or a combination of them. Diagnosis of an adult BH is usually delayed in view of rarity of the lesion and its varied presentation. Moreover, incorrect diagnosis may be thought of in a significant number of patients and may result in unnecessary intervention prolonging the patient morbidity and mortality. In a re-

view of 51 cases of adult BH, Thomas et al reported that it was misdiagnosed in 38% of the patients (4). Adult BH may present with a left lower zone opacity with or without air-fluid level masquerading as an effusion or a hydropneumothorax. A clinician who is unaware of the possibility of BH may be tempted to perform a tube thoracostomy resulting in injury to the hernia contents. BH, though rare, may masquerade hydropneumothorax and a tube thoracostomy intended to manage the same may injure the hernia contents. A detailed chest examination is the key to avoid any misadventure (5). Presence of gurgling gastric or bowel sounds in the chest suggests the presence of diaphragmatic hernia. Moreover, if a chest radiograph is performed after a nasogastric tube is placed; it can delineate the position of the stomach in the chest and clinch the diagnosis. A chest ultrasonography should be done in suspected cases before a tube thoracostomy is done. There is a limited literature regarding the etiology and the management of the hydropneumothorax. A recently published study from India analyzing a cohort of 57 patients of hydropneumothorax highlighted that Tuberculosis (TB) was the etiology in 80.7% patients, acute bacterial infection in 14%, malignancy in 3.5%, and obstructive airway disease in 1.8% (6). All of these patients were managed with tube thoracostomy. The etiology of hydropneumothorax is different in developed countries where incidence of tuberculosis is low.

The definitive treatment of BH is surgical. A number of surgical approaches to address the BH have been described – abdominal, thoracic, or thoraco-abdominal. Abdominal approach is most popular and has distinct advantages over thoracic approach as it allows the inspection of the abdominal viscera and permits the performance of any resection or repairs as required by the condition of these viscera (7). The disadvantages include: (a) difficult access to dome of the diaphragm, (b) difficult reduction of the hernia contents due to negative pressure and possible adhesions within the chest, and (c) unfavorable mechanical features of a closure done on the concave rather than on the convex surface of the diaphragm. The thoracic approach has the advantage of a much more immediate access to the site of the trouble and does away with the negative pressure of the pleural cavity, and so makes reduction easier and gives a much better field for suture of the hernial opening (8). The main disadvantage of the thoracic approach is inability to repair or even to recognize serious intra-abdominal lesions through the thoracic incision alone. The combined abdominal and thoracic

approach obviously affords all the advantages offered by either method alone. We utilized the thoraco-abdominal approach as it greatly facilitated the necessary steps of the operation by allowing us to meticulously dissect the adhesions in the chest, to perform the adequate thoracic lavage, and at the same time provided us the opportunity for a complete inspection of the abdominal organs including repair of the gastric perforations.

Our patient also had organo-axial gastric volvulus, though surprisingly, he did not have vomiting. The first episode of the acute pain in our patient may also be related to the gastric volvulus which got resolved spontaneously. A close look at the position of the nasogastric tube in the chest X-ray done at that time provides a subtle evidence of the gastric volvulus. We did not perform anterior gastropexy as a large part of greater curvature of the stomach, which was unhealthy sloughed out due to iatrogenic perforations caused by tube thoracostomy, was already excised.

This case reiterates a well-known fact that an adult type BH must find a place in the differential diagnosis of a hydropneumothorax. Though the adult BH is a rare diagnosis, reluctance or unawareness to consider the possibility of adult BH may prolong the suffering of the patient as happened in our patient who had iatrogenic perforation of the stomach due to tube thoracostomy.

REFERENCES

1. Hamid KS, Rai SS, Rodriguez JA. Symptomatic Bochdalek Hernia in an Adult. *JLSLS* 2010; 14: 279–81.
2. Loukas M, El-Sedfy A, Tubbs RS, Gribben WB, Shoja MM, Cermakova A. Vincent Alexander Bochdalek (1801–1883). *World J Surg* 2008; 32: 2324–6.
3. Haller Jr JA. Professor Bochdalek and His Hernia: Then and Now. In: Rickham PP ed. *Historical Aspects of Pediatric Surgery* [Internet]. Springer Berlin Heidelberg; 1986 [cited 2016 Oct 12]. p. 252–5. (Progress in Pediatric Surgery). Available from: http://link.springer.com/chapter/10.1007/978-3-642-70825-1_18
4. Thomas S, Kapur B. Adult Bochdalek hernia--clinical features, management and results of treatment. *Jpn J Surg* 1991; 21: 114–9.
5. Garg PK, Kumar A. Clinical examination: losing the shine. *Singapore Med J* 2012; 53: 149.
6. Kasargod V, Awad NT. Clinical profile, etiology, and management of hydropneumothorax: An Indian experience. *Lung India* 2016; 33: 278–80.
7. Suzuki T, Okamoto T, Hanyu K, Suwa K, Ashizuka S, Yanaga K. Repair of Bochdalek hernia in an adult complicated by abdominal compartment syndrome, gastropleural fistula and pleural empyema: Report of a case. *Int J Surg Case Rep* 2013; 5: 82–5.
8. Yamaguchi M, Kuwano H, Hashizume M, Sugio K, Sugimachi K, Hyoudou Y. Thoracoscopic treatment of Bochdalek hernia in the adult: report of a case. *Ann Thorac Cardiovasc Surg* 2002; 8: 106–8.