

# Endoscopic Third Ventriculostomy for Obstructive Hydrocephalus and Ventriculocystostomy for Intraventricular Arachnoid Cysts

Bekir Akgun\*, Sait Ozturk, Omer Batu Hergunsel, Fatih Serhat Erol, Fatih Demir

## ABSTRACT

**Objective:** To evaluate and discuss the outcomes of a combination of ventriculocystostomy (VC) and endoscopic third ventriculostomy (ETV) for obstructive hydrocephalus (HCP) due to ventricular/cisternal arachnoid cysts, and only ETV for obstructive HCP due to different etiologies.

**Methods:** We retrospectively reviewed all 40 symptomatic patients (aged 4 months – 61 years) of obstructive HCP treated by ETV or VC+ETV during October 2014 – April 2019. VC+ETV was performed in 7 patients with intraventricular/cisternal arachnoid cyst and obstructive HCP. Only ETV was performed in 33 patients with obstructive HCP due to other etiologies.

**Results:** Successful ETV or VC+ETV surgery was performed in 35 patients. The procedure failed in 5 patients aged < 1 year; all these 5 patients had a head circumference (HC) of > 90 percentile at the time of surgery. Another 5 patients aged < 1 year showed successful ETV, with a HC of 75–90 percentiles.

**Conclusion:** ETV is a successful alternative treatment for obstructive HCP. The ventricular size may not demonstrate a remarkable reduction post-ETV than post-shunting. Accordingly, increased intracranial pressure may not effectively decrease during the early period post-ETV than post-shunting. Therefore, the success rates of VC and/or ETV are low in very young patients with very high HCs (> 90 percentile).

## KEYWORDS

endoscope; third ventriculostomy; ventriculocystostomy

## AUTHOR AFFILIATIONS

Firat University, School of Medicine, Department of Neurosurgery, Elazig, Turkey

\* Corresponding author: Firat University Hospital, Department of Neurosurgery, Elazig, Turkey; e-mail: bekirakgun@yahoo.com

Received: 26 October 2019

Accepted: 10 November 2020

Published online: 14 April 2021

Acta Medica (Hradec Králové) 2021; 64(1): 29–35

<https://doi.org/10.14712/18059694.2021.5>

© 2021 The Authors. This is an open-access article distributed under the terms of the Creative Commons Attribution License (<http://creativecommons.org/licenses/by/4.0>), which permits unrestricted use, distribution, and reproduction in any medium, provided the original author and source are credited.

**Tab. 1** Demographic features of the patients and details of the surgeries.

Case	Age	Etiology of Hydrocephalus	Operation	Shunt History before ETV	Shunt Necessity after ETV
1	4 m	MMC + Chiari Type 2	ETV	-	+
2	6 m	MMC + Chiari Type 2	ETV	-	-
3	7 m	MMC + Chiari Type 2	ETV	-	+
4	8 m	IV arachnoid cyst (posterior of the 3rd ventricle)	VC + ETV	-	+
5	9 m	MMC + Chiari Type 2	ETV	-	+
6	9 m	Aqueductal stenosis	ETV	-	-
7	10 m	Aqueductal stenosis	ETV	-	+
8	11 m	IV arachnoid cyst (trigone of the right lateral ventricle)	VC + ETV	-	-
9	11 m	MMC + Chiari Type 2	ETV	-	-
10	12 m	Suprasellar arachnoid cyst	VC + ETV	-	-
11	2 y	MMC + Chiari Type 2	ETV	+	-
12	4 y	Suprasellar arachnoid cyst	VC + ETV	-	-
13	5 y	Aqueductal stenosis	ETV	-	-
14	5 y	Aqueductal stenosis	ETV	-	-
15	7 y	Pineal tumor	ETV	-	-
16	8 y	IV arachnoid cyst (body of the left lateral ventricle)	VC + ETV	-	-
17	9 y	IV arachnoid cyst (posterior of the 3rd ventricle)	VC + ETV	-	-
18	9 y	Aqueductal stenosis	ETV	-	-
19	13 y	Quadrigeminal arachnoid cyst	VC + ETV	-	-
20	13 y	Aqueductal stenosis	ETV	+	-
21	14 y	Aqueductal stenosis	ETV	-	-
22	15 y	Pineal tumor	ETV	-	-
23	16 y	Pineal cyst	ETV	-	-
24	18 y	Aqueductal stenosis	ETV	-	-
25	20 y	Pineal cyst	ETV	-	-
26	21 y	Chiari Type 1	ETV	-	-
27	24 y	Aqueductal stenosis	ETV	-	-
28	30 y	Aqueductal stenosis	ETV	-	-
29	32 y	Aqueductal stenosis	ETV	+	-
30	34 y	Chiari Type 1	ETV	-	-
31	36 y	Chiari Type 1	ETV	-	-
32	40 y	Aqueductal stenosis	ETV	-	-
33	45 y	Chiari Type 1	ETV	-	-
34	47 y	Chiari Type 1	ETV	-	-
35	48 y	Chiari Type 1	ETV	-	-
36	51 y	Chiari Type 1	ETV	-	-
37	53 y	Aqueductal stenosis	ETV	-	-
38	57 y	Aqueductal stenosis	ETV	-	-
39	60 y	IV hemorrhage	ETV	-	-
40	61 y	Aqueductal stenosis	ETV	-	-

## INTRODUCTION

Hydrocephalus (HCP) is one of the most common conditions encountered in neurosurgical practice. It is a spectrum of conditions involving an imbalance of cerebrospinal fluid (CSF) production and absorption, with resultant enlarged ventricles that are usually associated with the clinical sequelae of increased intracranial pressure (ICP) (1, 2). In 1923, Mixter first performed endoscopic third ventriculostomy (ETV) after successfully using a urethroscope to perform intervention in a pediatric patient with obstructive HCP (3). Shunt techniques became hugely popular in the 1950s considering the technical limitations of the endoscope, which resulted in high mortality and morbidity rates due to insufficient illumination and low-quality lenses (1, 4). However, there exists no ideal shunt system, and the complications encountered remain a great concern in the long-term management of HCP, with numerous drawbacks related to shunt malfunction and infection (1). In addition, neuroendoscopy gathered attention since the 1990s due to the production of more powerful light sources, small-sized cameras and the achievement of better quality in the optic systems with the advancements in the technology (5-7). Particularly, ETV has gained popularity in the recent years, with evident advantages over the ventriculoperitoneal shunt (VPS) as patients remain device-free (1, 2, 5). This technique provides direct communication between the third ventricle and interpeduncular and prepontine subarachnoid spaces so as to re-establish the normal CSF flow by perforating the floor of the third ventricle (2, 5, 7). Hence, it is the treatment of choice for obstructive HCP (stenosis of the aqueduct of Sylvius, Dandy-Walker malformation and Chiari malformations types I and II) (8). Recently, some preliminary reports of successful ETV employment in patients with communicating HCP have been reported, including idiopathic normal pressure HCP (9). However, past studies have shown that ETV is associated with more favorable outcomes in cases with obstructive HCP. The highest success rates have been reported in patients with obstructive HCP secondary to aqueductal stenosis (10).

Arachnoid cysts refer to a collection of CSF within a cyst wall lined with arachnoid cells and collagen. The pathophysiology of arachnoid cysts remains unclear. Although they are located mostly in the temporal fossa, several intracranial and intraspinal localizations have been reported. In addition, they can be found in the ventricles and cisterns (11, 12). Several arachnoid cysts are asymptomatic, while symptomatic arachnoid cysts can present with signs and/or symptoms resulting from increased ICP or local mass effect on the adjacent structures. Such cases often require surgical decompression of the cyst, which can be achieved by using craniotomy or shunt systems. Presently, we have techniques to treat intraventricular and/or intracisternal cysts that causes obstructive HCP with fenestration into the ventricle [ventriculocystostomy (VC)] and ETV performed simultaneously as a result of advancements in neuroendoscopy (11-14).

In this study, we discussed and analyzed our experience of the management and results of VC and ETV performed in patients with obstructive HCP due to ventricular or cisternal arachnoid cysts; and only ETV was performed for the treatment of obstructive HCP due to different etiologies.

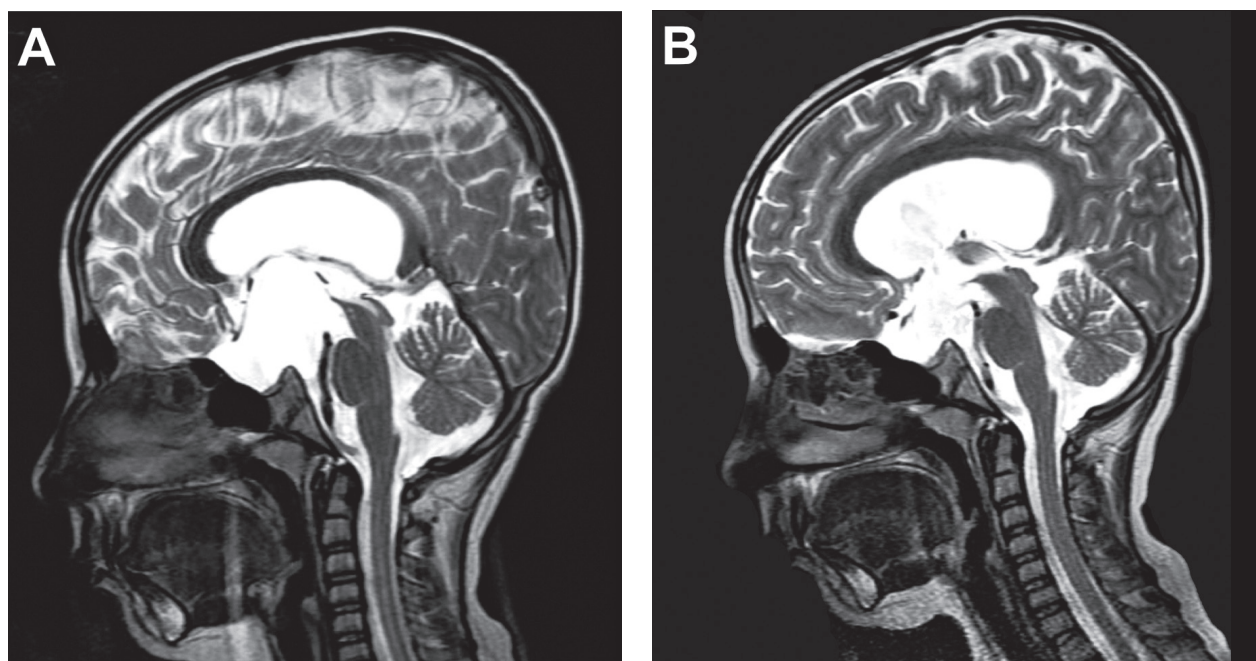
## MATERIAL AND METHODS

We retrospectively reviewed all cases of obstructive HCP treated with ETV or VC+ETV between October 2014 and April 2019 at our hospital. In total, 40 patients with symptomatic HCP of age 4 months – 61 years were evaluated, of which 18 were women and 22 were men. Seven patients showed obstructive HCP due to intraventricular or cisternal arachnoid cyst, and 33 showed obstructive HCP due to other etiologies such as Aqueductal stenosis, Chiari malformations, myelomeningocele and pineal cyst/tumor. Table 1 displays the enrolled patients' demographic features, etiologies of HCP, the applied surgical techniques, shunt history and the necessity of performing the shunt procedure after endoscopic procedures. The patients with colloid cysts and intraventricular tumors were excluded.

**Tab. 2** Correlation between the head circumference and the success in patients aged <1 year.

Case	Age	Operation	Head circumference	Success of the procedure
1	4 m	ETV	> 90 percentile	-
2	6 m	ETV	75-90 percentile	+
3	7 m	ETV	> 90 percentile	-
4	8 m	VC + ETV	> 90 percentile	-
5	9 m	ETV	> 90 percentile	-
6	9 m	ETV	75-90 percentile	+
7	10 m	ETV	> 90 percentile	-
8	11 m	VC + ETV	75-90 percentile	+
9	11 m	ETV	75-90 percentile	+
10	12 m	VC + ETV	75-90 percentile	+

m: months, VC: ventriculocystostomy, ETV: endoscopic third ventriculostomy



**Fig. 1** T2W-sagittal MRI of a 12-month-old boy included in this study. (A) Preoperative MRI showing a suprasellar arachnoid cyst extending to the third ventricle and the foramen of Monro, which caused the dilation of the lateral ventricles. (B) Reduction in the sizes of the cyst and the third ventricle after VC+ETV treatment in the postoperative first-month MRI. In addition, the CSF flow artifacts were observed at the site of VC (from the foramen of Monro to the third ventricle) and ETV (from the third ventricle to the prepontine cistern).

Table 2 displays the correlation between the head circumference (HC) and the success in patients aged < 1 year. The success rates of the procedures were primarily defined using clinical resolutions accompanied with radiological confirmations (Figure 1).

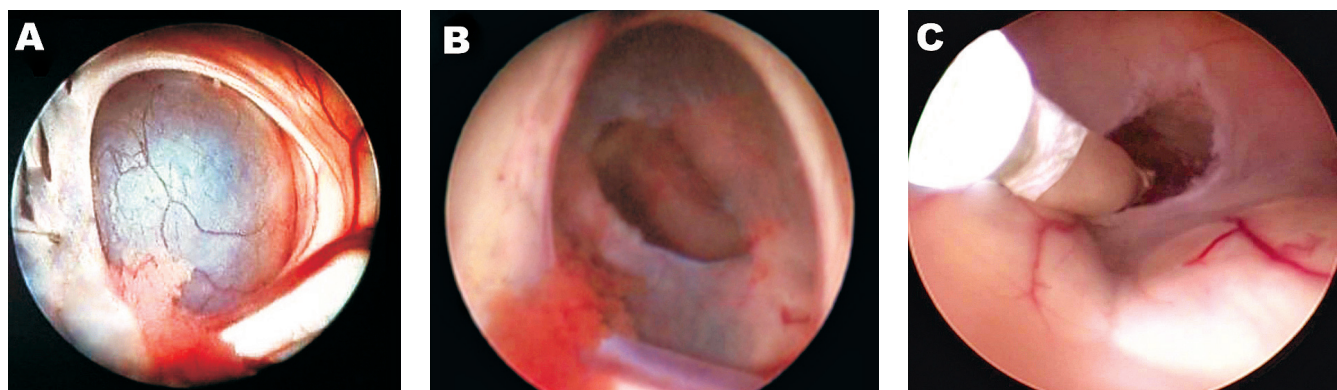## RESULTS

Seven patients were operated for intraventricular or cisternal arachnoid cysts by a combination treatment of VC and ETV. The surgical intervention was unsuccessful in only one 8-month-old patient from these 7 patients. In addition, this patient had a HC of > 90 percentile at the time of the surgical intervention.

Only ETV was performed in 33 patients with obstructive HCP due to other etiologies. Of these, 14 patients

had aqueductal stenosis. The applied procedure failed in a 10-month-old boy who had a HC of > 90 percentile at the time of the surgery. In addition, 6 patients had meningocele. ETV failed in 3 of these 6 pediatric patients aged 4, 7 and 9 months, who had a HC of > 90 percentile. These 3 patients had VPS history and were admitted because of shunt dysfunction. We performed ETV after shunt removal and achieved successful results; the treated patients remained shunt-free.

Successful ETV or VC+ETV (Figure 2) were performed in 35 of the 40 patients. VPS was applied in case of unsuccessful procedures. The procedures were unsuccessful in 5 patients aged < 1 year. In addition, they had a HC of > 90 percentile at the time of the surgery. ETV was successful in other 5 patients aged < 1 year who had HC of 75–90 percentiles. In our series, the procedure failure was not observed in adult patients and in those of age > 1 year.



**Fig. 2** Neuroendoscopic surgical photographs of a 12-month-old boy included in this study. (A) The view of the foramen of Monro and the third ventricle arachnoid cyst. (B) Fenestrated and dilated cyst wall. (C) After entering the cyst, we proceeded to the third ventricle floor and performed ETV. Fenestrated third ventricle floor can be seen.

Various complications arise in these kinds of neuroendoscopic procedures. For instance, CSF leakage can occur because of the failure of surgical closure. However, this condition can be observed in procedure failure. In 2 of the 5 patients in whom ETV failure was recorded, CSF fistula developed from the incision site after ETV. The first patient could be treated through the conservative method and the second one through surgical intervention (i.e. dural repair with synthetic dura material and fibrin sealant). Bradycardia occurred in 1 patient immediately after the fenestration of the third ventricular floor, and the patient was ameliorated after removing the endoscope from the third

ventricle. Intraventricular hemorrhages were recorded in 2 patients, and they were controlled within a few minutes of performing irrigation.

## DISCUSSION

VPS remains the most common treatment approach for HCP across the world. In the treatment of HCP and arachnoid cysts, significant reductions in the ventricular and/or cyst sizes could be noted after shunt surgeries in the early postoperative period (2, 5, 6, 11). Despite the sophisticated

**Tab. 3** Case series of intraventricular arachnoid cysts managed with endoscopic surgery

Authors (ref)	Study period	n	Cyst localization	Primary clinical features at presentation	Complications	Success (n)
Ozek and Urgan (13)	1994–2010	34	suprasellar-prepontine	hydrocephalus and macrocrania (n = 32), developmental delay (n = 6), visual field defect (n = 9), endocrine dysfunction (n = 9), central tremor (n = 3), loss of visual acuity (n = 2), seizure (n = 2)	transient abducens nerve palsy (n = 1), growth hormone deficiency (n = 1), salt wasting syndrome (n = 1)	34
Cinalli G et al. (5)	1995–2008	14	quadrigeminal cistern	hydrocephalus (n = 10), intracranial hypertension (n = 7), enlarging cyst (n = 6), macrocrania (n = 4)	subdural collection (n = 1), postoperative CSF leak (n = 1), intraoperative bleeding (n = 2)	11 of 14
Tamburrini et al. (27)	2000–2006	26	quadrigeminal cistern, paraventricular, suprasellar, and choroid plexus	hydrocephalus (n = 15), headache (n = 8), increasing head circumference (n = 7), asymptomatic (n = 5), bulging fontanelle (n = 3), hemiparesis (n = 3), strabismus (n = 3), seizures (n = 2)	none	26
Ersahin and Kesikci (19)	2000–2007	17	quadrigeminal cistern	hydrocephalus (n = 17), macrocephaly (n = 12), bulging fontanelle (n = 7), headache (n = 3), sun-setting eyes (n = 2), nausea/vomiting (n = 2), psychomotor retardation (n = 2)	subdural collection (n = 3), CSF leak/meningitis (n = 1)	10 of 17
El-Ghandour (28)	2001–2009	25	Suprasellar	macrocrania (n = 12), intracranial hypertension (n = 12), developmental delay (n = 5), precocious puberty (n = 1), seizures (n = 1)	arterial bleeding (n = 1), CSF leak (n = 1), subdural collection (n = 1)	22 of 25
Knie et al. (12)	2002–2015	10	velum interpositum, quadrigeminal cistern	enlarging cyst (n = 5), seizures (n = 2), hydrocephalus (n = 2), hemiparesis (n = 1), optic atrophy (n = 1), mass effect (n = 1)	seizures (n = 2)	10
Copley P et al. (11)	2005–2016	29	suprasellar, velum interpositum, lateral ventricles, quadrigeminal cistern, third ventricle (posterior)	hydrocephalus (n = 29), increasing head circum./macrocephaly (n = 12), vomiting (n = 6), seizures (n = 5), bulging fontanelle (n = 4), developmental delay (n = 4), headaches (n = 3)	asymptomatic subdural CSF collection (n = 2), seizure (n = 1), wound leak (n = 1), diabetes insipidus (n = 1), intraoperative subdural hematoma (n = 1)	25 of 29

n: number of patients

advancements in the shunt systems, they are usually associated with several complications and numerous revisions due to either malfunction or infection. Thus, the provision of a long-term, quality-of-life to children with HCP seems extremely urgent. ETV could be an attractive alternative to the commonly utilized VPS. If it is effective, ETV can prevent long-term morbidity and mortality inherent to shunt-related complications (5, 15, 16).

Intraventricular or intracisternal arachnoid cysts near the ventricles are difficult to treat because of their deep locations. Craniotomy and cyst excision or fenestration therefore carries the risk of significant potential complications, such as neurological deficits (hemiparesis or cranial nerve injury), subdural hematomas, seizures, CSF leakages and meningitis. Moreover, open surgeries involve complication risks due to the long-duration of anesthesia. The significant potential morbidity of microsurgical fenestration and the high incidence of shunting complications have prompted neurosurgeons to search for an alternative procedure. Cumulatively, endoscopic fenestration has become the first choice of treatment because of its minimally invasive nature and the high success rates (11, 13, 14). Table 3 shows a literature review of the largest previously published case series of intraventricular arachnoid cysts managed with endoscopic surgery.

Although ETV, VC and other types of intraventricular neuroendoscopic interventions are considered safe, various complications resulting from them have been reported, including cardiac arrhythmias, injury to the hypothalamic-pituitary axis and/or structures near the floor of the third ventricle, vascular injuries, CSF fistulas, meningitis and sepsis (1, 8, 16, 17). Transient bradycardia is the most frequent hemodynamic alteration resultant from the impression of the third ventricular floor; therefore, on diagnosis, surgeons should pause fluid irrigation and ballooning and then remove the endoscope from the third ventricle. Intraoperative cardiac arrests have been reported very rarely in this condition. Bradycardia has been reported in only 1 patient in our series, immediately after the fenestration of the third ventricular floor. The patient was ameliorated after removing the endoscope from the third ventricle (6, 16, 18). Moreover, injuries to the fornix, hypothalamus and cranial nerves could be observed because of the anatomical proximity. Although it has rarely been reported, increased ICP due to closed and obstructed outflow channels or excessive irrigation can delay awakening and cause persistent confusion (2, 18). Intraventricular hemorrhage can occur because of choroid plexus, vein, or artery injury during the third ventricle floor perforation. Injury to the basilar artery is the most feared intraoperative complication. The fenestration point in the third ventricle floor should always be in front of the basilar tip. Before surgery, detailed evaluation of the radiological investigations must be performed to assess the possible variations, most of which can be controlled through continuous irrigation. In this study, intraventricular hemorrhages were recorded in 2 patients and controlled within a few minutes through irrigation (16–18). CSF leakage can occur because of the failure of surgical closure. Tight suturing of the layers and occlusion of the cortical and calvarial holes with hemostatic agents can prevent this complication (16, 17).

In 2 patients, CSF fistula was detected at the incision site after ETV. The first patient could be treated conservatively (by resuturing the skin incision) and second one surgically (by dural repair with synthetic dura material and fibrin sealant). These 2 patients suffered from ICP symptoms after the treatment of the CSF fistulas; next, they were treated using VPS. Thus, CSF fistula was caused not only due to the surgical closure failure but also due to the application of the unsuccessful ETV procedure because of the high intraventricular volume and/or pressure. In other words, CSF leakage could indicate treatment failure.

The success of ETV can be determined by assessing clinical improvements and the absence of the need for further surgical procedure. Moreover, the simplest definition of successful ETV is 'freedom from a shunt'. Criteria as per the radiological investigations include decreased or stabilized ventricular size, especially that of the third ventricle, CSF flow through the fenestration point and straightened third ventricle floor that sprang downward (1, 16, 17). However, the ventricle size may not show a remarkable reduction on imaging post-ETV than post-shunting. However, this aspect does not necessarily reflect increased ICP (17). Hence, the main criterion for successful surgery should be the improvement of the clinical symptoms.

The correlation between ETV success and the patient's age is one of the most controversial issues. In a study by Erşahin and Kesikçi (19), almost all patients aged < 6 months who underwent both cyst fenestration and ETV required VPS postoperatively. In contrast, only a few studies indicated that there was no difference in the success rates in very young patients compared with older patients or that the rate was only slightly lower (20,21). Sufianov et al. (22) observed that ETV was successful in 71.4% of children aged 1–2 years and in 75.0% of children aged < 1 year. Recent studies have reported that the success of ETV mainly depended on the etiology of HCP and not on the patient's age alone. Several authorities consider patients with communicating HCP, especially due to the history of CSF infection or subarachnoid hemorrhage, to be more prone to ETV failure than those with obstructive HCP (2, 23). However, even in obstructive HCP, ETV failure can occasionally be observed in extremely young patients, especially in newborn and premature babies. Past studies have advocated different contributory factors to the worse outcomes of ETV in younger children. For instance, lesser efficacy for CSF reabsorption due to immaturity of the brain pathways in the arachnoid spaces/Pacchionian granulations, the development of new arachnoid membranes that obstruct the stoma, and low-gradient CSF reabsorption in newborns with open sutures are some of the contributing factors (15, 24).

Despite several investigations on the correlation between ETV success and the patient's age, no studies have yet reported the association between ETV success and HC or the ventricular volume. In our study, procedures were unsuccessful in 5 of 10 patients aged < 1 year. A common characteristic of these patients was a HC of > 90 percentile. HCP causes an increase in the intraventricular volume and pressure, which subsequently increase the fetal head size. Various investigations have shown that, in children with HCP, severe ventriculomegaly has been associated

with less favorable outcomes when compared with mild ventriculomegaly because of the high ventricular pressure or brain parenchyma compression (25). Furthermore, an increase in the fetal head size is associated with increased intraventricular pressure and volume (26). Shunts are mechanical drainage systems, with the features of rapid and high effectiveness. ETV re-establishes the physiological route of CSF dynamics, although the ventricular size may not result in a remarkable reduction post-ETV when compared with that post-shunting. Accordingly, increased ICP may not effectively decrease during the early period by ETV when compared with that by shunting. Therefore, the low success rates of VC and/or ETV may be observed in very young patients with a high HC.

## CONCLUSIONS

ETV is currently considered as a successful alternative to the shunt systems in the treatment of HCP. However, most studies have reported that ETV has low success rates in patients aged < 1 year. In contrast, only a few studies have indicated the absence of any difference in the success rates in extremely young patients when compared with older patients. As per the past reports, in infants and very young patients, the underdeveloped subarachnoid space plays a role in ETV failure. In this study, no failure was observed in children aged > 1 year and in adult patients. ETV or VC+ETV failure was recorded in half of the patients aged < 1 year; this report was consistent with those of the previous literature. Moreover, these patients had a HC of > 90 percentile at the time of the procedure, which makes it the focal point of our study. Furthermore, ETV failure was not observed in patients with a HC of < 90 percentile. Our results indicate that remarkable decrease in ICP may not be achieved by ETV in patients with enlarged ventricular volume and HC. Thus, the results of the present study contribute to the literature by addressing this important issue.

## REFERENCES

- Hellwig D, Grotenhuis JA, Tirakotai W, et al. Endoscopic third ventriculostomy for obstructive hydrocephalus. *Neurosurg Rev* 2005; 28: 1-34.
- Etus V, Ceylan S. Success of endoscopic third ventriculostomy in children less than 2 years of age. *Neurosurg Rev* 2005; 28: 284-8.
- Mixter MJ. Ventriculoscopy and puncture of the floor of the third ventricle. *Boston Med Surg J* 1923; 1: 277-8.
- Scarff JE. Endoscopic treatment of hydrocephalus: Description of ventriculoscope and preliminary report of cases. *Arch Neurol Psychiatr* 1936; 38: 853-61.
- Cinalli G, Spennato P, Columbano L, et al. Neuroendoscopic treatment of arachnoid cysts of the quadrigeminal cistern: a series of 14 cases. *J Neurosurg Pediatr* 2010; 6: 489-97.
- Gangemi M, Donati P, Maiuri F, Longatti P, Godano U, Mascari C. Endoscopic third ventriculostomy for hydrocephalus. *Minim Invasive Neurosurg* 1999; 42: 128-32.
- Walker ML, MacDanold J, Wright LC. The History of Ventriculoscopy: Where do we go from here? *Pediatr Neurosurg* 1992; 18: 218-23.
- Vogel TW, Bahuleyan B, Robinson S, Cohen A. The role of endoscopic third ventriculostomy in the treatment of hydrocephalus. *J Neurosurg Pediatr* 2013; 12: 54-61.
- Tasiou A, Brotis AG, Esposito F, Paterakis KN. Endoscopic third ventriculostomy in the treatment of idiopathic normal pressure hydrocephalus: a review study. *Neurosurg Rev* 2016; 39: 557-63.
- Knaus H, Matthias S, Koch A, Thomale UW. Single burr hole endoscopic biopsy with third ventriculostomy-measurements and computer assisted planning. *Childs Nerv Syst* 2011; 27: 1233-41.
- Copley P, Kirkman MA, Thompson D, James G, Aquilina K. Endoscopic surgery for intraventricular arachnoid cysts in children: clinical presentation, radiological features, management, and outcomes over a 12-year period. *Childs Nerv Syst* 2018; 34: 257-66.
- Knies B, Morota N, Ihara S, Tamura S, Ogiwara H. Pediatric intraventricular arachnoid cysts in the body of lateral ventricle: surgical outcome and its embryologic background. *Childs Nerv Syst* 2016; 32: 2197-204.
- Ozek MM, Urgan K. Neuroendoscopic Management of Suprasellar Arachnoid Cysts. *World Neurosurgery* 2013; 79: 13-18.
- Gui S, Bai J, Wang X, et al. Assessment of endoscopic treatment for quadrigeminal cistern arachnoid cysts: A 7-year experience with 28 cases. *Childs Nerv Syst* 2016; 32: 647-54.
- Rei J, Pereira J, Reis C, Salvador S, Vaz R. Endoscopic Third Ventriculostomy for the Treatment of Hydrocephalus in a Pediatric Population with Myelomeningocele. *World Neurosurg* 2017; 105: 163-9.
- Di Rocco C, Massimi L, Tamburrini G. Shunts vs endoscopic third ventriculostomy in infants: are there different types and/or rates of complications? A review. *Childs Nerv Syst* 2006; 22: 1573-89.
- Deopujari CE, Karmarkar VS, Shaikh ST. Endoscopic Third Ventriculostomy: Success and Failure. *J Korean Neurosurg Soc* 2017; 60: 306-14.
- Jung TY, Chong S, Kim IY, et al. Prevention of Complications in Endoscopic Third Ventriculostomy. *J Korean Neurosurg Soc* 2017; 60: 282-88.
- Erşahin Y, Kesikçi H. Endoscopic management of quadrigeminal arachnoid cysts. *Childs Nerv Syst* 2009; 25: 569-76.
- Alvarez JA, Cohen AR. Neonatal applications of neuroendoscopy. *Neurosurg Clin N Am* 1998; 9: 405-13.
- Buxton N, Macarthur D, Mallucci C, Punt J, Vloeberghs M. Neuroendoscopic third ventriculostomy in patients less than 1 year old. *Pediatr Neurosurg* 1998; 29: 73-6.
- Sufianov AA, Sufianova GZ, Iakimov IA. Endoscopic third ventriculostomy in patients younger than 2 years: outcome analysis of 41 hydrocephalus cases. *J Neurosurg Pediatr* 2010; 5: 392-401.
- Fukuhara T, Vorster SJ, Luciano MG. Risk factors for failure of endoscopic third ventriculostomy for obstructive hydrocephalus. *Neurosurgery* 2000; 46: 1100-11.
- Javadpour M, Mallucci C, Brodbelt A, Golash A, May P. The impact of endoscopic third ventriculostomy on the management of newly diagnosed hydrocephalus in infants. *Pediatr Neurosurg* 2001; 35: 131-35.
- Gilmore JH, Smith LC, Wolfe HM, et al. Prenatal Mild Ventriculomegaly Predicts Abnormal Development of the Neonatal Brain. *Biol Psychiatry* 2008; 64: 1069-76.
- Chiu TH, Haliza G, Lin YH, et al. A retrospective study on the course and outcome of fetal ventriculomegaly. *Taiwan J Obstet Gynecol* 2014; 53: 170-7.
- Tamburrini G, D'Angelo L, Paternoster G, et al. Endoscopic management of intra and paraventricular CSF cysts. *Childs Nerv Syst* 2007; 23: 645-51.
- El-Ghandour NMF. Endoscopic treatment of suprasellar arachnoid cysts in children. *J Neurosurg Pediatr* 2011; 8: 6-14.